



Left Internal Jugular Vein Cannulation in a Patient with Thrombosed Right Internal Jugular Vein: A Double Jeopardy?

Tromboze Sağ İnternal Juguler Venli Bir Hastada Sol İnternal Juguler Ven Kanülasyonu: Çifte Risk mi?

Chetna Shamsbery¹ , Vansh Priya² 

¹SGPGIMS, Raibareilly Road, Lucknow, Uttar Pradesh, India

²T. S Misra Medical College, Amausi, Lucknow, Uttar Pradesh, India

Cite this article as: Shamsbery C, Priya V. Left Internal Jugular Vein Cannulation in a Patient with Thrombosed Right Internal Jugular Vein: A Double Jeopardy? Turk J Anaesthesiol Reanim 2018; 46(4): 337-8.

ORCID ID of the author: C.S. 0000-0001-5658-2319; V.P. 0000-0000-25642-5871.

Facial swelling on postoperative day 3 in a renal transplant recipient whose left internal jugular vein was cannulated at the time of transplant. Pre-procedure ultrasonography revealed thrombus in the right internal jugular vein (Figure 1).

Color duplex ultrasonography showing thrombus in the left internal jugular vein on postoperative day 3 (Figure 2).

Resolution of swelling following the removal of triple lumen catheter and the administration of low-molecular-weight heparin therapy (Figure 3).

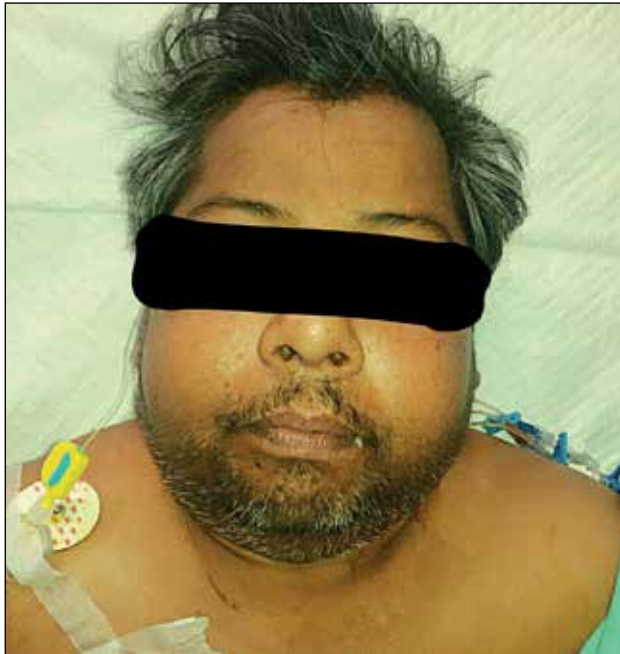

Figure 1. Facial swelling on postoperative day 3 in a renal transplant recipient whose left internal jugular vein was cannulated at the time of transplant. Pre-procedure ultrasonography revealed thrombus in the right internal jugular vein

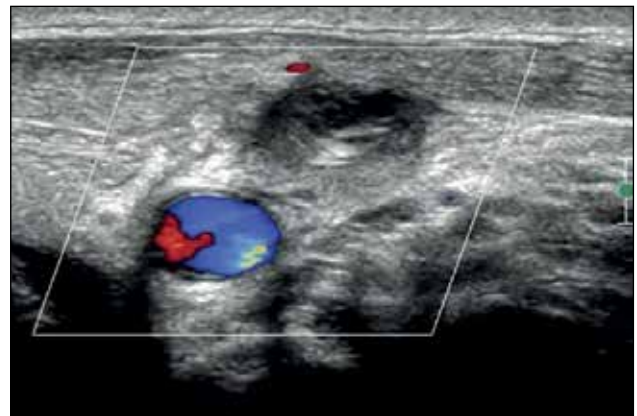


Figure 2. Color duplex ultrasonography showing thrombus in the left internal jugular vein on post-operative day 3

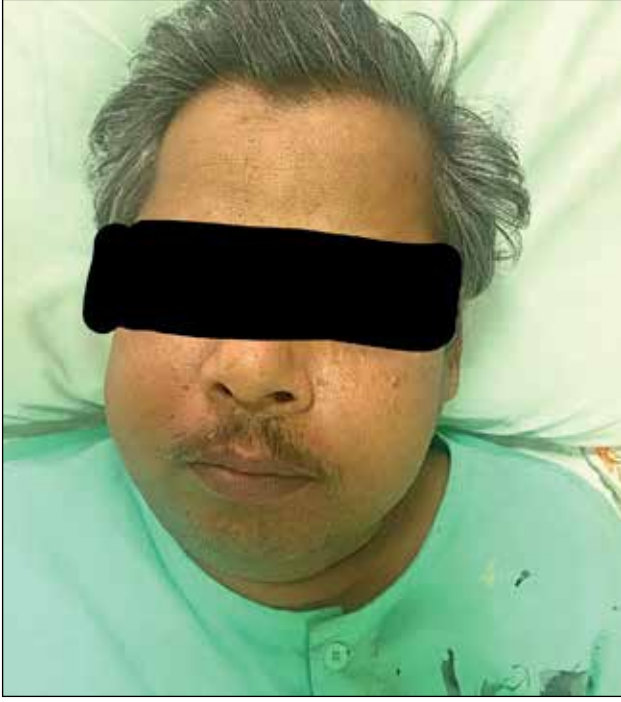

Figure 3. Resolution of swelling following the removal of triple lumen catheter and the administration of low-molecular-weight heparin therapy

Peer-review: Externally peer-reviewed.

Author Contributions: Concept – C.S., V.P.; Design – C.S., V.P.; Supervision – C.S., V.P.; Materials – C.S., V.P.; Writing Manuscript – C.S., V.P.; Critical Review – C.S., V.P.

Conflict of Interest: Authors have no conflicts of interest to declare.

Financial Disclosure: The authors declared that this study has received no financial support.

Hakem Değerlendirmesi: Dış bağımsız.

Yazar Katkıları: Fikir – C.S., V.P.; Tasarım – C.S., V.P.; Denetleme – C.S., V.P.; Malzemeler – C.S., V.P.; Yazıyı Yazan – C.S., V.P.; Eleştirel İnceleme – C.S., V.P.

Çıkar Çatışması: Yazarlar çıkar çatışması bildirmemişlerdir.

Finansal Destek: Yazarlar bu çalışma için finansal destek almadıklarını beyan etmişlerdir.