



## What Can We Learn From Two Consecutive Cases? Droperidol May Abolish TcMEPs

Art Arda Gelen İki Vaka Hakkında Ne Öğrenebiliriz? Droperidol TcMEP'i Engelleyebilir mi?

Ángel Saponaro González<sup>1</sup>, Pedro Javier Pérez Lorensu<sup>1</sup>, Santiago Chaves Gómez<sup>2</sup>, Josué Francisco Nodarse Medina<sup>2</sup>, Jose Ángel Torres Dios<sup>2</sup>

<sup>1</sup>Intraoperative Neurophysiologic Monitoring Unit, University Hospital Of Canarias, Santa Cruz De Tenerife, Spain

<sup>2</sup>Anesthesiology Department, University Hospital Of Canarias, Santa Cruz De Tenerife, Spain

Droperidol is a D2 receptor antagonist currently used in Europe for preventing postoperative nausea and vomiting. It was used to perform neurolept anaesthesia in combination with fentanyl until a Food and Drug Administration (FDA) 'black box' warning restricted its use due to cardiovascular side effects in 2001. There is no literature regarding the effects of droperidol on transcranial motor evoked potentials (TcMEPs) elicited by electrical stimulation. Our aim was to report two cases of spine surgery in which TcMEPs were lost due to droperidol administration. We report the cases of a 4-year-old male with scoliosis undergoing correction and a 58-year-old woman with metastasis on the D8 vertebrae undergoing kyphosis correction. Intraoperative neurophysiological monitoring was achieved through TcMEPs and somatosensory evoked potentials (SEPs). Intraoperative neurophysiological monitoring (IONM) showed a temporal loss of TcMEPs without SEPs changes coinciding with the administration of droperidol. TcMEP stimulation parameters were changed to double train of pulses, with the aim to elicit them, obtaining responses. Five minutes after droperidol administration, TcMEPs were equal to those at baseline. Droperidol used as prophylaxis for postoperative nausea abolishes TcMEPs. Changing stimulation parameters to double train of pulses, it allows to bypass droperidol central action, achieving monitorable TcMEPs.

**Keywords:** Droperidol, intraoperative neurophysiological monitoring, transcranial motor evoked potentials, double train

Droperidol postoperatif bulantı ve kusmayı önlemek amacıyla Avrupa'da şu an kullanılan bir D2 reseptör antagonisttir. 2001 yılında kardiyovasküler yan etkilerinden dolayı FDA kara kutu uyarısı ile kullanımını engellenene kadar fentanil ile kombine edilerek nörolept anestezi için kullanıldı. Droperidolün elektriksel stimülasyonun neden olduğu TcMEP üzerindeki etkileriyle ilgili literatür verisi bulunmamaktadır. Bu çalışmada TcMEP'in droperidol uygulamasından dolayı yok olduğu iki omurga cerrahisi vakası sunulmaktadır. İlk olarak, düzeltme ameliyatı olan 4 yaşındaki skoliyoz hastası bir erkek çocuğu vakasını ve sonra da D8 vertebralara metastazı olan ve kifoz düzeltme ameliyatı geçiren 58 yaşındaki bir bayan hastayı sunduk. Transkraniyel motor uyarılmış potansiyeller (TcMEP) ve somatosensoryel uyarılmış potansiyeller (SEP) ile, intraoperatif nörofizyolojik monitorizasyon gerçekleştirildi. Intraoperatif nörofizyolojik monitorizasyon (IONM), SEP değişiklikleri olmaksızın, droperidol uygulamasıyla aynı zamanda meydana gelen geçici bir TcMEP kaybı ortaya koydu. TcMEP stimülasyonu parametreleri, çift nabız atımlarıyla değiştirildi, yanıtlar alındı. Droperidol uygulamasından 5 dakika sonra TcMEP değeri başlangıç değeriyle eşitti. Postoperatif bulantı için profilaksi olarak kullanılan droperidol TcMEP'i engeller. Stimülasyon parametrelerinin çift diziyile değiştirilmesi ile problem çözülebilir.

**Anahtar Kelimeler:** Droperidol, intraoperatif nörofizyolojik monitorizasyon, TcMEP, çift dizi

### Introduction

Intraoperative neurophysiological monitoring in spine surgeries is a basic tool to assess the functional integrity of the spinal cord (1). To grant optimal intraoperative neurophysiological monitoring (IONM), an anaesthetic regime free of muscle relaxants as well as agents that do not suppress evoked potentials is essential. The gold standard is total intravenous anaesthesia (TIVA) with propofol and remifentanyl.

Before TIVA was standardised, many other drugs were used to allow IONM. Neurolept anaesthesia was one of the regimens used, which combined droperidol, a butyrophenone acting by blocking D2 receptors, and fentanyl, an opioid. It was popular during conscious sedation for seizure focus identification and ablation and had minor effects on EEG and cortical somatosensory evoked potential monitoring (2).

In 2001, a Food and Drug Administration (FDA) 'black box' warning restricted droperidol use because of QT-interval prolongation and torsade de pointes in patients following antipsychotic treatment. However, these side effects might be dose

dependant. No cardiovascular events have been reported in the literature due to droperidol at doses used for neurolept anaesthesia or as prophylaxis for postoperative nausea and vomiting (3).

Although droperidol is not currently used in the USA, it is still used by anaesthesiologists in 19 of 24 European countries as an antiemetic drug (0.625 to 1.25 mg IV) (4). It is more effective when administered at the end of surgery.

### Case Presentation

The first patient's legal guardian and the second patient were informed on IONM modalities and the anaesthetic protocol; they signed the informed consent form, and their permission was taken for this case report. A 4-year-old male weighing 16kgs was operated for correction of scoliosis which he presented with. The patient underwent a TIVA regime with propofol (4-6 mg kg<sup>-1</sup> h<sup>-1</sup>) and remifentanyl (0.15-0.25 mcg kg<sup>-1</sup> min<sup>-1</sup>), and his scoliosis was corrected by placing unilateral pedicle screws from T10 to L1 on the right side. IONM was performed with a Cadwell Cascade IONM 32 channel device (Kennewick, WA, USA). Motor evoked potentials were elicited by transcranial stimulation (corkscrew electrodes on C1-C2, train of five stimuli, duration: 0.05 ms, interstimulus interval: 4 ms, intensity: 380 V) and were bilaterally recorded by needle electrodes (12 mm) on the abductor pollicis brevis, tibialis anterior and abductor hallucis muscles. Somatosensory evoked potentials were elicited by bilateral stimulation of the posterior tibial and median nerves (paired surface disk electrodes on each nerve, single stimulus, duration: 0.2 ms, interstimulus interval: 5.1 Hz, intensity: 20-40 mA) and were recorded by corkscrew electrodes on Cz-Fz for the lower limbs and C3'-C4' for the upper limbs. During the procedure, the depth of anaesthesia was assessed with BIS monitoring that maintained values between 40 and 60 and the body temperature was stable at 35.5°C. A blood gas sample was obtained each hour, and capnography was continuously performed.

Intraoperative neurophysiological monitoring continued without any disturbances, until the surgeons started to close the surgical wound, when a sudden bilateral loss of TcMEPs was noted (Figure 1) while the somatosensory evoked potentials were stable. Any potential cause that could explain this finding, such as surgical damage, hypotension, anaemia, hypercapnia or hypoxemia, was dismissed as TcMEPs were lost in the lower and upper extremities and no changes in the blood pressure, blood gas sample, or capnography were seen. The anaesthesiologist adverted that 1-mg IV droperidol (50 mcg kg<sup>-1</sup>) was administered to the patient to avoid postoperative nausea 2 min before the TcMEPs were lost. After changing the parameters to elicit TcMEP by a double train of pulses (5) (first train: two stimuli, second train: five stimuli, duration: 0.05ms, interstimulus interval: 4ms, intertrain interval: 30ms, intensity: up to 400 V), low-amplitude TcMEPs were bilaterally obtained. Five minutes later, TcMEPs recovered. Surgery continued until

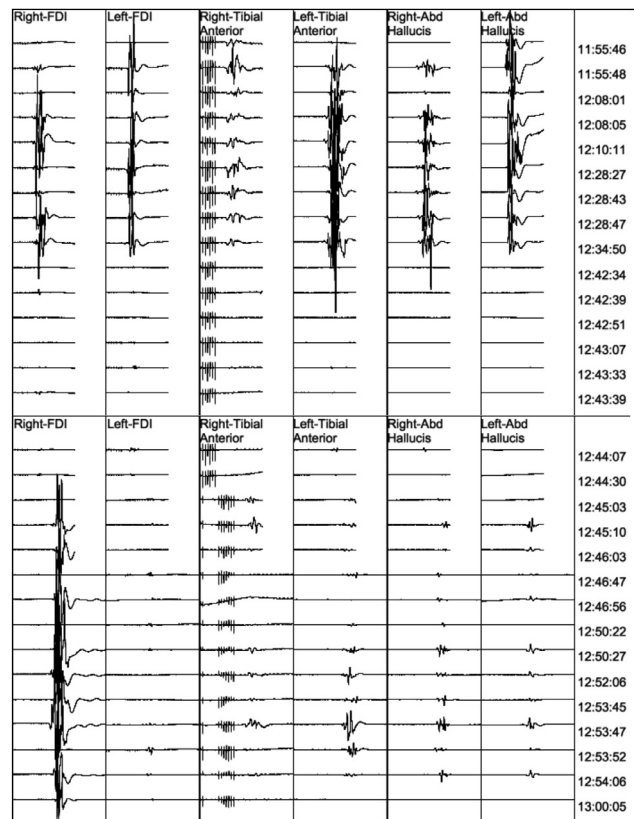


Figure 1. Transcranial motor evoked potentials (from left to right: right and left first dorsal interosseous, right and left tibialis anterior and right and left abductor hallucis muscles). Note the sudden loss of motor responses at time 12:42:34 and the recovery after applying a double train of stimuli at time 12:45:03.

the end without any further disturbance. The patient woke up without any additional neurological deficit.

The same anaesthetic protocol (propofol: 4-8 mg kg<sup>-1</sup> h<sup>-1</sup> and remifentanyl: 0.10-0.30 mcg kg<sup>-1</sup> min<sup>-1</sup>) was administered in the next consecutive patient (a 58-year-old woman undergoing thoracic kyphosis correction). During closure, TcMEPs were temporally suppressed after the administration of 1.25 mg droperidol. Applying a double train of pulses allowed to obtain monitorable TcMEPs.

### Discussion

These cases illustrate the importance of a fluid relationship between the different members in an operating room. The neurophysiological findings could be consequence of surgical damage, a systemic event or a pharmacologic interaction. Surgical damage was discarded by the surgeons as well as for TcMEPs loss on the upper extremities and hypotension, hypercapnia, hypoxemia or anaemia by the anaesthesiologist. The only remaining potential cause was the administration of droperidol.

To our knowledge, there is no report in the literature regarding the effect of droperidol on TcMEPs by electrical stimulation, even more since this drug it is not currently used since it was banished by the FDA. According to Kalkman, in

humans, droperidol produces a sustained amplitude depression of the tibialis anterior and abductor hallucis TcMEPs by magnetic stimulation with no onset latency changes (6). The same findings were noted in primates (7).

As a D2 receptor antagonist, it is unknown how droperidol increases the TcMEP intensity threshold. We can assert that it has no peripheral effect as a muscle relaxant because changing the stimulation parameters to a double train of pulses allows obtaining motor responses.

## Conclusion

Droperidol used as prophylaxis for preventing postoperative nausea and vomiting at standard doses (0.6-1.25 mg IV) administered prior to the end of the surgery temporally abolishes TcMEPs. Eliciting TcMEPs by applying a double train of stimuli can partially solve the suppression caused by droperidol. This effect must be taken into account, and droperidol should not be administered until after skin closure.

**Informed Consent:** Written informed consent was obtained from the parents of the patients who participated in this study.

**Peer-review:** Externally peer-reviewed.

**Author Contributions:** Concept - A.S.G., P.J.P.L., S.C.G., J.F.N.M., J.A.T.D.; Design - A.S.G., P.J.P.L., S.C.G., J.F.N.M., J.A.T.D.; Supervision - A.S.G., P.J.P.L., S.C.G., J.F.N.M., J.A.T.D.; Resources - A.S.G., P.J.P.L., S.C.G., J.F.N.M., J.A.T.D.; Materials - A.S.G., P.J.P.L., S.C.G., J.F.N.M., J.A.T.D.; Data Collection and/or Processing - A.S.G., P.J.P.L., S.C.G., J.F.N.M., J.A.T.D.; Analysis and/or Interpretation - A.S.G., P.J.P.L., S.C.G., J.F.N.M., J.A.T.D.; Literature Search - A.S.G., P.J.P.L., S.C.G., J.F.N.M., J.A.T.D.; Writing Manuscript - A.S.G., P.J.P.L., S.C.G., J.F.N.M., J.A.T.D.; Critical Review - A.S.G., P.J.P.L., S.C.G., J.F.N.M., J.A.T.D.; Other - A.S.G., P.J.P.L., S.C.G., J.F.N.M., J.A.T.D.

**Conflict of Interest:** No conflict of interest was declared by the authors.

**Financial Disclosure:** The authors declared that this study has received no financial support.

**Hasta Onamı:** Yazılı hasta onamı bu çalışmaya katılan hastaların ailelerinden alınmıştır.

**Hakem Değerlendirmesi:** Dış bağımsız.

**Yazar Katkıları:** Fikir - A.S.G., P.J.P.L., S.C.G., J.F.N.M., J.A.T.D.; Tasarım - A.S.G., P.J.P.L., S.C.G., J.F.N.M., J.A.T.D.; Denetleme - A.S.G., P.J.P.L., S.C.G., J.F.N.M., J.A.T.D.; Kaynaklar - A.S.G., P.J.P.L., S.C.G., J.F.N.M., J.A.T.D.; Malzemeler - A.S.G., P.J.P.L., S.C.G., J.F.N.M., J.A.T.D.; Veri Toplanması ve/veya İşlemesi - A.S.G., P.J.P.L., S.C.G., J.F.N.M., J.A.T.D.; Analiz ve/veya Yorum - A.S.G., P.J.P.L., S.C.G., J.F.N.M., J.A.T.D.; Literatür Taraması - A.S.G., P.J.P.L., S.C.G., J.F.N.M., J.A.T.D.; Yazıyı Yazan - A.S.G., P.J.P.L., S.C.G., J.F.N.M., J.A.T.D.; Eleştirel İnceleme - A.S.G., P.J.P.L., S.C.G., J.F.N.M., J.A.T.D.; Diğer - A.S.G., P.J.P.L., S.C.G., J.F.N.M., J.A.T.D.

**Çıkar Çatışması:** Yazarlar çıkar çatışması bildirmemişlerdir.

**Finansal Destek:** Yazarlar bu çalışma için finansal destek almadıklarını beyan etmişlerdir.

## References

1. Nuwer MR, Emerson RG, Gallway G, Legatt AD, Lopez J, Minahan R, et al. Evidence-based guideline update: Intraoperative spinal monitoring with somatosensory and transcranial electrical motor evoked potentials. *J Clin Neurophysiol* 2012; 29: 101-8. [\[CrossRef\]](#)
2. Sloan TB. Anesthetic effects on electrophysiologic recordings. *J Clin Neurophysiol* 1998; 15: 217-26. [\[CrossRef\]](#)
3. Henzi I, Sonderegger J, Tramèr MR. Efficacy, dose-response, and adverse effects of droperidol for prevention of postoperative nausea and vomiting. *Can J Anaesth* 2000; 47: 537-51. [\[CrossRef\]](#)
4. Schaub I, Lysakowski C, Elia N, Tramèr MR. Low-dose droperidol ( $\leq 1$  mg or  $\leq 15$   $\mu$ g kg<sup>-1</sup>) for the prevention of postoperative nausea and vomiting in adults: quantitative systematic review of randomised controlled trials. *Eur J Anaesthesiol* 2012; 29: 286-94. [\[CrossRef\]](#)
5. Journée HL, Polak HE, de Kleuver M, Langeloo DD, Postma AA. Improved neuromonitoring during spinal surgery using double-train transcranial electrical stimulation. *Med Biol Eng Comput* 2004; 42: 110-3. [\[CrossRef\]](#)
6. Kalkman CJ, Drummond JC, Patel PM, Sano T, Chesnut RM. Effects of droperidol, pentobarbital, and ketamine on myogenic transcranial magnetic motor-evoked responses in humans. *Neurosurgery* 1994; 35: 1066-71. [\[CrossRef\]](#)
7. Ghaly RF, Stone JL, Levy WJ, Kartha R, Brunner EA, Aldrete JA, et al. The effect of neuroleptanalgesia (droperidol-fentanyl) on motor potentials evoked by transcranial magnetic stimulation in the monkey. *J Neurosurg Anesthesiol* 1991; 3: 117-23. [\[CrossRef\]](#)