



Breakage of an Epidural Catheter Inserted for Labor Analgesia

Doğum Analjezi İçin Takılan Epidural Kateterin Kopması

Pınar Üşar¹, Aysun Afife Kar¹, Güven Çıtak², Jale Maral¹, Şeyda Canlı¹

¹Clinic of Anaesthesiology and Reanimation, Şifa University Hospital, İzmir, Turkey

²Clinic of Neurosurgery, Şifa University Hospital, İzmir, Turkey

The breakage of an epidural catheter, which is usually not noticed, is a rare but important complication encountered while inserting or removing the catheter during epidural blockade. While the epidural catheter was being inserted for labor analgesia, despite no problem being encountered in advancing the catheter, it was drawn back to verify the location; it was observed that 2 cm of the distal end of the catheter was missing. A neurosurgical consultation was requested; it was reported that the broken piece would not create any problems and reintervention could be performed for labor analgesia. An epidural catheter was reinserted and was used for analgesia without any problem until delivery. Although nine months have passed, no problem was defined by the patient. If epidural catheter has to be removed while the Tuohy needle is still in place, we recommend that they should be removed together to minimize the risk of a possible breakage. We think that the decision for surgery and imaging can be performed based on the individual patient's clinical picture.

Keywords: Epidural analgesia, catheter, complication, breakage

Epidural kateter kopması, epidural blok uygulanırken yerleştirme veya çekme sırasında görülebilen, çoğu zaman fark edilemeyen, nadir fakat önemli bir komplikasyondur. Gebe hastamıza analjezi uygulanmak üzere epidural kateter yerleştirilirken, ilerletmede bir sorunla karşılaşılmasına rağmen yerini tekrar doğrulamak amacıyla kateter geri çekildi ve bu sırada yaklaşık 2 cm kadar distal ucun kopmuş olduğu görüldü. Beyin cerrahi konsültasyonu istendi. Kopan parçanın herhangi bir sorun yaratmayacağı ve doğum analjezi uygulamak için tekrar girişim yapılabileceği belirtildi. Epidural kateter yeniden takıldı ve doğuma kadar analjezi için sorunsuz bir şekilde kullanıldı. Şu an üzerinden yaklaşık dokuz ay geçmesine rağmen hasta herhangi bir sorun tanımlamadı. Epidural kateter henüz Tuohy iğnesi içindeyken geri çekilecekse olası kopmaları en aza indirilebilmek için mutlaka birlikte çekilmesini öneriyoruz. Görüntüleme ve cerrahi konusunda ise hastanın kliniğine göre karar verilebileceği ve takip edilebileceği görüşündeyiz.

Anahtar Kelimeler: Epidural analjezi, kateter, komplikasyon, kopma

Introduction

The breakage of an epidural catheter, which is usually not noticed, is a rare but important complication encountered while inserting or removing the catheter during epidural anaesthesia (1). Epidural catheters are usually made of nylon, polyethylene, polyurethane and polyamide; recently, they are being manufactured with a stainless steel guide wire. Among the epidural catheter entrapments, the incidence of the compression of a catheter in the body has been reported to be 1/20,000-1/30,000 and that of catheter knotting has been reported to be 1/20,000-1/25,000 (2).

We encountered a case of epidural catheter breakage inserted for labor analgesia. A consent for publication of this case has been obtained from the patient.

Case Presentation

Epidural catheter insertion was required to provide analgesia for labor pain of a 31-year-old primigravid woman with a height and weight of 1.68 m and 95 kg, respectively. According to the American Society of Anesthesiology (ASA) classification, she was ASA I. Her cervical dilatation was 4 cm and effacement was 50%.

After the patient was informed about the procedure and her consent was obtained, the lumbar region was cleaned with povidone-iodine solution and 30 mg of 2% lidocaine was infiltrated into the skin at the L₃-L₄ level, while the patient was in

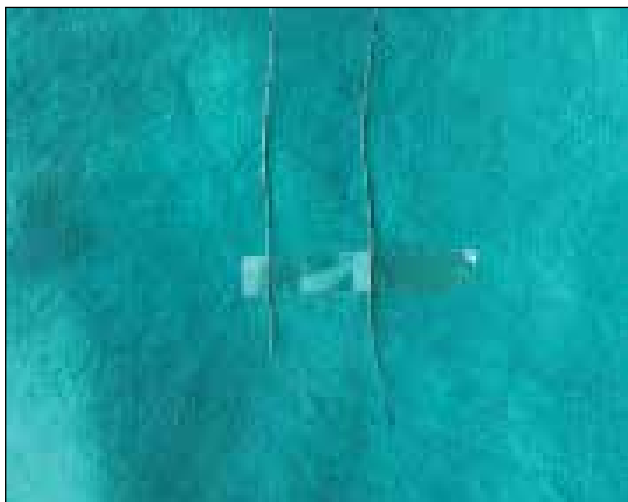


Figure 1. An intact catheter and a broken catheter

the sitting position. Perifix® Soft Type 701 Filter Set (Braun, Melsungen, Germany), and the loss of resistance technique with normal saline was used. The epidural space was identified by a 18-gauge Tuohy needle with the bevel laterally pointing at 5 cm at the first attempt. Further, the tip of the needle was rotated to the cranial direction, a 20-gauge polyamide catheter was inserted. Despite no problem being encountered while advancing the catheter, in case of a pseudo loss of resistance feeling, the catheter was drawn back to verify the location and it was observed that 2 cm of the distal end of the catheter was missing (Figure 1). Therefore, the needle was also removed; however, the broken piece was not present.

A neurosurgical consultation was requested. It was reported that the broken piece was too small to be visualized by any imaging method; even if it could be, surgical removal would be unnecessary if the patient was asymptomatic; probably, it would not be possible to find it during surgical intervention. Reintervention could be performed for labor analgesia.

Thus, an epidural catheter was reinserted through the L₄-L₅ level at the first attempt and was used for analgesia without problem until delivery. Thereafter, the required explanations were provided to the patient, and she was scheduled to follow-up. Although nine months have passed, no problem was defined.

Discussion

The use of an epidural catheter for labor analgesia has substantially increased in the recent years and performed by many anaesthesiologists. Several epidural catheter-related complications have been defined. Kinking, curling, occlusion, knotting, manufacturing defects, injury during insertion, cutting, breakage during removal, unilateral block because of catheter position and intravascular or intrathecal placement are some of these complications (3). An ideal catheter should be radiopaque, flexible and disposable and have stretching capacity. Catheters can be made of various materials, including nylon,

polyethylene, polyurethane and polyamide (4). Ateş et al. (3) demonstrated that polyurethane catheters are less fragile compared with nylon catheters even when traumatized. While nylon catheters can be stretched by 30% of their original length, this rate is 300% for polyurethane catheters.

The breakage of an epidural catheter may be because of various reasons, including the length of the catheter in epidural space being longer than required, cut because of compression between the epidural needle and bony surface, degenerative effects of structural alterations caused by degenerative osteoarthritis, impairment in catheter flexibility, withdrawal of catheter by patient, injury of catheter by the Tuohy needle, breakage of the strengthening wire in the catheter and varying catheter resistance to tension (2). Considering these factors, it may be thought that Tuohy needle has cut the catheter in the present case.

It has been recommended that if a catheter is to be withdrawn during insertion, it should be withdrawn along with the needle (1, 2). Such an approach may avoid catheter injury because of the needle. Despite this technique, Collier, who presented two cases with epidural catheter inserted for labor analgesia, has encountered approximately 4 cm breakages of epidural catheters (1). We have withdrawn the catheter alone because no problem was encountered and our catheter was broken.

Catheters should be examined in terms of manufacturing defects prior to insertion. The maximum length of the catheter within the epidural space should be 5 cm. Epidural catheters should never be sutured to the skin; this may also cause breakage. An experienced and well-trained person should perform catheter removal without using excessive force or tools, such as forceps (5). Pierre et al. (6) observed no problem in the catheters withdrawn approximately 3 h after insertion; however in practice, catheters are not withdrawn at such early times.

There are some suggested methods in the event of difficulty while withdrawing the epidural catheter. In case of resistance, injecting normal saline through the catheter may facilitate the procedure. It is recommended that patients should be placed in the same position during the insertion and withdrawal of the catheter. In case of failure, it can be attempted again in the lateral position. If the catheter cannot be withdrawn at the first attempt, a second attempt can be made after 30-60 min. In such a case, by the postural changes of the patient, the catheter may be incidentally loosened from where it is compressed (7, 8). Although there has been a case report, wherein the catheter was successfully withdrawn by passing the Tuohy needle over the catheter, it is not recommended (9).

There are various options to visualize the broken fragment of an epidural catheter. Fragments that could not be visualized by radiography can be visualized by lumbar ultrasonography (5). Although cases of injury occurring secondary to magnet-

ic resonance imaging have not been reported, it is not recommended as the first option due to some theoretical risks, such as thermal injury, dislodgment, or movement. Computerized tomography can be considered as a visualization technique alternative to fluoroscopy as it is a high-resolution modality, providing rapid results (10). Some patients may require the simultaneous use of different imaging modalities. However, despite the use of all these techniques, some catheters remain undetected (1, 4, 11). We were unable to use an imaging modality as our patient was pregnant. After the recommendations of neurosurgeons, literature review and informing the patient, we decided to monitor the patient without using any imaging method as the broken fragment was very small.

In cases with epidural catheter breakage, the currently accepted consensus on treatment is that surgical removal is not necessary if the broken fragment is sterile and inert, and if the patient has no neurological complaints (5, 12). A study on cats demonstrated that broken fragments were surrounded by fibrous tissue within 3 weeks and remained harmlessly in the epidural area (13). The present patient, who has been under follow-up for nine months, remained asymptomatic with no neurological complaints. In symptomatic patients, immediate neurosurgical consultation for early surgical intervention should be considered. Another group, wherein surgical removal is recommended, is paediatric patients. The broken fragment should be surgically removed in children, considering that it has the potential to cause neurological damage secondary to infection, fibrosis, migration, or direct mechanical neural irritation (14).

Conclusion

If an epidural catheter has to be removed while the Tuohy needle is still in place, we recommend that they should be removed together to minimize the risk of a possible breakage. Although many studies have recommended imaging, we think that decision making and monitoring can be performed based on the individual patient's clinical picture because most broken fragments cannot be visualized and surgery can only be performed in a limited number of cases. Furthermore, there have been many cases, wherein broken fragment cannot be detected even in surgery. As for the ethical aspect, we believe that patients and their relatives should be provided the necessary information.

Informed Consent: Written informed consent was obtained from patient who participated in this case.

Peer-review: Externally peer-reviewed.

Author Contributions: Concept - P.Ü.; Design - P.Ü., A.A.K.; Supervision - J.M., Ş.C.; Funding - P.Ü., G.Ç.; Materials - P.Ü.; Data Collection and/or Processing - P.Ü.; Analysis and/or Interpretation - P.Ü., A.A.K., G.Ç., J.M., Ş.C.; Literature Review - P.Ü., J.M.; Writer - P.Ü.; Critical Review - P.Ü., A.A.K., G.Ç., J.M., Ş.C.; Other - P.Ü.

Conflict of Interest: No conflict of interest was declared by the authors.

Financial Disclosure: The authors declared that this study has received no financial support.

Hasta Onamı: Yazılı hasta onamı bu olguya katılan hastadan alınmıştır.

Hakem Değerlendirmesi: Dış bağımsız.

Yazar Katkıları: Fikir - P.Ü.; Tasarım - P.Ü., A.A.K.; Denetleme - J.M., Ş.C.; Kaynaklar - P.Ü., G.Ç.; Malzemeler - P.Ü.; Veri toplaması ve/veya işlemesi - P.Ü.; Analiz ve/veya yorum - P.Ü., A.A.K., G.Ç., J.M., Ş.C.; Literatür taraması - P.Ü., J.M.; Yazıyı yazan - P.Ü.; Eleştirel İnceleme - P.Ü., A.A.K., G.Ç., J.M., Ş.C.; Diğer - P.Ü.

Çıkar Çatışması: Yazarlar çıkar çatışması bildirmemişlerdir.

Finansal Destek: Yazarlar bu çalışma için finansal destek almadıklarını beyan etmişlerdir.

References

1. Collier C. Epidural catheter breakage: a possible mechanism. *Int J Obstet Anesth* 2000; 9: 87-93. [\[CrossRef\]](#)
2. Gülcü N. The diagnosis and treatment in epidural catheter breakages. *Uludağ University Medical Journal* 2007; 33: 29-32.
3. Ateş Y, Yücesoy CA, Unlü MA, Saygin B, Akkaş N. The mechanical properties of intact and traumatized epidural catheters. *Anesth Analg* 2000; 90: 393-9. [\[CrossRef\]](#)
4. Sbardelotto C, Yoshimi MM, Pereira Rda R, de Castro RA. Breakage of a catheter in the epidural space. *Rev Bras Anesthesiol* 2008; 58: 643-50.
5. Hobaike AB. Breakage of epidural catheters: etiology, prevention, and management. *Rev Bras Anesthesiol* 2008; 58: 227-33. [\[CrossRef\]](#)
6. Pierre HL, Block BM, Wu CL. Difficult removal of a wire-reinforced epidural catheter. *J Clin Anesth* 2003; 15: 140-1. [\[CrossRef\]](#)
7. Lee YH, Hwang HY, Sim WS, Yang M, Lee CJ. Breakage of a thoracic epidural catheter during its removal -A case report-. *Korean J Anesthesiol* 2010; 58: 569-72. [\[CrossRef\]](#)
8. Asai T, Yamamoto K, Hirose T, Taguchi H, Shingu K. Breakage of epidural catheters: a comparison of an arrow reinforced catheter and other nonreinforced catheters. *Anesth Analg* 2001; 92: 246-8. [\[CrossRef\]](#)
9. Shantha TR, Mani M. A simple method to retrieve irretrievable epidural catheters. *Anesth Analg* 1991; 73: 508-9. [\[CrossRef\]](#)
10. Mitra R, Fleischmann K. Management of the sheared epidural catheter: is surgical extraction really necessary? *J Clin Anesth* 2007; 19: 310-4. [\[CrossRef\]](#)
11. Schummer W, Schummer C. Another cause of epidural catheter breakage? *Anesth Analg* 2002; 94: 233. [\[CrossRef\]](#)
12. Nishio I, Sekiguchi M, Aoyama Y, Asano S, Ono A. Decreased tensile strength of an epidural catheter during its removal by grasping with a hemostat. *Anesth Analg* 2001; 93: 210-2. [\[CrossRef\]](#)
13. Vallejo MC, Adler LJ, Finegold H, Mandell GL, Ramanathan S. Periosteal entrapment of an epidural catheter in the intrathecal space. *Anesth Analg* 2001; 92: 1532-4. [\[CrossRef\]](#)
14. Lenox WC, Kost-Byerly S, Shipley R, Yaster M. Pediatric caudal epidural catheter sequestration: an unusual complication. *Anesthesiology* 1995; 83: 1112-4. [\[CrossRef\]](#)