



## Can the Endotracheal Tube Become a Threat to Airway Patency?

### Entübasyon Tüpü Havayolu Açıklığı İçin Tehdit Haline Gelebilir mi?

Tülay Özkan Seyhan, Mukadder Orhan Sungur, Emine Uzundere

Department of Anaesthesiology and Reanimation, İstanbul University İstanbul Faculty of Medicine, İstanbul, Turkey

Dear Editor,

Although intubation is considered as the gold standard to maintain airway safety, the intubation tube itself may at times pose as a danger (1, 2). We would like to share a rare problem with our colleagues pertaining to a smooth general anaesthesia process after obtaining patient's consent. The trachea of a patient (43 years, 63 kg, 162 cm and ASA I) who was undergoing general anaesthesia was intubated with an endotracheal tube (ETT; Chilecom Medical Devices Co. Ltd., China) of a 7.0 mm internal diameter; the ETT was fixed at a depth of 20 cm from the mouth angle. Anaesthesia circuit was fixed to prevent tube kinking while keeping the patient's head in neutral position. Peak airway pressure was 21 cm H<sub>2</sub>O during mechanical ventilation with tidal volume of 500 mL, 10 breaths min<sup>-1</sup> and an end-expiratory pressure of 5 cm H<sub>2</sub>O, whereas end-tidal CO<sub>2</sub> (EtCO<sub>2</sub>) was 32–33 mmHg. After 50 min, peak airway pressure started to increase and reached up to 40 cm H<sub>2</sub>O within few minutes. Because of pressure limitation, the tidal volume decreased to 200 mL with EtCO<sub>2</sub> of 20 mmHg. No problems were encountered when breath sounds, anaesthesia circuit, cuff of ETT and muscle relaxation were checked. Laryngoscopic inspection of ETT revealed no problem in the oral cavity, but a 14-Fr suction catheter did not pass through the ETT during tracheal aspiration attempt. The patient was extubated and reintubated with a new tube. Starting at the distance of 17 cm of the removed tube, a kink was observed that almost obstructed the lumen (Figure 1a, b). After approximately 20 min at room temperature, the kinking that narrowed the lumen of the intubation tube had significantly disappeared (Figure 2).

Polyvinyl ETTs are relatively resistant to kinking at room temperatures. However, at body temperatures, the tubes soften and may kink causing lumen occlusion even at very low angles (3). The exit point of the cuff line to the pilot balloon is often reported as the location of kinking (3). Head position other than neutral position (4) or shifting the position of the ETT (5)

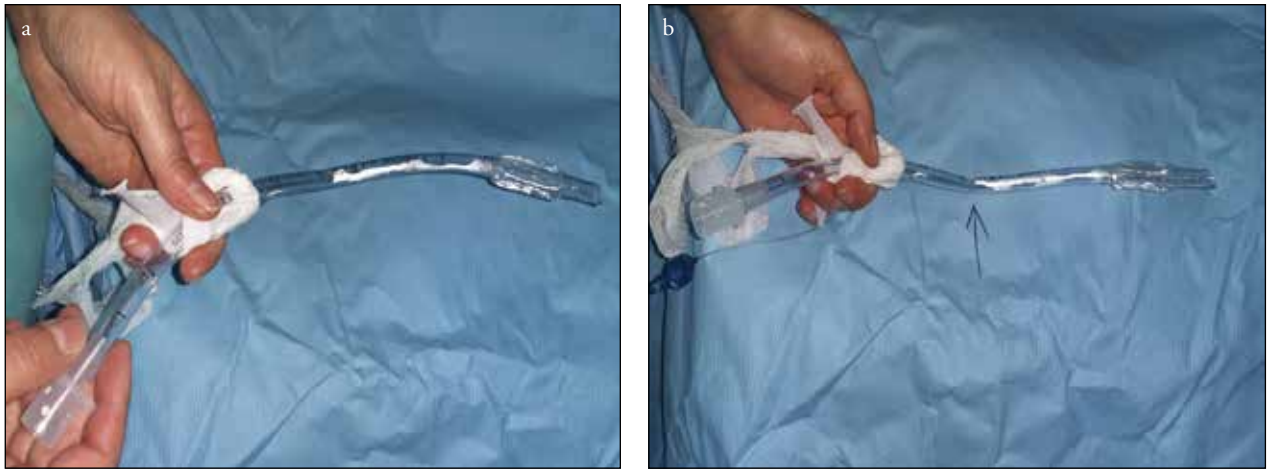

Figure 1. a, b. Kinked ETT from different views

**Address for Correspondence/Yazışma Adresi:** Dr. Tülay Özkan Seyhan, İstanbul Üniversitesi İstanbul Tıp Fakültesi Anesteziyoloji ve Reanimasyon Anabilim Dalı, 34093 Çapa, İstanbul, Türkiye E-mail: tulay2000@gmail.com

©Telif Hakkı 2015 Türk Anesteziyoloji ve Reanimasyon Derneği - Makale metnine www.jtaics.org web sayfasından ulaşılabilir.

©Copyright 2015 by Turkish Anaesthesiology and Intensive Care Society - Available online at www.jtaics.org

Received / Geliş Tarihi : 26.01.2015

Accepted / Kabul Tarihi : 04.05.2015

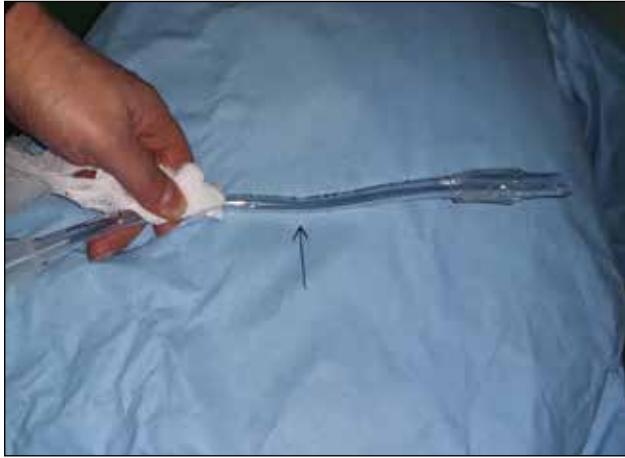


Figure 2. The restoration of luminal patency of kinked endotracheal tube at room temperature

may also contribute to kinking. For our patient, although the tube was secured at the distance of 20 cm at the right corner of the mouth, kinking started at approximately 3 cm from this point at the pharynx-larynx intersection. During laryngoscopic control with a Macintosh blade, we saw the dorsal side adjacent to the palate but could not detect the kink. In case of unaccounted airway pressure elevations (6), ETT must be controlled considering possible lumen blocking because of tube kinking within the mouth.

**Informed Consent:** Written informed consent was obtained from patient who participated in this study.

**Peer-review:** Externally peer-reviewed.

**Author Contributions:** Concept - T.Ö.S., M.O.S., E.U.; Design - T.Ö.S., M.O.S., E.U.; Supervision - T.Ö.S., M.O.S., E.U.; Funding - T.Ö.S., M.O.S.; Materials - T.Ö.S., M.O.S.; Data Collection and/or Processing - T.Ö.S., M.O.S., E.U.; Analysis and/or Interpretation - T.Ö.S., M.O.S., E.U.; Literature Review - T.Ö.S., M.O.S., E.U.; Writer - T.Ö.S., M.O.S., E.U.; Critical Review - T.Ö.S., M.O.S.

**Conflict of Interest:** No conflict of interest was declared by the authors.

**Financial Disclosure:** The authors declared that this study has received no financial support.

**Hasta Onamı:** Yazılı hasta onamı bu çalışmaya katılan hastadan alınmıştır.

**Hakem Değerlendirmesi:** Dış bağımsız.

**Yazar Katkıları:** Fikir - T.Ö.S., M.O.S., E.U.; Tasarım - T.Ö.S., M.O.S., E.U.; Denetleme - T.Ö.S., M.O.S., E.U.; Kaynaklar - T.Ö.S., M.O.S.; Malzemeler - T.Ö.S., M.O.S.; Veri Toplanması ve/veya İşlemesi - T.Ö.S., M.O.S., E.U.; Analiz ve/veya Yorum - T.Ö.S., M.O.S., E.U.; Literatür Taraması - T.Ö.S., M.O.S., E.U.; Yazıyı Yazan - T.Ö.S., M.O.S., E.U.; Eleştirel İnceleme - T.Ö.S., M.O.S.

**Çıkar Çatışması:** Yazarlar çıkar çatışması bildirmemişlerdir.

**Finansal Destek:** Yazarlar bu çalışma için finansal destek almadıklarını beyan etmişlerdir.

## References

1. Tunalı Y, Utku T, Korkmaz Dilmen Ö, Akçıl E. Acute airway obstruction due to dissection of the endotracheal tube. *J Turk Anaesth Int Care* 2012; 40: 158-62. [\[CrossRef\]](#)
2. Onisei A, Shroff P, Martin T. Defective endotracheal tube – cause of airway obstruction. *Paediatr Anaesth* 2003; 13: 739. [\[CrossRef\]](#)
3. Hübler M, Petrasch F. Intraoperative kinking of polyvinyl endotracheal tubes. *Anesth Analg* 2006; 103: 1601-2. [\[CrossRef\]](#)
4. Prakash S, Kumar A, Kumar M, Gogia AR. Successful detection and management of kinked tracheal tube in a patient with severe post-burn contracture of the neck. *Indian J Anaesth* 2013; 57: 90-1. [\[CrossRef\]](#)
5. Hariharan U, Garg R, Sood R, Goel S. Intraoperative kinking of the intraoral portion of an endotracheal tube. *J Anaesthesiol Clin Pharmacol* 2011; 27: 290-1. [\[CrossRef\]](#)
6. Borshoff D. *Anaesthetic Crisis Manual*. New York: Cambridge University Press; 2011, 26.