



Parotid Gland Mass as the Presenting Symptom of Nasopharyngeal Carcinoma

Parotis Bezi Kitlesi Olarak Semptom Veren Nazofarenks Karsinomu

Ayşegül Verim, Ömer Faruk Çalım*, Özge Düzacı Yüksel, Barış Naiboğlu, Çiğdem Tepe Karaca

Haydarpaşa Numune Education and Research Hospital, Clinic of Otorhinolaryngology, Head and Neck Surgery, İstanbul, Turkey

*Medipol University Hospital, Clinic of Otorhinolaryngology, Head and Neck Surgery, İstanbul, Turkey

Abstract

Even though metastatic tumors of the parotid gland are rarely seen, they are observed more frequently than other salivary gland metastatic masses. The reason why this gland is more frequently affected by metastatic tumors as compared to other salivary glands relies on the higher number of intraglandular and periglandular lymph nodes that the parotid gland contains. The incidence of metastatic parotid masses is relatively low compared to other head and neck neoplasms, consequently, few cases have been reported in the literature. Here, we present a patient referred to our clinic with parotid gland masses on both sides suggesting malignant neoplasm after fine needle aspiration biopsy of both sides. In this report, we aimed to draw attention to nasopharyngeal carcinoma metastasis in the differential diagnosis of parotid gland masses and to emphasize the importance of a careful endoscopic examination and magnetic resonance imaging before deciding on total parotidectomy. (*The Medical Bulletin of Haseki 2014; 52: 130-2*)

Key Words: Parotid gland, metastasis, nasopharyngeal carcinoma

Introduction

Salivary gland tumors constitute 3% of the neoplasms in the body and 5%-10% of the head and neck tumors (1). 80% of salivary gland tumors are of parotid gland origin. Of these 80% are benign and 20% are malignant (2). However, metastatic tumors are rarely seen in parotid glands. In almost all of them, the primary tumor is located in the head-neck region (3).

Özet

Parotisin metastatik tümörleri nadir olarak görülmesine rağmen diğer tükürük bezlerinin metastatik kitlelerinden daha sık olarak izlenir. Bu bezin metastazdan diğer tükürük bezlerine göre daha sık etkilenmesinin nedeni içerisinde bulunan intraglandular lenf nodları ve periglandüler nod sayısının daha fazla olmasındandır. Kliniğimize yüzünün her iki yanında parotis kitlesi nedeni ile refere edilen ve ince iğne aspirasyon biopsilerinin sonucu maligniteyi düşündüren bulgular olarak rapor edilen bir hasta vesilesiyle total parotidektomi kararı vermeden önce nazofarinks karsinom metastazını ekarte etmenin ve dikkatli bir endoskopik muayene ve manyetik rezonans görüntülemenin önemini vurgulamak istedik. (*Haseki Tıp Bülteni 2014; 52: 130-2*)

Anahtar Sözcükler: Parotis, metastaz, nazofarenks karsinomu

The parotid gland contains both extraglandular and intraglandular lymphatic nodes. These lymphatic node groups are interrelated by means of intermediary connections. Lymphatic drainage is mainly into the superior deep jugular lymph nodes that are near the superficial lobe of parotid gland (4). Both the node groups are affected by tumor invasion and metastasis (5).

Address for Correspondence/Yazışma Adresi: Ömer Faruk Çalım

Medipol University Hospital, Clinic of Otorhinolaryngology, Head and Neck Surgery, İstanbul, Turkey

GSM: +90 505 392 92 74 E-mail: omercalim@yahoo.com

Received/Geliş Tarihi: 22 Eylül 2013 **Accepted/Kabul Tarihi:** 14 Kasım 2013

33th Turkish National Otorhinolaryngology and Head and Neck Surgery was presented at the Congress

The Medical Bulletin of Haseki Training and Research Hospital, published by Galenos Publishing.

Haseki Tıp Bülteni,
Galenos Yayınevi tarafından basılmıştır.

Metastases to the parotid gland mostly originate from mucosal or epithelial tumors of the head and neck (6). The incidence of metastatic parotid masses is relatively low compared to all the head and neck neoplasms, thus, the number of reported cases are very limited (2,3).

Although rare, parotid gland can also be metastasized from distant neoplasms in the body such as renal cell carcinoma, lung, breast, prostate or gastrointestinal (GI) tract malignancies, leukemia and lymphoma (7).

Metastasis to salivary glands may essentially occur via hematogenous and lymphatic routes. The most common affected salivary gland by metastasis is the parotid gland (3). The relative frequency of metastases in the lymph nodes of the parotid gland is due to numerous lymph vessels and lymph nodes, which are localized in the gland parenchyma or around the parotid gland.

In this paper, we present a 67-year-old patient referred to our clinic for bilateral parotid neoplasms detected by fine needle aspiration biopsy (FNAB) of both sides. The patient, who in fact had nasopharyngeal carcinoma with metastasis to the parotid glands, was treated with radiotherapy.

Case

A 67-year-old male presented to the plastic surgery clinic with masses on his both cheeks that appeared 2 months ago. On ultrasonographic evaluation, cystic masses measuring 4x5 cm and 2x3 cm were identified on his right and left cheeks, respectively. FNAB of both sides reported malignant epithelial cells of unknown primary origin. The patient was scheduled for surgery in the Department of Plastic Surgery and a consultation was requested from the Department of Otorhinolaryngology (ORL).

On examination, masses extending from the tragus to the mandibular angle were observed on both sides of the patient's face. These masses were non-tender, mobile, rubber-like swellings located within the parotid gland parenchyma (Figure 1).

Endoscopic examination revealed a soft, yellow-gray colored, polypoid mass hanging from the right lateral wall of the nasopharynx (Figure 2). However, a perforation in the right tympanic membrane, opacity and slight retraction in the left tympanic membrane were observed on otoscopy.

Since the nasal endoscopy was normal, the polyp was considered to arise from the nasopharynx. Thus, magnetic resonance imaging (MRI) was requested for further investigation. A well delineated mass in the right lateral nasopharyngeal wall was displayed on contrast-enhanced MRI (Figure 3) and the patient underwent endoscopic biopsy of the nasopharynx. Histopathologic analysis of the biopsy material revealed WHO Type III nasopharyngeal

carcinoma. Subsequently, the patient was referred to the radiation oncology clinic for radiation therapy to the nasopharynx and neck. The masses on both the parotid glands and nasopharynx were all cured after radiotherapy and the patient is free of disease at 1-year follow-up.

Discussion

Metastasis to the parotid is mostly from skin squamous cell cancers or melanomas of the head and neck. Since the parotid lymphatic system receives drainage from multiple

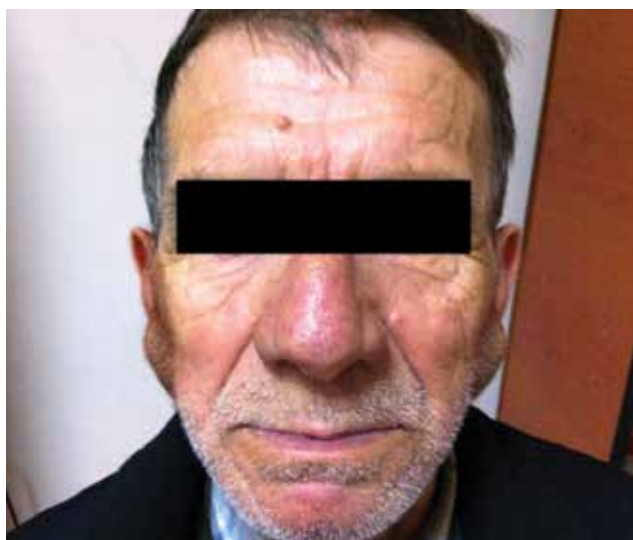

Figure 1. Left and right parotid masses

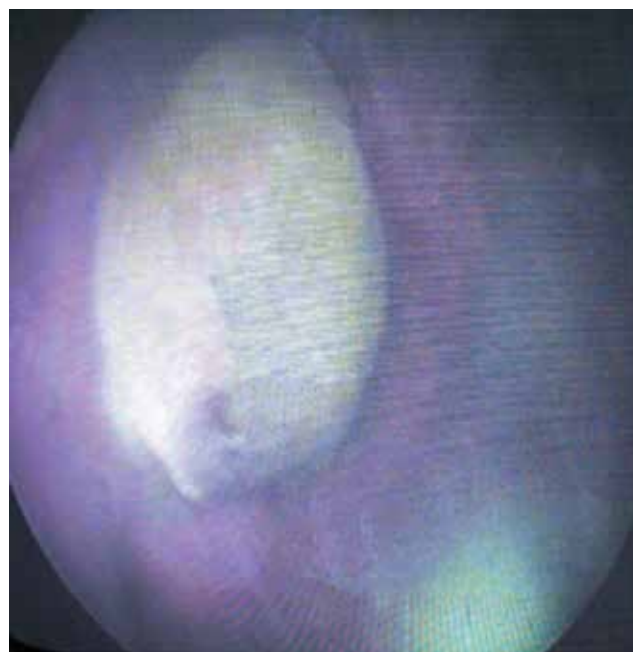


Figure 2. Polypoid mass on the right lateral wall of the nasopharynx

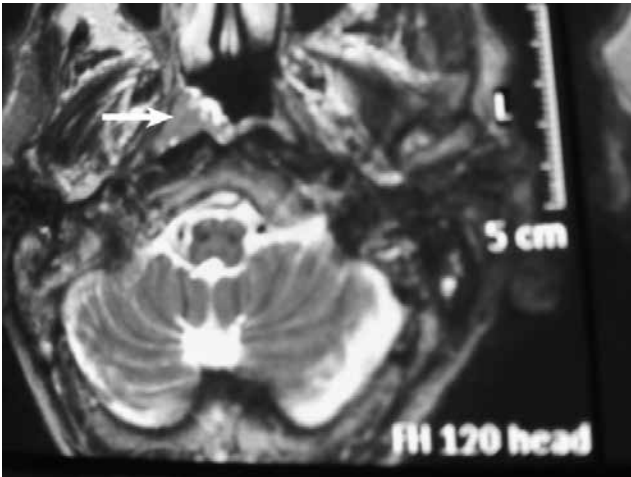


Figure 3. MRI: A mass on the right lateral wall of the nasopharynx

lymph nodes, metastatic tumors that originate from distant primary tumors may involve the parotid gland (8).

Parotid gland metastatic masses may mimic primary parotid tumors. Metastasis can occur via lymphatic or hematogenous spread. Invasion via lymphatic spread originates from supraclavicular primary tumors and affects intraglandular lymph nodes. Whereas, invasion via hematogenous spread, which is very rarely seen, originates from infraclavicular primary neoplasms such as carcinomas of the chest, kidneys and lung and affects parotid gland parenchyma (9).

Metastasis from the nasopharynx to both parotid glands is extremely rare. A few cases have been reported in the literature (10-14). If a malignant lymphoepithelial lesion is identified on FNAB of the parotid gland, it is a prerequisite to determine whether it is a primary or a metastatic one. It should be kept in mind that the primary origin of a metastatic malignant lymphoepithelial lesion located in the parotid gland could be the nasopharynx. Since the primary lesion in the nasopharynx could be submucosal, a single endoscopic examination is not enough for identifying the primary tumor. A contrast-enhanced MRI should be taken to verify the existence of a submucosal lesion (14,15).

Once it is definitely confirmed with the histopathological analysis of the biopsy material that the primary lesion is originated from the nasopharynx, the treatment of choice should certainly be treating the primary lesion. Unless

the primary lesion is taken under treatment, there is no possibility that the metastasis can be cured (13). However, if the radiation therapy to the nasopharynx and neck fails to treat the parotid metastasis, it is essential to perform total parotidectomy and neck dissection.

Metastatic neoplasms should always be kept in mind and ruled out in case of parotid masses that rapidly develop and MRI should be requested to determine the origin of the primary tumor.

References

- Schwentner I, Obrist P, Thumfart W, Sprinzl G. Distant metastasis of parotid gland tumors. *Acta Otolaryngol* 2006;126:340-5.
- Yeh S. The salivary glands. In: JJ. Ballenger, editor. *Diseases of the nose throat ear, Head and Neck*. Baltimore: Lea and Febiger; 1991. p. 299-311.
- Luna MA. Pathology of tumors of the salivary glands. In: Thawley SE, Panje WR, Batsakis JG, Lindberg RD, editors. *Comprehensive management of head and neck tumors*. Philadelphia: W.B Saunders; 1987. p. 1082-4.
- Spiro RH, Spiro JD. Cancer of salivary glands. In: Myers EN, Suen JY editors. *Cancer of the Head and Neck*. Newyork : Churchill Livingstone; 1989. p. 645-68.
- Kaplan MJ, Johns ME. Malignant neoplasm of salivary glands. In: Cummings CW, Fredrickson JM, Krause CJ, Harker LA, Schüller DE, editors. *Otolaryngology-Head and Neck Surgery*. St Louis: Mosby Year Book; 1993. p. 1043-78.
- O'Brien CJ1, Uren RF, Thompson JF, et al. Prediction of potential metastatic sites in cutaneous Head and Neck melanoma using lymphoscintigraphy. *Am J Surg* 1995;170:461-6.
- Inal IE1, Borçbakan C, Sützen T. Clinical features of parotid gland malignancies. *Acta Otorhinolaryngol Ital* 1990;10 Suppl 29:13-6.
- Bergerson PJ, Kennedy PJ, Kneale KL. Metastatic tumors of the parotid region. *Aust N Z J Surg* 1987;57:23-6.
- Batsakis JG, Bautino E. Metastases to major salivary glands. *Ann Otol Rhinol Laryngol* 1990;99:501-3.
- Seifert G, Hennings K, Caselitz J. Metastatic tumors to the parotid and submandibular glands-analysis and differential diagnosis of 108 cases. *Pathol Res Pract* 1986;181:684-92.
- Saw D, Ho JH, Lau WH, Chan J. Parotid swelling as a first manifestation of nasopharyngeal carcinoma: a report of two cases. *Eur J Surg Oncol* 1986;12:71-5.
- Rees R, Maples M, Lynch JB, Rosenfeld L. Malignant secondary parotid tumors. *South Med J* 1981;74:1050-2.
- Tüz M, Çetin O, Turanlı M, Taşel M, Ugan G. Parotis bezinin metastatik tümörleri. *K.B.B. ve Baş Boyun Cerrahisi Dergisi* 1999;7:131-4.
- Joshi SW, Pavar A, Lakhkar D. Unusual metastatic tumour of parotis - Report of two cases. *Ind J Radiol Imaging* 2005;15:205-7.
- Chong VF1, Fan YF. Parotid gland involvement in nasopharyngeal carcinoma. *J Comput Assist Tomogr* 1999;23:524-8.