

HETEROTOPIC CERVICAL PREGNANCY WITH FETAL SURVIVAL

Semra KAYATAS¹, Elif MESECI², Erbil CAKAR¹, Sevcan Arzu ARINKAN¹, Kadir GUZIN²

¹ Zeynek Kamil Women and Children Diseases Hospital, Istanbul, Turkey

² Medeniyet University, Goztepe Research and Training Hospital, Istanbul, Turkey

SUMMARY

Heterotopic pregnancy is defined as a uterine pregnancy in conjunction with an extrauterine pregnancy. Cervical heterotopic pregnancy represents a rare type of ectopic pregnancy, reported to be less than 0.1% of all pregnancies. We present the case of a rare event of a simultaneous intrauterine gestation combined with cervical heterotopic pregnancy in a natural conception cycle. A 32 year old primigravid women presented with vaginal bleeding and 8 weeks of amenore. The pelvic examination revealed a intrauterine pregnancy and heterotopic cervical pregnancy. Heterotopic cervical pregnancy terminated uneventfully by curettage and using cervical sutures to ligate lateral cervical vessels to prevent bleeding. Pregnancy was continued up to 36 weeks of gestation and healthy baby was born.

Key words: alive birth, cervical pregnancy, heterotopic

Journal of Turkish Society of Obstetrics and Gynecology, (J Turk Soc Obstet Gynecol), 2014; Vol: 11, Issue: 1, Pages: 64-7

CANLI DOĞUM İLE SONUÇLANAN HETEROTOPİK GEBELİK OLGUSU

ÖZET

Heterotopik gebelik rahim içinde bulunan normal bir gebeliğe aynı anda dış gebeliğin eşlik etmesidir. Servikal gebelik ektopik gebeliklerin çok nadir görülen bir şeklidir ve %0.1'den daha az sıklıkta görülür. Biz burada; normal siklusta olmuş olan, intrauterine gebeliğe eşlik eden heterotopik servikal gebelik olgusunu sunduk. 32 yaşında primigravid olan olgumuz vajinal kanama ve 8 haftalık adet rötari şikayeti ile başvurdu. Yapılan pelvik muayenede heterotopik servikal gebeliğin eşlik ettiği intrauterine canlı gebelik saptandı. Kanamayı durdurmak amacı ile lateral servikal damarlara servikal sütürler konarak heterotopik servikal gebelik kürete edildi. İntrauterine gebelik sorunsuz bir şekilde 36.haftaya kadar devam etti ve sağlıklı, canlı doğum gerçekleştirildi.

Anahtar kelimeler: canlı doğum, heterotopik, servikal gebelik

Türk Jinekoloji ve Obstetrik Derneği Dergisi, (J Turk Soc Obstet Gynecol), 2014; Cilt: 11, Sayı: 1, Sayfa: 64-7

Address for Correspondence: Sevcan Arzu Arıkan. Zeynep Kamil Eğitim ve Araştırma Hastanesi, Üsküdar, İstanbul
Phone: +90 (505) 683 75 57
e-mail: pataraa96@gmail.com

Received: 09 May 2013, revised: 13 June 2013, accepted: 18 July 2013, online publication: 21 July 2013

INTRODUCTION

Heterotopic pregnancy is defined as a uterine pregnancy in conjunction with an extrauterine pregnancy. It was described by Duverney in 1708⁽¹⁾. In the past spontaneous heterotopic pregnancy have occurred in approximately 1 in 30.000 pregnancies. The increasing incidence of ectopic pregnancies especially together with in vitro fertilisation mean that the increasing incidence of combined pregnancy as many as 2 in 15.000 live births⁽²⁾. Cervical heterotopic pregnancy represents a rare type of ectopic pregnancy, reported to be less than 0.1% of all pregnancies^(3,4). Pelvic inflammatory disease, use of an intrauterine device, ovulation induction and in vitro fertilisation has been related to the increased incidence of cervical pregnancy, but a direct relationship with heterotopic pregnancy has not been proved^(5,6). IVF centers reported an incidence of heterotopic pregnancy as 0.75-1.3 %⁽⁷⁾.

Cervical heterotopic pregnancy is a life threatening condition with the potential of profuse vaginal bleeding because of cervical vessels erosion⁽⁴⁾. In heterotopic pregnancy, also existence of intrauterine pregnancy with ectopic pregnancy remains a diagnostic dilemma that demands special consideration and also increases both maternal and fetal mortality. In the past, cervical pregnancy remains undiagnosed, so these patients commonly presented with massive bleeding leading to hysterectomy and even death^(2,5). The diagnosis of the heterotopic pregnancy is difficult as the symptomatology is often misleading. Improvements in ultrasound resolution resulted in earlier detection of such pregnancies which results in conservative treatment. While ultrasonography has greatly aided in the management of several cases, also increased clinical awareness and suspicion which can yield improved diagnostic accuracy.

We present the case of a rare event of an intrauterine gestation combined with cervical gestational sac. The patient was managed successfully. Cervical pregnancy terminated uneventfully and resulted with alive baby.

CASE

A 32 year old primigravida woman was admitted to the our clinic. She was first seen with complaint of

severe vaginal bleeding with 8 weeks of amenore. At admission, the patient's vital signs were stable, laboratory tests were normal and her pregnancy test was positive. The gynecological examination revealed; massive cervical bleeding with dilated cervix, the uterus soft and minimally enlarged as six-week sized with normal adnexal findings. On abdominal examination no defans and rebound were detected. Ultrasonographic examination demonstrated an intrauterine gestational sac in fundal region with embryo and yolk sac and fetal heart activity. In addition, another gestational sac was demonstrated in the cervix with a yolk sac without an embryo (Figure 1).

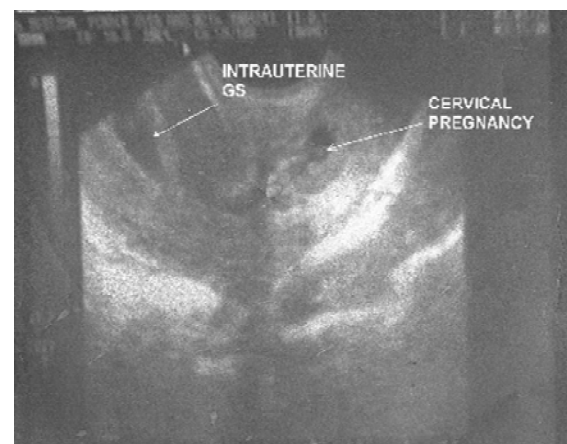


Figure 1: Intrauterine gestational sac with heterotopic intracervical gestational sac.

Because of massive bleeding surgical intervention was preferred. The patient was given a full and detailed explanation regarding the risk of hysterectomy if required. Written informed consent was obtained from the patient. Abdominal ultrasonography guided cervical curettage was performed uneventfully under general anesthesia by using two cervical sutures at the two-four and eight-ten o'clock positions to ligate lateral cervical branches of uterine arteries to prevent bleeding during cervical curettage. We controlled the bleeding, to maintain intrauterine pregnancy. This procedure was performed without complications for the intrauterine pregnancy. Then vaginal bleeding was stopped. At the end of the procedure transvaginal sonography confirmed the intrauterine embryo with fetal heart activity (Figure 2). Histopathological examination of the cervical curratage material revealed chorionic villi (Figure 3). The patient was counseled again regarding the continuation of intrauterine pregnancy and discharged on postoperative second

day with no vaginal bleeding. Pregnancy was continued up to 36 weeks of gestation and alive baby was born.

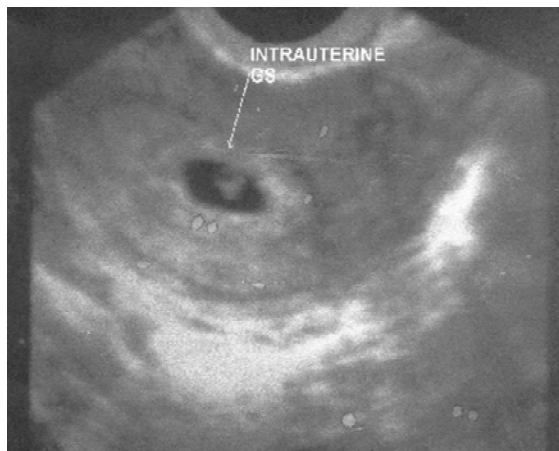

Figure 2: Intrauterine gestational sac after curettage of the intracervical canal.

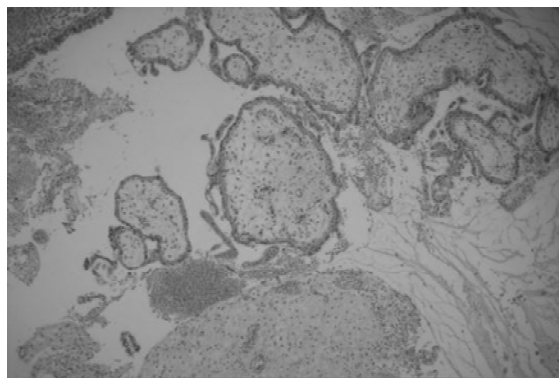


Figure 3: Immatur chorionic villus and decidua.

DISCUSSION

The spontaneous heterotopic pregnancy is rare and life threatening condition. Recognizing this form of pregnancy is often rendered difficult by an asymptomatic clinical course and by the inability to use β -HCG (beta human chorionic gonadotropin) to establish the correct diagnosis. Diagnosis therefore relies on suspicion and ultrasonography because observation of intrauterine pregnancy with ultrasonography misleads the clinician and a coexisting ectopic pregnancy might be overlooked, resulting in increased morbidity and mortality. Improvements in ultrasonography results in early and correct diagnosis and so improvements in morbidity and mortality and succes of conservative procedures.

In heterotopic pregnancy about 95% of extrauterine implantations occur in the tuba. Ectopic implantations

occur less often in the ovary 0.5 %, in cervix 0.1% and peritoneal cavity 0.03 %⁽¹⁾. The uterine bleeding is rare in heterotopic pregnancy. Also other syptoms are; abdominal pain 81.8%, adnexal mass 43.9%, peritoneal irritation 43.9% and enlarged uterus 42.4% were the classical clinical futures depending on the location of associated combined pregnancy⁽³⁾.

Attemts have been made to treat cervical pregnancies by using surgical or medical treatment modalities. Surgical conservative treatments include intraamniotic aspiration with placement of cervical sutures, hypogastric iliac artery ligation, uterine artery embolisation followed by either dilatation and evacuation or systemic metotrexate administration, hysteroscopic resection. Medical conservative treatments include intraamniotic or cardiac injection of potassium chloride or metotrexate, intraamniotic injection of hypertonic solution^(3,6). Depending on location, metotrexate administered either systemically or locally to decrease vascularization of the mass, thus reducing blood loss and it has been reported as effective therapy⁽⁸⁾.

Conservative approaches can be used succesfully if up to 10 to 12 weeks of pregnancy was present because in advanced pregnancy trophoblastic tissue infiltrates deeply in to cervical wall⁽³⁾. If uncontrolled bleeding was started or if heterotopic pregnancy diagnosed at second or third trimester of pregnancy; radical treatment like hysterectomy was recommended. There is no universally accepted treatment modality. Some reports published concerning heterotopic cervical pregnancy treated with curettage and foley catheter ballon which is also combined with cervical cerclage^(9,10). Various type of conservative management to save an intrauterine pregnancy have been attempted and have a different results. In literature some author reported a tubal and counal heterotopic pregnancy which was succesfully treated and resulted with a alive baby^(11,12). In Cho JH et al. study, simple cervical embryo aspiration under transvaginal ultrasonography guidance was reported as a succesfull procedure⁽¹³⁾. Fruscalzo A. et al. demonstrated a spontaneous abortion after cervical pregnancy termination with same technique⁽¹⁴⁾. In Moragianni et al study, they reviewed 39 reported cases with heterotopic cervical pregnancy and alive intrauterine pregnancy. They found that 27 cases result in viable delivery of intrauterine gestation without compromising the patients reproductive capacity⁽¹⁵⁾.

In our case because of detrimental effect of metotrexate

on intrauterine normal pregnancy and also because of bleeding, we prefer the surgical conservative approach with curettage of cervical canal as a first choice. Although fetal mortality rate have ranged from 20% to 70% for the intrauterine pregnancy, the extrauterine gestation has a mortality rate greater than 90%(1). In our case intrauterine gestational sac and embryo were not effected from this procedure and surgical intervention was performed succesfully without complications for the intrauterine pregnancy.

Cervical pregnancy combined with intrauterine pregnancy is very rare case. Recognizing this form of pregnancy is often rendered difficulty. Diagnosis therefore relies on suspicion. There is no standart protocols for the management of heterotopic pregnancy. Treatment depends on the time of diagnosis, symptom of patients, location of extrauterine pregnancy , fertility desire and the condition of intrauterine pregnancy. Hysterectomy can be avoided by early diagnosis.

REFERENCES

1. Te Linde R, Rock JA, Thompson JD. Ectopic Pregnancy Telinde's Operative Gynecology. Eight edition, Philadelphia 1996;23(2):501-29.
2. Schorge JO, Schaffer JI, Halvorson LM. Williams Gynecology 2008;20(6):157-71.
3. Hirakawa M, Tajima T, Yoshimitsu K. Uterine artery embolisation along with the administration of methotrexate for cervical ectopic pregnancy: Technical and clinical outcomes. *AJR Am J Roentgenol* 2009;192(6):1601-7.
4. Kaya S, Kayah B, Keskina L, Avşar F. Heterotopic Pregnancy in a natural conception: Case Report. *Turkiye Klinikleri J Gynecol Obst* 2012;22(3):178-80.
5. Şekeroğlu M, Tekelioğlu M, Badar M, Göker N. Heterotopic pregnancy in a spontaneous cycle: case report *Turkiye Klinikleri J Gynecol Obst* 2008;18(1):65-7.
6. Shahh A, Grotegut CA, Likes CE . Heterotopic cervical pregnancy treated with transvaginal ultrasound guided aspiration resulting in cervical site varices within the myometrium. *Fertil Steril* 2009;91(3):934:e19-22.
7. Habana A, Dokras A, Giraldo JL. Cornual heterotopic pregnancy contemporary managements option. *Am J Obstet Gynecol* 2000;182(5):1264-70.
8. Hung TY, Shau WY, Hsieh TT, Hsu JJ, Soong YK, Jeng CJ. Prognostic factors for an unsatisfactory primary methotrexate treatment of cervical pregnancy: a quantitive review. *Hum Reprod* 1998;13(9):2636-42.
9. Fylstra DL, Coffey MD. Treatment of cervical pregnancy with cerclage, curettage and bolloon tamponade. A report of three cases. *J Reprod Med* 2001;46(1):71-4.
10. De La Vega GA, Avery C, Nemiroff R, Treatment of early cervical pregnancy with cerclage, carboprost, curettage and balloon tamponade. *Obstet Gynecol* 2007;109(2 Pt2):505-7.
11. Yeniel AÖ, Ergenoğlu AM, Sanhal CY, İtil İM. Geçirilmiş lineer salpingostomi sonrası spontan heterotopik gebelik olgusu ve laparoskopik tedavi: Olgu sunumu *J Turk Soc Obstet Gynecol* 2012;9(1):1-5.
12. Özerkan K, Develioğlu OH, Akşan A, Kimya Y. Canlı bir doğumla sonuçlanan heterotopik kornual gebelik; bir olgu sunumu *J Turk Soc Obstet Gynecol* 2006;3(5):342-6.
13. Cho JH, Kwon H, Lee KW, Cervical heterotopic pregnancy after assisted reproductive technology succesfully treated with only simple embryo aspiration: a cese report. *J Reprod Med* 2007;52(3):250-2.
14. Fruscalzo A, Mai M, Löbbeke K. A combined intrauterine and cervical pregnancy diagnosed in the 13th gestational week: Which type of management is feasible and succesful? *Fertil Steril* 2008;89(2):456.e13-6.
15. Moragianni VA, Hamar BD, McArdle C, Ryley DA. Management of a cervical heterotopic pregnancy presenting with first-trimester bleeding: case report and review of the literature. *Fertil Steril* 2012;98(1):89-94.