

A Gallbladder Mercedes-Benz Sign in Acute Hepatitis A

Akut Hepatit A Olgusunda Safra Kesesinde Mercedes-Benz İşareti

Özüm Tunçyürek¹, Elif Çetinkaya², Aslı Kuru³

¹Adnan Menderes University Faculty of Medicine, Department of Radiology, Aydın, Turkey

²Atatürk State Hospital, Clinic of Internal Medicine, Aydın, Turkey

³Atatürk State Hospital, Clinic of Infectious Diseases, Aydın, Turkey



Abstract

A 26-year-old male presented to the emergency department with the complaints of abdominal pain, fever, nausea and vomiting. During the abdominal ultrasound examination of the patient, who was taken to the intensive care unit due to stomach ache and nausea, the size of the long axis of the right lobe of the liver was found to be 140 mm. An about 1.5-cm lymphadenopathy was detected in the hilum. On portal venous phase-enhanced computed tomography (CT), the gallbladder wall thickness was 8 mm and pericholecystic and pelvic fluids were observed. Following biochemical tests, the patient was diagnosed with acute hepatitis A. In this case, it was an interesting finding that the gallbladder wall took the form of a Mercedes-Benz sign observed on CT, as a finding of hepatitis A for the first time in the literature.

Öz

Yirmi altı yaşındaki erkek olgu acil servise karın ağrısı, ateş, bulantı ve kusma yakınması ile başvurdu. Karın ağrısı ve mide bulantısı yakınmaları ile yoğun bakımda takibe alınan olgunun abdominal ultrason tetkikinde karaciğer sağ lob uzun aksı 140 mm bulundu. Karaciğer hilusunda 1,5 cm'lik lenfadenopati mevcuttu. Olgu bilgisayarlı tomografi (BT) tetkiki ile incelendi. Portal venöz faz kontrastlı BT incelemesinde, safra kesesi duvar kalınlığı 8 mm olup, perikolesistik ve pelvik serbest sıvı saptandı. Yapılan biyokimyasal testler sonrasında olgu akut hepatit A tanısı aldı. Bu olguda ilginç olan bulgu BT tetkikinde literatürde ilk kez tanımlanacak olan safra kesesi duvarında izlenen Mercedes Benz işaretidir.

Keywords

Hepatitis A, gallbladder, liver, inflammation

Anahtar Kelimeler

Hepatit A, safra kesesi, karaciğer, enflamasyon

Received/Geliş Tarihi : 08.09.2014

Accepted/Kabul Tarihi : 09.09.2014

doi:10.4274/meandros.1807

Address for Correspondence/Yazışma Adresi:

Özüm Tunçyürek MD,
Adnan Menderes University Faculty of
Medicine, Department of Radiology, Aydın,
Turkey
Phone : +90 530 143 76 69
E-mail : ozum.tuncyurek@gmail.com

©Meandros Medical and Dental Journal,
published by Galenos Publishing.

©Meandros Medical and Dental Journal,
Galenos Yayınevi tarafından basılmıştır.

Introduction

The most frequent causes of acute hepatitis include viral infections A, B, and C, medicine/alcohol overdose, and autoimmunity. Although the presence of high serum aminotransferase is important for diagnosis, it may sometimes be indispensable to do a biopsy for differential diagnosis, severity, and prognosis. Before arriving at this stage, imaging findings are utilized for differential diagnosis. They are ultrasonography (US) and contrast-enhanced computed tomography (CT), the cheaper and easy-to-access methods. Thanks to them, biliary obstruction, cirrhosis and metastasis may be ruled out. In

acute hepatitis A, hepatosplenomegaly, lymph node enlargement in the hilar-hepatoduodenal ligament, an increase in gallbladder wall thickness (GWT) and the intra-abdominal free fluid can be detected using both imaging methods, whereas a decrease in periportal density is a finding unique on CT and an increase in echogenicity is a finding unique to US (1). In this case presentation the interesting finding was a Mercedes-Benz sign on the gallbladder wall as a finding of hepatitis A. Our aim was to emphasize the importance of increased GWT in cases with acute hepatitis.

Case Report

A 26-year-old male presented to the emergency service with nausea and vomiting. During the abdominal US examination of the patient, who was taken to the intensive care unit due to abdominal ache and vomiting, the size of the long axis of the right lobe of the liver was found to be 140 mm. A lymph node with a diameter of about 1.5-cm was detected in the hilum (Figure 1). The GWT was 8 mm, and pericholecystic and pelvic fluids were present. No stone was detected in the lumen of the gallbladder. The parenchymal echogenicity of the liver and the size of the pancreas were normal, however, the pancreas echo pattern was minimally heterogeneous. The case was subjected to a CT examination to rule out pancreatitis. In his portal venous phase CT examination, it was observed that the density of the liver was homogeneous and that the gallbladder was contracted and was in the form of a Mercedes-Benz sign (Figure 2). The wall thickness was increased. The pancreas was homogeneous, and no evident decrease was detected in the parenchymal density-in agreement with pancreatitis-. The results of the liver function test were as the following; aspartate aminotransferase (AST): 1064 U/L, alanine aminotransferase (ALT): 1463 U/L, lactate dehydrogenase: 609 U/L, gamma glutamyltransferase: 239 U/L, total bilirubine: 3.3 mg/dl, direct bilirubin: 2.2 mg/dl, and indirect bilirubin: 1.1 mg/dl.

Discussion

A thick gallbladder wall is one of the findings observed on US in acute hepatitis. Hepatomegaly, a decrease in the periportal density, parenchymal heterogeneity of the liver and enlargement of the lymph nodes in the hilum are additional findings

which are observed on CT. Identical findings are also observed on US (2). On CT, lymphadenopathy and an increase in the GWT are determined more easily (3). A finding of periportal tracking indicates periportal edema (Figure 3) and perivenous edema (Figure 4, 5). Liver heterogeneity detected on arterial phase dynamic CT of the liver is a specific finding in acute hepatitis (4). Most of these findings are present in the icteric phase of acute hepatitis (1). It is hard to identify the increase in GWT by US when the free fluid is present. It is determined more easily on CT (Figure 2). An increase in the GWT is detected on ultrasound at rates ranging from 51% to 91% (4,5). In their study, Maresca et al. (4) have reported that there were morphological changes in the gallbladder in 80% of patients within 7 days after the onset of symptoms. If the GWT was greater than 3 mm, Park et

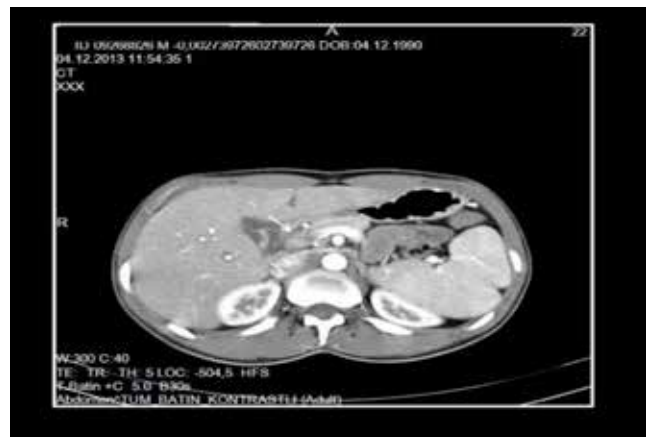

Figure 1. An about 1.5-cm lymphadenopathy in the hepatoduodenal ligament

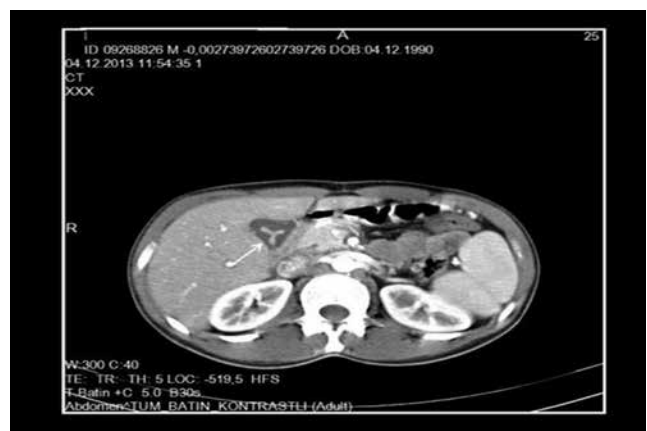

Figure 2. Gallbladder wall thickening-the Mercedes-Benz sign

al. (3) considered it abnormal and found it abnormal in 56.6% of the cases with acute hepatitis. In our case, the GWT was 8 mm-greater than 3 mm-. Periportal tracking and lymph node enlargement, which Park et al. (3) determined at 80% in their study, were also detected in our case. Also, they showed that arterial heterogeneity, periportal tracking, lymph node enlargement >7 mm, and ascites was 294 (80.1%), 348 (84.7%), 346 (84.5%), and 56 (13.6%), respectively. In some studies, an increase in the GWT was found to be accompanied by an increase in serum aminotransferase (6). However, this correlation could not be determined in some studies (7). Suk et al. (7) showed a significant correlation between GWT and increases in serum bilirubin. In our case, the AST and ALT values were 30 fold the normal values. Park et al. (3) reported that inflammation of the liver caused an inflammatory reaction on the gallbladder wall. Gallbladder wall thickening observed in cases with chronic renal failure and cirrhosis is also accompanied by hypoalbuminemia (2). The correlation of imaging findings (lymph node enlargement in the

hepatoduodenal ligament, periportal tracking, and an increase in GWT) with liver function blood tests reveals liver injury and hepatic dysfunction more clearly. In the study by Park et al. (3), the male gender, toxic hepatitis, a low level of albumin and an increase in GWT were stated to be the indicators of acute hepatitis. In addition, an increase in GWT and high levels of bilirubin indicate prolonged cholestasis, for if the GWT is smaller than 5 mm in 20% of the cases with hyperbilirubinemia during CT, prolonged cholestasis might be mentioned. An increase in GWT is associated with the degree of severity of acute hepatitis.

In 1992, Black and Mann (8) have reported a case of acute gangrenous cholecystitis due to hepatitis A infection in a pediatric patient. Kaya et al. (9) also showed that cholecystitis was a rare complication of acute viral hepatitis. The pathophysiology behind this phenomenon is complicated. The inflammation of hepatocyte and parenchyma alters bile flow and has been accused as the main cause of symptomatic gallbladder inflammation (10,11). To protect against radiation exposure in young cases, examinations such as MRI or US might be utilized. Nevertheless, if it is suspected that a simultaneous attack of inflammatory pancreatitis exists, CT should be the first alternative for differential diagnosis. Abdominal CT findings and biochemical tests of the liver correlate in acute hepatitis. Increased GWT is a predictive finding independent of prolonged cholestasis or the severity of acute hepatitis.

Ethics

Informed Consent: Confirmation has not been received from the patient by the reason of it could not reached him in the process of preparing the article.

Peer-review: Externally peer-reviewed.

Authorship Contributions

Surgical and Medical Practices: Elif Çetinkaya, Aslı Kuru, Concept: Özüm Tunçyürek, Design: Özüm Tunçyürek, Data Collection or Processing: Elif Çetinkaya, Aslı Kuru, Analysis or Interpretation: Özüm Tunçyürek, Literature Search: Özüm Tunçyürek, Elif Çetinkaya, Aslı Kuru, Writing: Özüm Tunçyürek, Elif Çetinkaya, Aslı Kuru.

Conflict of Interest: No conflict of interest was declared by the authors.

Financial Disclosure: The authors declared that this study has received no financial support.

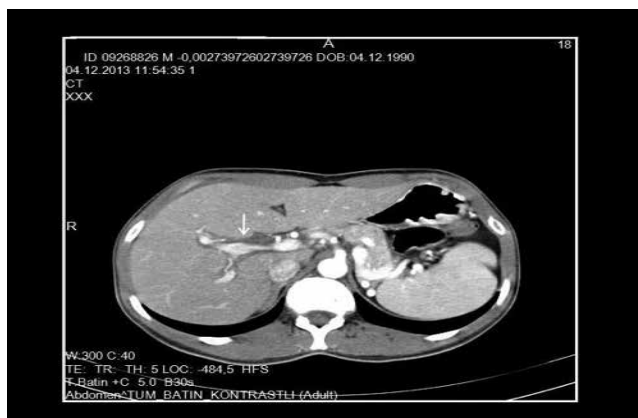

Figure 3. The portal venous phase liver computed tomography showing periportal tracking

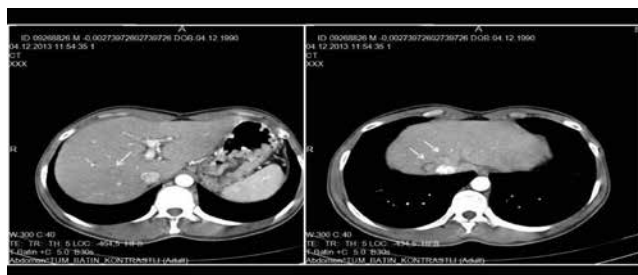


Figure 4, 5. Finding of hypodense halo-edema around the hepatic veins

References

1. Yoo SM, Lee HY, Song IS, Lee JB, Kim GH, Byun JS. Acute hepatitis A: correlation of CT findings with clinical phase. *Hepatogastroenterology* 2010; 57: 1208-14.
2. Zissin R, Osadchy A, Shapiro-Feinberg M, Gayer G. CT of a thickened-wall gall bladder. *Br J Radiol* 2003; 76: 137-43.
3. Park SJ, Kim JD, Seo YS, Park BJ, Kim MJ, Um SH, et al. Computed tomography findings for predicting severe acute hepatitis with prolonged cholestasis. *World J Gastroenterol* 2013; 19: 2543-9.
4. Maresca G, De Gaetano AM, Mirk P, Cauda R, Federico G, Colagrande C. Sonographic patterns of the gallbladder in acute viral hepatitis. *J Clin Ultrasound* 1984; 12: 141-6.
5. van Breda Vriesman AC, Engelbrecht MR, Smithuis RH, Puylaert JB. Diffuse gallbladder wall thickening: differential diagnosis. *AJR Am J Roentgenol* 2007; 188: 495-501.
6. Kim MY, Baik SK, Choi YJ, Park DH, Kim HS, Lee DK, et al. Endoscopic sonographic evaluation of the thickened gallbladder wall in patients with acute hepatitis. *J Clin Ultrasound* 2003; 31: 245-9.
7. Suk KT, Kim CH, Baik SK, Kim MY, Park DH, Kim KH, et al. Gallbladder wall thickening in patients with acute hepatitis. *J Clin Ultrasound* 2009; 37: 144-8.
8. Black MM, Mann NP. Gangrenous cholecystitis due to hepatitis A infection. *J Trop Med Hyg* 1992; 95: 73-4.
9. Kaya S, Eskazan AE, Ay N, Baysal B, Bahadir MV, Onur A, et al. Acute acalculous cholecystitis due to viral hepatitis A. *Case Rep Infect Dis* 2013; 2013: 407182.
10. Casha P, Rifflet H, Renou C, Bulgare JC, Fieschi JB. Acalculous acute cholecystitis and viral hepatitis A. *Gastroenterol ClinBiol* 2000; 24: 591-2.
11. Portincasa P, Moschetta A, Di Ciaula A, Palmieri VO, Milella M, Pastore G, et al. Changes of gallbladder and gastric dynamics in patients with acute hepatitis A. *Eur J Clin Invest* 2001; 31: 617-22.