

Management of Cardiac Myxoma; Tertiary Academic Center Experience

Saygin Turkyilmaz¹, Ali Aycan Kavala¹

¹Bakırköy Dr. Sadi Konuk Training and Research Hospital, Department of Cardiovascular Surgery, Istanbul, Turkey

ABSTRACT

Aim: In this study, our clinical experience on cardiac myxoma, being the most frequently seen primary cardiac tumor is presented.

Material and Methods: In the present study, demographic data, presenting symptoms, clinical findings and when deemed necessary, coronary angiography results of 45 primary cardiac myxoma patients who were diagnosed, and operated between November 2010 and July 2016, were evaluated.

Results: Of 45 included cases, 34 (75.6%) had left atrial, the remaining 11 (24.4%) had right atrial myxoma. Postoperative echocardiography was performed with no residual myxoma or recurrence.

Conclusion: Since presenting symptoms are often nonspecific, high degree of clinical suspicion is necessary to diagnose cardiac tumors. The mainstays of current treatment strategy are surgical intervention with complete resection of tumor mass without any complications, and prevention of recurrence.

Keywords: Myxoma, heart neoplasms, cardiac surgery

ÖZ

Kardiyak miksomaya tedavisi; üçüncü basamak akademik merkez deneyimi

Amaç: Bu çalışmada, en sık görülen primer kalp tümörü olan miksomaların klinik özellikleri ve cerrahi deneyimlerimiz paylaşıldı.

Gereç ve Yöntem: Kasım 2010-Temmuz 2016 tarihleri arasında 45 primer kardiyak miksomaya hastasına tanı konularak opere edildi. Bu hastaların demografik özellikleri, semptomları, klinik bulguları, ekokardiyografi ve gerekli olanlara uygulanan koroner anjiyografi bulguları değerlendirildi.

Bulgular: Toplam 45 hastanın 34 tanesinde (%75.6) sol atriyum 11 tanesinde (%24.4) sağ atriyum kaynaklı miksomaya tespit edildi. Postoperatif dönemde hastaların ekokardiyografi kontrollerinde rezidü ve rekürrens rastlanmadı.

Sonuç: Klinik bulguları nonspesifik olduğu için başlangıçta kardiyak tümörlerin akla getirilmesi çok önemlidir. Tek tedavi seçeneği cerrahi olup, komplikasyon gelişmeden cerrahinin planlanması ve tümörün tam rezeksiyon edilerek rekürrensin önlenmesi çok önemlidir.

Anahtar kelimeler: Miksoma, kalp neoplazileri, kalp cerrahisi

Geliş tarihi/Received: 30.12.2017 Kabul tarihi/Accepted: 17.01.2018



Yazışma Adresi/Address for Correspondence: Saygin Turkyilmaz, Bakırköy Dr. Sadi Konuk Training and Research Hospital, Department of Cardiovascular Surgery, Istanbul, Turkey **Telefon/Phone:** +90-505-255-7993 **E-posta/E-mail:** sygnty@hotmail.com

Atıf/Citation: Turkyilmaz S, Kavala AA. Management of cardiac myxoma; tertiary academic center experience. Bakırköy Tıp Dergisi 2018;14:98-103. <https://doi.org/10.5350/BTDMJB.20171230024937>

INTRODUCTION

Though cardiac tumors are rarely seen, they are pathologies causing high rate of mortality and morbidity when they are complicated. Primary cardiac tumors are rarely seen and 80% of them benign and more than half of them myxoma. Myxoma account for 5-10% of all cardiac and pericardial tumors (1). They are often seen on the left side of the heart (75%) left atrial and some are seen in right cardiac cavity (18%). The tumors on the right side are generally diagnosed while searching for pulmonary embolism that have recurred and have not been diagnosed for a long time. In embolic pathologies possibility of intracardiac tumor should be taken into consideration (2). Left atrial myxoma can be confused with mitral stenosis and left atrial thrombus (3). And also, right atrial myxoma can be confused with tricuspid valvular heart disease. Cardiac myxoma is more common in women. They can be diagnosed at any age however, they are often diagnosed during the 3rd and 6th decades of life (4-8). Myxomas constitute only 15% of benign cardiac tumors in children (5). They are rare during infancy (5-7). Echocardiography and cardiopulmonary bypass dramatically changed prognosis of cardiac myxoma. Transesophageal echocardiography also supplies significant information on the characteristics and scanning of tumors (9).

The aim of our study was to convey our approach to myxoma cases, patient follow-up and early and late period findings and compare them with the literature.

MATERIAL AND METHOD

In our centre, 45 primary cardiac myxoma patients were operated between November 2010 and July 2016, and 32 of them were females (71.1%) and 13 patients were males (28.9%). Their average age was 45.3 (range, 15-73) years. Their symptoms in the pre-operation period were as follows; shortness of breath in 31 patients (68.8%), palpitation in 16 patients (35.5%), confusion weakness in arms and legs in 3 patients (6.6%), peripheral embolism in 4 patients (8.8%).

The age and clinic features of patients are shown in (Table 1).

In pre-operation diagnostic echocardiography was used in all patients (Figure1). In the cases over age of 45 years,

Table 1: The age and clinic features of patients

Number of Patients	45
Male/Female	13/32
Mean Age	15-73 (45.3)
Preoperative Symptom	
Shortness of Breath	31 (68.8%)
Palpitation	16 (35.5%)
Confusion Weakness	3 (6.6%)
Peripheral Embolism	4 (8.8%)
Preoperative Rhythm	
Sinus	43 (95.5%)
Atrial Fibrillation	2 (4.5%)
Localization	
Right Atrium	11 (24.4%)
Left Atrium	34 (75.6%)

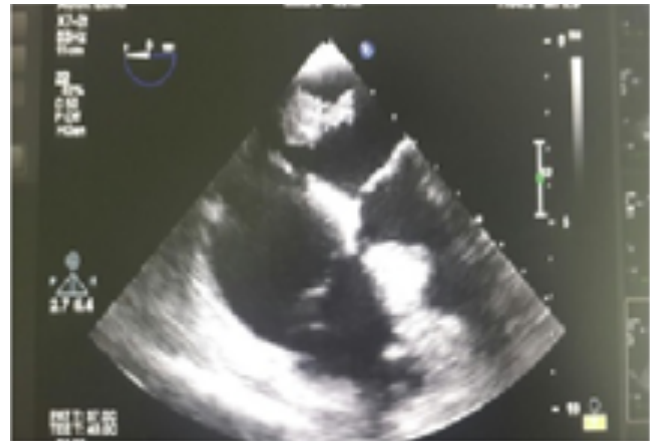

Figure 1: Echocardiographic imagine of myxoma

cardiac angiography was done and myxoma surgery with simultaneous coroner artery surgery was decided in 2 cases (6.6%). There was no specific characteristic in family history. During physical examination, to define myxoma location, generally auscultation findings due to mitral stenosis were indicated left atrial myxoma, whereas findings of right cardiac insufficiency indicated right atrial myxoma.

Of study population, 43 patients (95.5%) had sinus rhythm, and 2 patients (4.5%) had atrial fibrillation during the pre-operation period. Increased vascularity was determined in lungs in 9 patients (30%) in telecardiography.

Surgery Techniques

Patients with definite diagnosis were immediately taken to operation. Median sternotomy was performed under general anesthesia. After aortic and bicaval cannulation,

cardiopulmonary bypass was started. The patients were provided with cardiac arrest by applying antegrad cardioplegia with hypothermia at the middle level. Localization of myxoma was in left atrial in 34 (75.6%) cases, and in right atrial in 11 (24.4%) cases. The right atriotomy was performed on all cases.

In 2 cases with myxoma in the right atrium, 2*2cm myxomatous mass was excised on tricuspid valve and taken out without any damage to the tricuspid valve. The right atriotomy was closed, and cardiopulmonary bypass was completed. In all off the 34 cases with myxoma in left atrium, the left atrium was reached through transseptal approach by opening the right atrium. In a total of 10 cases with myxoma in the left atrium myxoma mass was excised with its stem holding on interarterial septum.

Interatrial septum was closed with 4/0 prolene and the right atrium was primarily closed with 5/0 prolene. In a total of 2 cases with myxoma in interatrial septum, coronary artery disease was also diagnosed. Therefore, in two cases Lima-LAD, Ao-Om1, Ao -RCA bypass were performed, and cardiopulmonary bypass was completed.

RESULTS

In all cases, the mass was pathologically studied after the operation. The measures of tumors were between minimum 2*2 cm and maximum 4*6.2 cm (Figure 2). The structure of the tumors was seen as a colloid substance within thick pedicules and lobules. Neither intraoperative nor postoperative hospital mortality was experienced in the

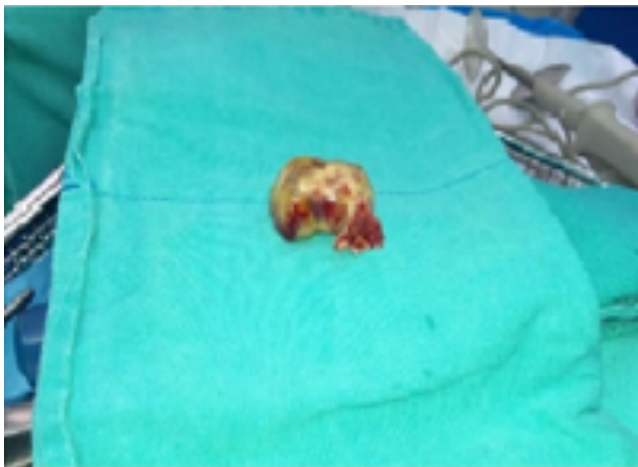


Figure 2: Measures of tumor

early period. Postoperative first month, 6. month and the first year control echocardiography was used in all patients. Residue or recurrence was not seen in any patient.

DISCUSSION

Cardiac myxoma is a type of neoplasia with unknown etiology, but it is thought to originate from primitive mesenchymal cells. Myxoma is histopathologically made up of polygonal myxoma cells embedded in a mucoid substance which is rich in glycosaminoglycan. Myxoma is an intracavitary tumor with 5-6 cm in diameter. Generally, it has a polypoid structure with a stem and spreads in its surroundings. The stem may have a large base. It may be papillary or have a smooth base. It may be gelatinoid and include some bleeding sites. Though it can be seen in all cardiac cavities, it is more commonly observed in atriums, especially in the left atrium. Papillary ones may fragmentize and lead to embolies. Echocardiography is generally sufficient for diagnosis. Developing tumors, almost 5% of myxoma carry the pattern of autosomal dominant inheritance. While the pattern of DNA is normal in 80% of the patients with non-familial sporadic myxoma, it is abnormal in 20% of the patients with familial myxoma. Familial myxoma is seen at younger ages, unlike sporadic myxoma. familial myxoma is multisentric tumors and has an equal in sexual rate. Higher recurrence rates have been reported in patients with familial myxoma cases after surgical resection (between 21% and %67) (10-13). None of our cases had a family story. Myxoma is an intracavitary tumor. Left atrial myxoma is seen most frequently (75%). The frequencies of right and left ventricular myxomas are equal (6.8%) (5). Right ventricular myxoma originates from free wall and left ventricular myxoma originates from posterior papillary muscle (14,15). Left ventricular myxoma is accompanied by hemodynamical disorders (arrhythmia, valve insufficiency, intracavitary obstruction causing damage to the valves; congestive heart failure, fainting or sudden death) systemic embolization (64%) or rarely some structural impacts such as weakness and fatigue. Right ventricular myxoma are risk of pulmonary artery mycotic emboli during operation and require simultaneous pulmonary embolectomy.

Yilman and his colleagues reported that tumor was in the

left atrial in 3 myxoma cases they operated, on the left of interatrial septum in 2 cases and it originated from posterior valvular of mitral valve in 1 case (16). Kaplan and his colleagues (3) pointed out in a series of 45 cases they published that 32 cases originated from the left atrium. Similary Keceligil and his colleagues reported in a series of 8 cases that 7 cases originated from the left atrium (17).

Similar to previous studies, we determined that 34 cases originated from the left atrium (75.6%) in our series of 45 cases.

Cardiac myxoma is often seen in women during the 3rd and 6th decades of their lives (5). The results of our study are compatible to this fact.

Hemodynamical disorders, embolies and non-specific symptoms, such as fever and fatigue can be seen in myxoma. Left atrial myxoma may show some symptoms, such as dyspnea and hemoptysis like mitral stenosis symptoms. Syncope attacks, fast developing congestive heart failure may develop. In right atrial myxoma, hepatomegaly, ascites and peripheral edema may be observed. Neurological findings depending on cerebral embolies (10), extremity ischemia depending on peripheral embolism, angina depending on coronary embolism, dyspnea depending on pulmonary embolism may also be seen. The symptom which is seen mostly in patients with atrial myxoma is breathing difficulty depending on obstruction. Although the most common preoperative symptom among our patients was breathing difficulty; in a series of 20 cases by Suzer and his colleagues (18) congestive heart failure was remarkably the most common symptom. In preoperative clinic profiles of our cases our neurological system findings were confusion and weakness in arms in one patient. However, in literature, Oto and his colleagues (19) reported stroke symptoms in 7 patients with cardiac myxoma who were treated at the hospital. In a series of 7 cases treated by Bozoglan and his colleagues (20) the most common symptom was shortness of breath and palpitation. Likewise, in a series of 45 cases treated by Kaplan and his colleagues the most common symptom was published as respiratory distress (3).

One of major symptoms of cardiac myxoma is embolization. Systematic embolus is observed in 30-40% of left atrial myxoma cases (21). Emboli episodes affect central nervous system by making 50% intracranial and extracranial vascular obstruction (5,21). Bartolotti and his colleagues (22)

pointed out that they encountered 24% embolic episode in left atrial myxoma cases, and this was first symptom of tumor in 10 patients out of 13. In tumors located in right cavities of heart, 10% embolism was observed, and massive fatal pulmonary obstruction might occur. In our series, peripheral embolism (right femoral artery embolism) was encountered in only one case (6.6%).

In diagnosis of cardiac myxoma echocardiography is the most suitable and efficient method (4-6,21). Especially trans-esophageal echocardiography is superior as it gives information about the size of the tumor, its location, its mobility and the way it is attached (5). Unless there is a cardiac or coronary artery disease, catheterization and angiocardigraphy are not the methods to be used in diagnosis (14). On the contrary, it is advisable to avoid invasive procedures because of danger in fragmentation of tumor (4). Although computerized tomography can be used in diagnosis of myxoma, this option is more advisable to evaluate malign tumors of heart (5). Magnetic resonance can be used in diagnosis of myxoma and determining the size and shape of tumors and its structural characteristics (5,6). We also used transesophageal echocardiography in all of our cases.

In treatment of myxoma, surgical resection is the only and eligible method (5,6,22). After diagnosing with echocardiography, immediate surgical intervention should be performed (6,22).

Symbas and his colleagues (23) stated that there was a high mortality rate due to massive embolization and fatal obstruction of intracardiac blood passage during time duration between diagnosis and surgical intervention. In our cases, the time duration between diagnosis and surgical operation was 4 days in average (range, 3-7 days). In myxoma, surgical operations are made by using cardiopulmonary bypass with median sternotomy (6). The basic principles of surgical operation are as follows; avoid manipulation of heart not to cause embolization during removing the tumor, avoid manipulation of cardiac wall to which the tumor is attached or interatrial septum in full thickness while removing the tumor so as not to segment it, and to inspection all cardiac cavities and all cardiac valves (5,6).

After removal, the defect on cardiac wall or septum is repaired by a patch or primer stitching (24). Left atrial myxoma can be taken out by left atrial incision, by right

atrial incision, and with approach by reaching left atrium or with biatrial incision (5). Biatrial approach is more suitable for removal of tumors, especially of large diameters (5,6). As well as taking out the tumor, if necessary, valve surgery should be performed (25). For right ventricular myxoma right atriotomy is advisable in order to be valued with right ventriculotomy or tricuspid valve passage (6,21). In ventricular myxoma, ventricular wall does not need to be removed along with complete floor of tumor. Less radical subtraction is enough (5,6,21). We preferred biatrial incision in all left atrial myxoma cases (totally 26 cases) and right atrial incision in right atrial myxoma cases (total 4 cases). In left atrial myxoma cases, we removed the tumor with endocardial part to which it was attached in full thickness without any segmentation. In cardiac myxoma, the result of surgical resection were quite good. Operative mortality was below 5% (6,21). It was informed that excision of ventricular myxoma had a slightly higher risk (10%). However, experiences are limited (5). In a series, hospital mortality was reported as 0%. In non- familial sporadic myxoma, recurrence was nearly 1% and 4.70% (5) or below 5% (6). In contrast, high recurrence rate was reported such as 6.30% (4), 22.5% (5), 30%-75% in symptoms of complex myxoma (21). Our patients were followed up for 12 months. No recurrence was noted in echocardiography controls.

The rate of recurrence is 2-3%, and it happens depending on four reasons. These are insufficient resection, tumor at multiple centers, familial type and metastatic recurrence. A

large resection of tumor with its stem is necessary. In the literature, recurrence of left ventricular myxoma has been reported after left atrial myxoma resection. It is controversial whether recurrence results from the segmentation and spreading of pieces of tumor in ventricular and its attachment to ventricular structure or from the multifocal disease. Sometimes recurrent myxoma is seen in peripheral vascular bed with fragments of tumor going to periphery (26).

In conclusion, as its clinical findings are non-specific, considering cardiac tumor in the beginning is extremely important. Myxomas have similar characteristics to benign tumors. In surgery, complete resection of tumor and controlling all chambers are also vitally important to prevent recurrence. Transesophageal echocardiography should be the first option in diagnosis as well as first preference in the follow-up. And patients should also be examined in 6 month intervals for detection of recurrence by echocardiography.

Ethics Committee Approval: Ethics committee approval was received for this study from the local ethics committee.

Informed Consent: Informed consent was obtained.

Author contributions: Development of study - S.T.; Methodological design of the study - S.T.; Data acquisition and process - A.A.K.; Data analysis and interpretation - A.A.K.; Literature review - S.T.; Manuscript writing - S.T.; Manuscript review and revision - A.A.K.

Conflict of Interest: Authors declared no conflict of interest.

Financial Disclosure: Authors declared no financial support.

REFERENCES

- Bhan A, Mehrotra R, Choudhary SK, et al. Surgical experience with intracardiac myxomas: long-term follow-up. *Ann Thorac Surg* 1998;66(1):810. [CrossRef]
- McCoskey EH, Mehta JB, Krishnan K, Roy TM. Right atrial myxoma with extracardiac manifestations. *Chest* 2000;118:547-9. [CrossRef]
- Kaplan M, Demirtaş MM, Çimen S, Gerçekoğlu H, Yapıcı F, Özler A. Cardiac Myxomas: surgical experience with 45 Cases. *Turkish Journal of Thoracic and Cardiovascular Surgery* 2002;10:11-4.
- Parry AJ, Pillaj R. Miscellaneous cardiac disease. In: Morris PJ, Malt RA (ed). *Oxford Textbook of Surgery*, Oxford, Oxford University Press, Vol 2, 1994; 1848-54.
- Hall RA, Anderson RP. Cardiac neoplasms. In: Edmunds LH Jr (ed). *Cardiac Surgery in the Adult*, New York, The McGraw-Hill Companies, 1997; 1345-62.
- Giuliani ER, Pieher JM. Cardiac neoplasms. In: Catterjee K, Karliner J, Rapaport E, Cheitlin MD, Parmley WW, Scheinman M (eds). *Cardiology*, Philadelphia, J. B. Lippincott Company, Vol 2, 1991; 12.45-12.54.
- Becker AE, Losekoot TG. Cardiac tumours. In: Anderson RH, Macartney FJ, Shinebourne EA, Tynan M. *Paediatric Cardiology*, Edinburgh, Churchill Livingstone, Vol 2, 1987; 1153-61.
- Lucacs L, Lengyel M, Szedő F, et al. Surgical treatment of cardiac myxomas: a 20-year follow-up. *Cardiovascular Surgery* 1997;5(2): 225-8. [CrossRef]
- Roldán FJ, Vargas-Barrón J, Espinola-Zavaleta N, Keirns C, Romero-Cárdenas A. Recurrent myxoma implanted in the left atrial appendage. *Echocardiography* 2000;17:169-71. [CrossRef]
- Lee VH, Connolly HM, Brown RD Jr. Central nervous system manifestations of cardiac myxoma. *Arch Neurol* Aug 2007;64(8):1115-20. [CrossRef]

11. Gelder HM, Oi Brian DJ, Styles ED, Alexander JA. Familial cardiac myxoma. *Ann Thorac Surg* 1992;53:419-24. [\[CrossRef\]](#)
12. Prichard RW. Tumors of the heart: Review of the subject and report of one hundred and fifty cases. *Arch pathol* 1951;51:98-104.
13. Wold LE, Lie JT. Cardiac myxomas: A clinicopathologic profile. *Am J Pathol* 1980;101:219-22.
14. Talwalkar N, Livesay JJ, Treistman B, Lacle CE. Mobilization of the anterior mitral leaflet for excision of a left ventricular myxoma. *Ann Thorac Surg* 1999;67:1476-8. [\[CrossRef\]](#)
15. Selvaraj A, Kumar R, Ravikumar E. Surgical management of right atrial myxomas. A 15 year experience with review of the literature. *J Cardiovasc Surg (Torino)* 1999;40:101-5.
16. Yılman M, Kolbakır F, Keçeligil HT, Geyik T, Erk MK. Mitral anulustan orijin alan miksoma. *Türk Göğüs Kalp Damar Cer Derg* 1994;2:159-61.
17. Keçeligil T, Demir Z, Kolbakır F, Demirbağ K, Akar H. Kardiyak miksoma ve cerrahi tedavisi. *GKDC Dergisi* 1999;7:210-6.
18. Süzer K, Aytaç A, Akçevin A ve ark. Cerrahi açıdan kalp tümörleri: 20 vakaya ait deneyim ve gözden geçiri. *Türk Kardiyol Dern Arş* 1990;18:56-62.
19. Oto Ö, Okutan H, Kutluk K ve ark. Strok ve miksoma. *Türk Göğüs Kalp Damar Cer Derg* 1998;6:493-7.
20. Bozoğlan O, Erdem K, Güneş T, Gül A, Yılmaz Y, Erdogan H. Kardiyak miksomalara ve cerrahi tedavi. *Abant İzzet Baysal Tıp Fakültesi Dergisi* 2012;7(1-2-3).
21. Kirklin JW, Barratt-Boyes. Cardiac tumor. In: Kirklin JW, Barratt-Boyes BG. *Cardiac Surgery*, 2nd edition, New York, Churchill Livingstone, Vol 2, 1993; 1635-1654.
22. Bortolotti U, Maraglino G, Rubino M, et al. Surgical excision of intracardiac myxomas: A 20 year follow-up. *Ann Thorac Surg* 1990;49:449-53. [\[CrossRef\]](#)
23. Symbas PN, Hatcher CR, Gravanis MB. Myxoma of the heart: Clinical and experimental observations. *Ann Surg* 1976;183:470-4. [\[CrossRef\]](#)
24. Eralp A, Kutsal A, İbrişim E, Şener E, Babacak K, Bayazıt K. Atrial miksoma ve cerrahi tedavisi. *Ankara Tıp Mecmuası* 1989;42:535-44.
25. Aydoğan H, Akay MH, Orhan G ve ark. Miksomaların cerrahi tedavisi. *HKK Cerrah Bül* 1999;7:34-7.
26. Shinfeld A, Katsumata T, Westaby S. Recurrent cardiac myxoma: seeding or multifocal disease? *Ann Thorac Surg* 1998;66:285-8. [\[CrossRef\]](#)