

A Pathological Process Should be Carefully Conducted in the Breast: Mucocele-Like Lesion

Zühal GÜCİN 

Department of Pathology, Bezmalem Vakif University School of Medicine, İstanbul, Turkey

ABSTRACT

Mucocele-like lesion (MLL) of the breast has been firstly described as a benign lesion resembling mucinous carcinoma of the breast. Subsequently, it has also been reported to be associated with ductal hyperplasia or breast carcinoma. The risk of cancer development in the long term is unknown. Therefore, the approach to pure MLL of the breast detected during percutaneous biopsy is controversial. In this report, a mucocele-like breast lesion in a 47-year-old woman was first noticed during a core biopsy and later detected to be associated with ductal carcinoma in-situ focuses in excisional biopsy material is presented. The aim of this paper was to provide an overview of this rare and controversial lesion and its variabilities with regard of the presented case.

Keywords: Mucocele-like lesion, mucin, breast

Introduction

Mucocell-like lesion of the breast MLL was described in 1986 by Rosen as a benign lesion that is histologically similar to the mucinous carcinoma of the breast and that contains extravasated mucin (1). It was also been reported to be associated with ductal hyperplasia or carcinoma afterwards (2-4).

Some unusual lesions may cause problems for pathologists in core biopsy. Mucocele-like lesions (MLL), spindle-celled metaplastic carcinomas, adenomyoepithelioma, pseudoangiomatous stromal hyperplasia (PASH), collagenous spherulosis, myofibroblastoma, vascular lesions, lymphoid infiltrates can be listed in this type of lesions that cause confusion in breast pathology (5).

Cancer risk is not known for MLL in long-term follow-up (6). Therefore, the approach to pure mucosel-like lesions diagnosed with percutaneous breast biopsy is controversial (7).

Case Presentation

A 47-year-old female patient was admitted to our hospital with the diagnosis of mucocele-like lesion and atypical hyperplasia after a tru-cut biopsy that had been performed at an external center due to a recurrent mass in the left breast. The patient had undergone excision on the same breast, had been diagnosed with atypical ductal hyperplasia 3 years ago and had been followed up. On physical examination, nodular areas with a diameter of 0.5 cm were detected on the areola edge of the left breast at 12 o'clock position and at a distance of 2 cm to the areola. In the imaging reports performed at the external center, at the 12 o'clock position of the left breast an area that contained 13 mm heterogeneous microcalcification at a distance of 2 cm to the nipple had been described. The lesion marked with wire was excised. Macroscopically, in the central part of the excision material, mass lesion of 1.6x1.2x0.8 cm with partially lobulated edging and bright gelatinous appearance with small cystic structures was observed (Figure 1). Microscopic examination revealed intermediate grade insitu ductal carcinoma areas in flat, micropapillary and solid pattern. In these structures, both prevalent intraluminal and the mucosel-like extracellular mucinous material were remarkable (Figure 2). Atypical ductal hyperplasia and atypical lobular hyperplasia were detected outside the lesion area. It was learned that the patient who was living outside of İstanbul had mastectomy at an external center but information about the result could not be obtained.

Cite this article as: Gücin Z. A Pathological Process Should be Carefully Conducted in the Breast: Mucocele-Like Lesion. *Bezmalem Science* 2018; 6: 147-9.

Address for Correspondence: Zühal GÜCİN, Department of Pathology, Bezmalem Vakif University School of Medicine, İstanbul, Turkey E-mail: zgucin@bezmalem.edu.tr

Received: 15.08.2016
Accepted: 16.01.2017

©Copyright 2018 by Bezmalem Vakif University - Available online at www.bezmalemscience.org

Discussion

When a cyst containing mucin in the breast is ruptured, the secreta and epithelium inside may spread into the surrounding tissue. This creates a benign lesion that is similar to the so-called mucocele of the minor salivary glands and very little is known about this type of lesion (1). Its histology connotates mucinous carcinoma. The abundance of mucin content and occasional epithelial structures observed during aspiration biopsy may make it difficult to differentiate from mucinous carcinoma (1, 4, 8). Mucocele-like lesions should be kept in mind in the differential diagnosis especially among young premenopausal women in whom mucinous carcinoma is rare (1).

The most important finding of mammography has been reported as microcalcifications (clustered round calcifications)

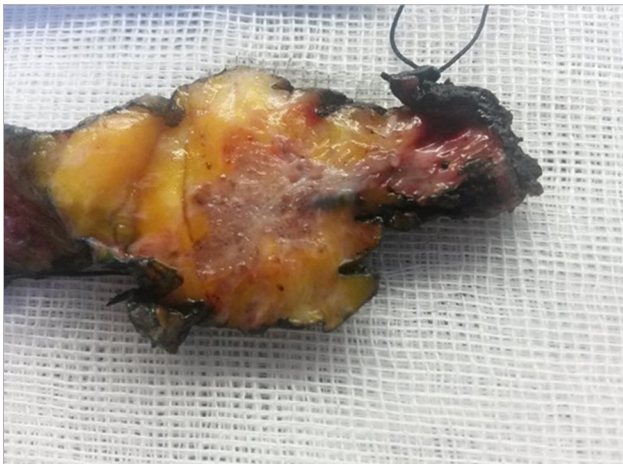

Figure 1. Macroscopic view of the mass. Lesion area with partially lobular margin, mucinous bright surface and small cystic structures

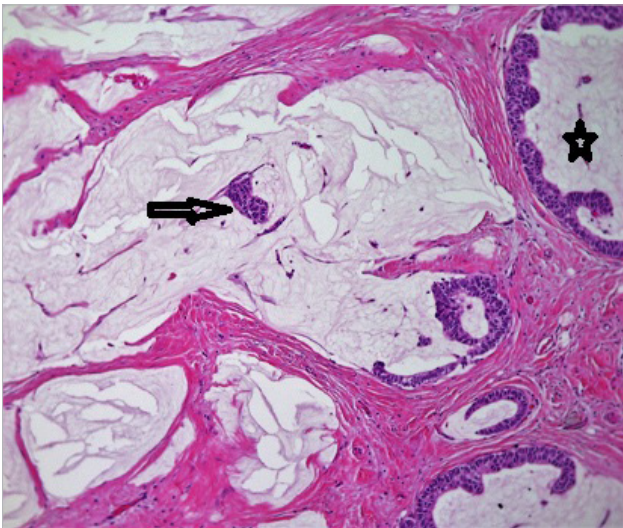


Figure 2. Ductal carcinoma insitu focus (star) in micropapillary form on the upper right, neoplastic epithelial cells floating in extravasated mucin and mucin lakes in large area (arrow)

(7, 9, 10). The presented case was also described as a lesion with microcalcification in imaging.

In the literature, it is seen that the core / needle biopsy and excision biopsy series performed with the help of imaging in long-term periods were reexamined and the MLL ratios and their follow-up results were reviewed (6-10). Meares et al. (6) detected 102 MLL cases (0.7%) in 13,412 breast biopsies performed between 1967 and 2001. The incidence of atypical hyperplasia in MLL cases was 27% and MLL was frequently interpreted as a rare breast lesion with atypical hyperplasia. It was reported that breast carcinoma had developed in 13 patients during their follow-up periods (6). In another study, 21,340 breast biopsies performed between 1997 and 2010 were reviewed and 51 MLL patients were detected (0.23%). Thirty-five patients underwent surgery after percutaneous biopsy and 33 of them had benign results, and 2 (5.7%) of them were diagnosed with ductal carcinoma insitu (DCIS) (7). Pure mucocele-like lesion is a rare condition and is usually well progressed (7); the incidence of DCIS in patients undergoing excision is 5.7% (7). In a similar study, when the core biopsies applied to 18,111 patients between 2003 and 2013 were reviewed, 32 MLL cases were determined (0.17%). While twenty-seven subjects were pure MLL; in 5 cases, lesions such as breast carcinoma / atypical hyperplasia / papillary lesion / lobular carcinoma insitu (LCIS) / radial scar were observed (9). In another series, 9,286 cases were retrospectively reviewed and MLL was found in 35 cases (0.38%) (10). Considering the large patient series given above, the incidence of MLL in core / excision biopsies is between 0.17% and 0.7%. Even though MLL is mostly in the form of pure lesions, it may be accompanied by further results such as proliferative lesions, atypical hyperplasia, ductal carcinoma in situ in up to 1/4-1/3 cases. In the presented case, atypical ductal and atypical lobular hyperplasia and ductal carcinoma insitu areas were also present.

Mucocele-like lesions are rare breast pathologies. Surgical intervention is recommended if there are any signs of atypical findings associated with mucocele-like structures in core biopsy. In the surgical excision, it is sufficient to follow with short intervals if there is no change except for atypical hyperplasia in surgical excision (10). In the presented case, mucocele-like extracellular mucin presence and concomitant atypical ductal hyperplasia areas were noted after core biopsy. In the large local excision, ductal carcinoma insitu areas were detected.

Conclusion

The mucocele-like lesion (MLL) of the breast has a wide diagnostic spectrum that is characterized by the presence of abundant extravasated mucin but can contain different pathologies. Therefore, the cases detected in core biopsy should be excised and re-evaluated.

Informed Consent: Written informed consent was obtained from patient who participated in this study.

Peer-review: Externally peer-reviewed.

Conflict of Interest: The authors have no conflict of interest to declare.

Financial Disclosure: The author declared that this study has received no financial support.

References

1. Rosen PP. Mucocele-like tumors of the breast. *Am J Surg Pathol* 1986; 10: 464-9. [\[CrossRef\]](#)
2. Hamele-Bena D, Cranor ML, Rosen PP. Mammary mucocele-like lesions: Benign and malignant. *Am J Surg Pathol* 1996; 20: 1081-5. [\[CrossRef\]](#)
3. Kikuchi S, Nishimura R, Osako T, Okumura Y, Hayashi M, Toyozumi Y, et al. Mucocele-like tumor associated with ductal carcinoma in situ diagnosed as mucinous carcinoma by fine-needle aspiration cytology: report of a case. *Surg Today* 2012; 42: 280-4. [\[CrossRef\]](#)
4. Schnitt F, Sneige N, Lee A. Classification using needle-core biopsy and fine-needle aspiration. In: Lakhani SR, Ellis IO, Schnitt SS, Tan PH, van de Vijver MJ(eds). *WHO Classification of Tumours of the Breast*. 4th ed. Lyon, IARC, 2012: 26-7.
5. Hoda SA, Rosen PP. Observations on the pathologic diagnosis of selected unusual lesions in needle core biopsies of breast. *Breast J* 2004; 10: 522-7. [\[CrossRef\]](#)
6. Meares AL, Frank RD, Degnim AC, Vierkant RA, Frost MH, Hartmann LC, et al. Mucocele-like lesions of the breast: a clinical outcome and histologic analysis of 102 cases. *Hum Pathol* 2016; 49: 33-8. [\[CrossRef\]](#)
7. Diorio C, Provencher L, Morin J, Desbiens C, Poirier B, Poirier É, et al. Is there an Upgrading to Malignancy at Surgery of Mucocele-Like Lesions Diagnosed on Percutaneous Breast Biopsy? *Breast J* 2016; 22: 173-9. [\[CrossRef\]](#)
8. Bhargava V, Miller TR, Cohen MB. Mucocele-like tumors of the breast. Cytologic findings in two cases. *Am J Clin Pathol* 1991; 95: 875-7. [\[CrossRef\]](#)
9. Park YJ, Kim EK. A pure mucocele-like lesion of the breast diagnosed on ultrasonography-guided core-needle biopsy: is imaging follow-up sufficient? *Ultrasonography* 2015; 34: 133-8. [\[CrossRef\]](#)
10. Ha D, Dialani V, Mehta TS, Keefe W, Iuanow E, Slanetz PJ. Mucocele-like lesions in the breast diagnosed with percutaneous biopsy: is surgical excision necessary? *AJR Am J Roentgenol* 2015; 204: 204-10. [\[CrossRef\]](#)