

Case Report: Mediastinal Hydatid Cysts

Mehmet Oğuzhan ÖZYURTKAN, Semih KOÇYİĞİT, Muharrem ÇAKMAK,
İbrahim Ethem ÖZSOY, Akın Eraslan BALCI

Fırat Üniversitesi Tıp Fakültesi, Göğüs Cerrahisi Anabilim Dalı, Elazığ, Türkiye

SUMMARY: Although the intrathoracic location is common for hydatid cyst, chest-wall, mediastinal, pericardial, myocardial, fissural and pleural-space locations have been reported. The incidence of mediastinal involvement is 0.1-0.5%. Here in this paper, two cases of mediastinal hydatid cysts are reported. Both of them had anterior mediastinal hydatidosis, while one of the patients had also additional three pericardial hydatid cysts. They have undergone thoracotomy for the removal of cystic lesions. Hydatid cysts should be considered in the differential diagnosis of mediastinal cystic lesions especially in the endemic regions. Surgical removal is the treatment of choice for mediastinal hydatid cysts, and additional medical therapy may avoid recurrence.

KeyWords: Hydatid cyst, Mediastinum, Thoracotomy

Olgu Sunumu: Mediyastinal Kist Hidatik

ÖZET: Kist hidatidin intratorasik tutulumu beklenen bir durum olmakla birlikte, göğüs duvarı, mediyasten, perikard, miyokard, fissür ve plevral boşluk tutulumları nadir olarak bildirilmektedir. Mediyasten tutulum oranı %0.1-0.5'tir. Bu yazıda iki adet mediyastinal kist hidatik vakası sunulmuştur. Her iki hastada ön mediyastinal tutulum, birinde ek olarak perikardiyal tutulum mevcuttu. Kistlerin hepsi torakotomi ile çıkarılmıştır. Özellikle endemik bölgelerde, mediyastinal kistik lezyonların ayırıcı tanısında kist hidatik akla gelmelidir. Cerrahi önerilen bir tedavi metodudur ve ilave medikal tedavi rekürrens olasılığını azaltmaktadır.

Anahtar Sözcükler: Hidatik kist, Mediyasten, Torakotomi

INTRODUCTION

Human Hydatid disease caused by the larval form of *Echinococcus granulosus* is endemic to many parts of the world, particularly the Mediterranean countries including Turkey, the Middle East, South America, Africa, New Zealand, Russian Federation, Central Asia, and Australia (1). The disease is encountered mostly in the Central Anatolian and Aegean regions of Turkey with an incidence of 6.3/100000 (2). The liver and the lungs are the most commonly affected areas in adults (1). Extrapulmonary location of the disease in the thorax is very rare. Intrathoracic extrapulmonary locations are generally the mediastinum, pleura, pericardium and chest wall (3). We report two cases of mediastinal hydatid cysts in this paper.

CASE REPORTS

Case 1: A 34-year-old man was admitted to our clinic with a complaint of coughing. There was no history of any disease, but he frequently came into contact with carnivores, and sheep.

Makale türü/Article type: **Olgu Sunumu / Case Report**

Geliş tarihi/Submission date: 22 Eylül/22 September 2008

Düzeltilme tarihi/Revision date: 23 Ocak/23 January 2009

Kabul tarihi/Accepted date: 24 Ocak/24 January 2009

Yazışma /Corresponding Author: M. Oğuzhan Özyurtkan

Tel: (90) (424) 233 35 55 Fax: -

E-mail: moozyurtkan@hotmail.com

Laboratory tests were normal except for mild leucocytosis and eosinophilia. His physical examination was normal. Computed tomography (CT) scan of the thorax showed multiple cystic lesions at anterior mediastinum (Figure 1), and three cystic lesions at the left pericardium (Figure 2). Abdominal ultrasonography revealed a normal liver, but multiple cysts at the upper pole of the spleen. A preoperative diagnosis of mediastinal, pericardial, and splenic hydatid cyst was made. A left anterolateral thoracotomy was performed. In thoracotomy, multiple cystic lesions located at the anterior mediastinum, and three cystic lesions located at the parietal pericardium were removed. No intraparenchymal cysts were found in this patient, there were no complications in the postoperative period and he was discharged 7 days after the operation. He was told to admit to the General Surgery department after a month for his splenic cystic lesions. The antihelminthic therapy (10 mg/kg albendazole) was administered daily for a month postoperatively. There was no recurrence of the disease during a follow-up of one month.

Case 2: A 60-year-old man was admitted to our clinic with complaints of mild chest pain for the past 3 months. Pain was constant and started at the left parasternal area radiating to the left lateral side of the chest. There was no history of trauma, fever, syncope, dyspnoea on exertion, or contact with carnivores, and sheep.

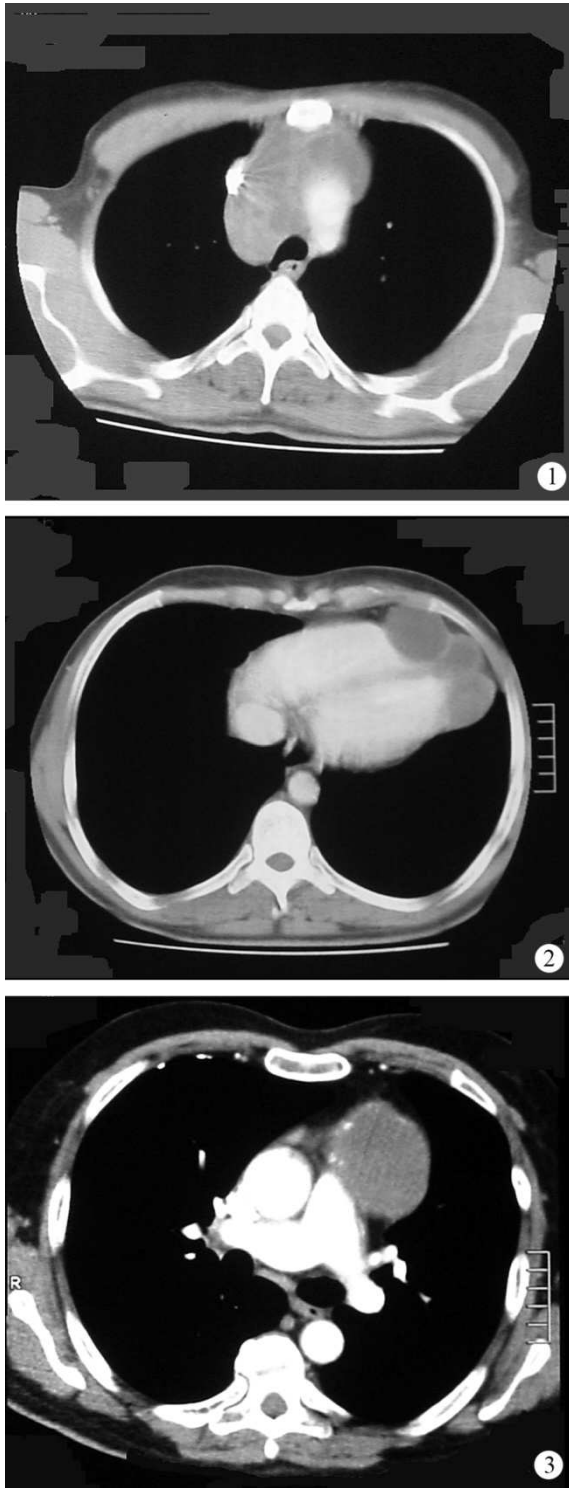


Figure 1. Computed tomography scan demonstrating multiple cystic lesions at anterior mediastinum.
 2. Computed tomography scan demonstrating three cystic lesions at the left pericardium.
 3. Computed tomography scan showing a well-defined lobulated cystic lesion at the left anterior mediastinum.

His laboratory tests were normal except for mild leucocytosis. CT scan of the thorax showed a well-defined lobulated cystic lesion 7 x 7 cm in size at the left anterior mediastinum (Figure 3). The heart and major vascular structures appeared normal. The patient underwent left-sided posterolateral exploratory thoracotomy. The cyst was found in the mediastinum, and it was diagnosed to be an hydatid cyst. Total cyst excision was performed. The postoperative stay of the patient in the hospital was uneventful, and he was discharged on the sixth day. The patient received albendazole (10 mg/kg) daily for three months postoperatively and there was no recurrence of the disease during a follow-up of 6 months.

DISCUSSION

Echinococcosis is a zoonotic infection caused by *Echinococcus* species and is one of the most important helminthic diseases worldwide. Although the disease is endemic to our country, few surveys have been performed (4). The prevalence of the infection in dogs varies widely between 0.32 and 40% in different areas of Turkey (5). Prevalence of echinococcosis was found to be 22.6% in cattle and 67.6% in sheep (6). The incidence of the disease in Turkish people is 0.87-6.6/100000 as reported by Merdivenci (7). In a very recent study published in 2008, the incidence is 6.3/100000 (2).

Hydatid cyst has a predilection to locate in liver, lungs, and brain. Although many uncommon locations have been reported, the disease is rarely present in the mediastinum. Approximately 100 cases have been described in the English literature so far (8). Among intrathoracic hydatid cysts, the incidence of mediastinal echinococcosis is about 0.1-0.5% (8, 9). Posterior mediastinal or paravertebral involvement of mediastinal hydatid cysts are more common (55%), but about 36% of the cysts are located in anterior mediastinum (9). Both of our patients had anterior mediastinal involvement, and in addition, one had three cystic lesions in the pericardium.

Mediastinal echinococcosis is neither clinically nor radiologically distinguishable from other mediastinal cystic lesions. In such cases, the diagnosis can be made by surgery. In a recent study, Shehatha performed Casoni's intradermal reaction and Weinberg's complement fixation tests for all his 763 patients and detected positive results in 73% and 86% of the cases respectively (10). However, due to their low diagnostic values, variable sensitivity and limited specificity, these tests are not routinely performed or are discontinued in most studies (8, 11). Many serologic tests including the indirect immunofluorescence assay, the indirect hemagglutination test, immunoelectrophoresis, enzyme-linked immunosorbent assay are being proposed today, and judicious application of these techniques may confirm the diagnosis in 80% to 94% of hepatic hydatidosis cases and in the 65% of pulmonary cases (12). We did not perform any serological tests due to their relatively low diagnostic values, and in both cases, the definitive diagnosis was made by surgery.

Symptoms and complications of cyst depend on size, location and involvement of neighboring structures. A large mediastinal hydatid cyst may compress the vital organs and produces pressure symptoms, similar with other mediastinal cystic lesions (13). Symptoms range from retrosternal and parasternal pain, cough, dysphagia to dyspnea or severe compression of the trachea and superior vena cava (8). Both of our patients were symptomatic.

The gold standart therapy is radical removal of the germinative membrane and pericyst. When the localization of the cysts and invasion to vital structures prevent the total excision, partial pericystectomy and removal of germinative membrane is suggested (9). Albendazole has been used as primary drug therapy and as an adjunct to surgery to diminish recurrence and potentila spread of the organism (14). We performed total excision in both of our patients and administered postoperative albendazole treatment. No recurrence was seen in their follow-up.

Hydatid cysts may be located in many different sites, including extrapulmonarily in the mediastinum. They should be considered in the differential diagnosis of mediastinal cystic lesions especially in the endemic regions. Surgical removal is the treatment of choice for mediastinal hydatid cysts, and additional medical therapy may avoid recurrence.

REFERENCES

1. **Harlaftis NN, Aletras HA, Symbas PN**, 2005. Hydatid disease of the lung. Shields TW, LoCicero J III, Ponn RB, Rusch VW. eds. *General Thoracic Surgery*. Philadelphia: Lippincott Williams and Wilkins. p.1298-1308.
2. **Yazar S, Taylan Özkan A, Hökelek M, Polat E, Yılmaz H, Özbilge H, Üstün Ş, Koltaş İS, Ertek M, Şakru N, Alver O, Çetinkaya Z, Koç Z, Demirci M, Aktaş H, Parsak CK, Özerdem D, Sakman G, Cengiz ZT, Özer A, Keklik K, Yemenici N, Turan M, Daştan A, Kaya E, Sönmez Tamer G, Girginkardeşler N, Türk M, Sınırtaş M, Evcı C, Kılıçturgay S, Mutlu F, Artış T**, 2008. Türkiye’de 2001-2005 yılları arasında kistik ekinokokkozis. *Türkiye Parazitoloj Derg*, 32: 208-220.
3. **Oğuzkaya F, Akçalı Y, Kahraman C, Emiroğulları N, Bilgin M, Şahin A**, 1997. Unusually located hydatid cysts: Intrathoracic but extrapulmonary. *Ann Thorac Surg*, 64: 334-337.
4. **Altıntaş N**, 2003. Past to present: Echinococcosis in Turkey. *Acta Tropica*, 85: 105-112.
5. **Tınar R, Coşkun SZ**, 1991. Cyst hydatid disease in animals. Özcel MA. ed. Echinococcosis, vol. 10. *Turkish Society of Parasitology Publications*, p. 157-196.
6. **Yılmaz H**, 1999. Recent status of hydatidosis in Van. *Abstract Book of 11th National Congress of Parasitology*, Sivas, Turkey, September 6-10. p. 83.
7. **Merdivenci A, Aydınlioğlu K**, 1982. *Hidatidoz* (Hidatik Kist Hastalığı). İÜ Cerrahpaşa Tıp Fak Yayınları, İstanbul, No:2972/97.
8. **Thameur H, Chenik S, Abdelmoula S, Bey M, Hachicha S, Chemingui M, Mestiri T, Chaouch H**, 2000. Thoracic hydatidosis: a review of 1619 cases. *Rev Pneumol Clin*, 56: 7-15.
9. **Rakower J, Milwidsky H**, 1960. Primary mediastinal echinococcosis. *Am J Med*, 29: 73-83.
10. **Shehatha J, Alizzi A, Alward M, Konstantinov I**, 2008. Thoracic hydatid disease: a review of 763 cases. *Heart Lung Circ*, 17: 502-504.
11. **Kavukçu Ş, Kılıç D, Tokat AO, Kutlay H, Cangır AK, Enön S, Ökten İ, Özdemir N, Güngör A, Akal M, Akay H**, 2006. Parenchyma-preserving surgery in the management of pulmonary hydatid cysts. *J Invest Surg*, 19: 61-68.
12. **Biava MF, Dao A, Fortier B**, 2001. Laboratory diagnosis of cystic hydatid disease. *World J Surg*, 25: 10-14.
13. **Özdemir N, Akal M, Kutlay H, Yavuzer Ş**, 1994. Chest wall echinococcosis. *Chest*, 105: 1277-1279.
14. **Mawhorter S, Temeck B, Chang R, Pass H, Nash T**, 1997. Nonsurgical therapy for pulmonary hydatid cyst disease. *Chest*, 112: 1432-1436.