



THE EVALUATION OF THE INFECTIONS AFTER ALGOLOGIC POSTERIOR PARAVERTEBRAL INJECTIONS

Gürdal NUSRAN¹,
Doğaç KARAGÜVEN²,
Kürşat BAYRAKTAR³
Murat TÜYSÜZ¹,
Yunus ATICI²,
İ. Teoman BENLİ².

¹ Çanakkale 18 March University Medical Faculty, Department of Orthopaedics and Traumatology, Çanakkale, Turkey.

² İstanbul Okan University Medical Faculty, Department of Orthopaedics and Traumatology, Tuzla, İstanbul, Turkey.

³ University of Medical Sciences, Okmeydanı Research and Training Hospital, Department of Orthopaedics and Traumatology, Okmeydanı, İstanbul, Turkey.

Address: Prof. Dr. İ. Teoman Benli, İstanbul Okan Üniversitesi Tıp Fakültesi, Ortopedi ve Travmatoloji Anabilim Dalı, Aydınlı Yolu, No: 2, İçmeler, Tuzla, İstanbul, Turkey.

GSM: +90 532 205 85 62

E-mail: cutku@ada.net.tr

Received: 10th October, 2017.

Accepted: 12th December, 2017.

ABSTRACT

Background Data: Recently, the development of algology and the increase of algological initiatives have accompanied complications. Especially in patients with immune system disorders, epidural abscesses, facet joint septic arthritis, or abscess formation in paravertebral muscles have significantly increased after corticosteroid injections, especially applied to the disc, around nerve roots and facet joints.

Aim: The aim of this study is to evaluate the cases of infections after 1028 algological treatments in 3 hospitals.

Patients and Method: In this study, 24 patients who were referred to Orthopedics and Traumatology clinics with low back pain and fever, were evaluated retrospectively. 16 of the patients were male and 8 were females. The mean age was determined as 62.6 ± 10.4 (46-92). These patients were questioned for diabetes mellitus, history of tuberculosis, immunodeficiency syndromes and their epidemiological characteristics. The isolated microorganisms and complications associated with clinical findings have been evaluated and classified. In addition, it has been investigated whether the infections are eradicated or not in these treatments. Root blockage was found in 12 (50%) of the infected patients, facet joint injection in 6 (25%) and paravertebral intramuscular injection in 6 (25%). 4 (16.7%) of these patients developed epidural abscesses, 4 (16.7%) had facet joint septic arthritis, and 16 (66.6%) of them developed paravertebral intramuscular abscess formation. All of the patients were surgically drained and facet joint fusion was performed in the cases of septic arthritis.

Results: There were 1028 cases of algological intervention in the last two years in these three hospitals. It was determined that 24 or more of these cases developed superficial or deep infection. The infection rate was generally found to be as high as 2.34%. Additionally, it was found that 8 (33.3%) of the patients had received insulin-dependent diabetes mellitus treatment, 12 (50%) received oral antidiabetic drugs due to Type-2 diabetes, and 1 patient had a treated tuberculosis. No cases were found to have immunodeficiency (such as AIDS). Prophylactic antibiotics were not used in any of the patients. At the end of the treatment regimen, CRP and ESR values decreased statistically and came to normal values ($p < 0.05$). The variance analysis shows that the most important predisposing factors were; cigarette, DM and the processing conditions of the injections ($p < 0.05$).

Conclusion: It has been detected that the use of prophylactic antibiotics is particularly important in patients with impaired immune system and diabetes mellitus. It has been suggested that the most important measure in the prevention of infections in algological interventions is to perform these procedures in sterile conditions, especially in operating room conditions with positive pressured ventilation.

Key words: Paraspinal injection complication of algological intervention, infection, epidural abscess

Level of evidence: Retrospective clinical study, Level III.

INTRODUCTION

Throughout history, pain has become one of the most important health problems of human beings. Throughout life, every person has had at least one complaint

of back pain ⁽¹⁾. As a result, in modern medical applications, a medical discipline which deals with pain treatment has emerged. Many specialists working in this field are usually injecting analgesics

and corticosteroids into facet joints or foraminal areas to find causes leading to low back pain or for therapeutic purposes⁽⁸⁾. Algological intervention procedures have been used frequently in recent years, especially in destructive and metastatic involvement of the spine, such as malignant tumors, disc hernias or spinal stenosis, where neuronal structures are repressed⁽²⁾ It has been determined that there are 5 major complications in these interventions⁽¹²⁾. **1) Allergic reaction.** Usually, the allergy is to the X-ray contrast or steroid; rarely to local anesthetic. Life threatening or severe allergies are rare. **2) Bleeding.** A rare complication, bleeding is more common for patients with underlying bleeding disorders or in patients on blood thinners. **3) Discomfort at the point of the injection or worsening of pain symptoms.** These symptoms are usually mild and short-lived. Long lasting increases in pain are rare. **4) Nerve or spinal cord damage or paralysis.** While very rare, damage to the spinal cord or spinal nerves can occur from direct trauma from the needle, or secondarily from infection, bleeding resulting in compression, or injection into an artery-causing blockage. **5) Infection.** Minor infections occur in less than 1 % to 2 % of all injections. Severe infections are rare, occurring in 0.1 % to 0.01 % of injections^(2,8).

In this study, the rates of superficial and deep infections that are rarely seen during paraspinal algological interventions were evaluated, the predisposing factors in these patients were investigated and treatment options were discussed.

PATIENTS AND METHODS

In this study, 24 patients who applied to 3 different hospitals with the complaint of low back pain and fever after paraspinal injections during the last 2 years were evaluated retrospectively. There were 1028 cases in which the algological procedures were performed in these 3 hospitals and 24 (2.34%) of these cases were found to develop superficial or deep infection. 16 of the patients were male and 8 were females. The mean age was determined as 62.6 ± 10.4 (46-92). These patients were questioned for diabetes mellitus, history of tuberculosis or immunodeficiency syndrome and their epidemiological characteristics. The isolated microorganisms and complications associated with clinical findings have been evaluated and classified. It was also investigated whether the infections were eradicated after treatments. 24 patients who developed infection after algological injections were evaluated in terms of the causes of predisposing factors such as age, sex, smoking, diabetic, immunodeficiency disease, malignancy and the infected part the of the spine.

Clinical and Laboratory Examination

All of the patients were applied to the hospital with severe pain and high fever, and 4 (16.7%) patients had neurological deficits. Histories of all the patients were similar which was about paravertebral joint injection after drug-resistance back pain. In their laboratory test, CRP, ESR and WBC increases was established. Main CRP value was 11.5 ± 5.1 mg/dl and ESR value was 61.0 ± 17.7 mm/h in patient's first admittance. Four of the patients had neurological deficits. The lower limb

muscle strength was 2/5 at 2 cases, 3/5 at 1 case and 4/5 at 1 case.

Radiological Evaluation

Definitive diagnosis was made with MR examinations. Root blockage was found in 12 (50%) of the infected patients, facet joint injection in 6 (25%) and paravertebral intramuscular injection in 6 (25%). 4 (16.7%) of these patients developed epidural abscesses, 4 (16.7%) had facet joint septic arthritis, and 16 (66.6%) of them developed paravertebral intramuscular abscess formation.

Surgical Technique

All of the patients were surgically drained and facet joint fusion and debridement was performed in cases of septic arthritis. Four patients with epidural abscess with neurological deficit underwent emergent posterior decompression and epidural abscess drainage with physiological saline and posterior short segment instrumentation with extensive decompression.

Four patients (16.7%) underwent epidural abscess drainage with posterior decompression, and 3 of these 4 patients underwent short segment posterior instrumentation for preservation of spinal stability (Figure-1).

In 4 patients with facet joint septic arthritis, articular debridement and facet fusion with local auto grafts was performed because of unilateral involvement.

In patients with paravertebral abscess formation, only a short incision was inserted into the abscess loin, abscess was drained, and the infected tissues were debrided. In patients with paravertebral abscess formation, abscess cavity is drained with a short incision and the infected tissues are debrided (Figure-2).

Microbiological Tests and Antibiotherapy

In 17 (70.8%) patients Staphylococcus aureus was produced, in 4 (16.7%) patients no micro-organism was produced. Pseudomonas aeruginosa, E. coli and Proteus and Klebsiella was produced in one of the patients each. (4.2%). Empirical antibiotherapy was given initially. After the bacteria was isolated from the culture specimen the regimen was changed.

Patients were followed up with CRP, and antibiotherapy was continued until the level of CRP fell below 0.5.

Statistical Analysis

SPSS v21.0 for Windows (SPSS, Armonk, NY, USA) was used for statistical analysis. Student T-test and one way ANOVA test and Pearson correlation tests were used. The probability value was taken as 0.05.

RESULTS

Twenty-four patients who had previously been injected from the waist and had fever and resistance to painkillers were included in this study. In the last 2 years, 16.7% of

the patients who underwent algological intervention were found to develop infection following the procedure. In the MRI study, 4 (16.7%) had epidural abscesses, 4 (16.7%) had facet joint septic arthritis and 16 (66.6%) had paravertebral intramuscular abscesses (Table-1).

In 17 (70.8%) patients *Staphylococcus aureus* was produced, in 4 (16.7%) patients no micro-organism was produced. *Pseudomonas aeruginosa*, *E. coli* and *Proteus* and *Klebsiella* was produced in one of the patients each (4.2%).

In all patients, paravertebral, epidural and facet joint septic arthritis were surgically debrided, using parenteral antibiotics for a mean of 4.7 ± 1.3 weeks, followed by oral antibiotics for 2 weeks. Antibiotherapy treatment was followed by a decrease in CRP of less than 0.5.

At the time of admission, CRP and ESR values were determined as 11.5 ± 5.1 mg / dl and 61.0 ± 17.7 mm / h, respectively. At the end of the treatment, it was determined

that CRP and ESR values decreased significantly, and all patients had normal levels ($p < 0.05$). All patients who had epidural abscesses with neurologic deficit at the time of admission had full neurological improvement after operation.

All of the 4 (16.7 %) patients who developed epidural abscess were included in the 12 (50 %) patients who underwent root blockade. Patients with facet joint septic arthritis were all found to be from patients with root blockade. Almost all of the paravertebral intramuscular injection models have localized abscess formation in the muscle. Infection was eradicated in all patients after a mean of 4.7 ± 1.3 weeks parenteral and 2 weeks after oral antibiotherapy, and there was no recurrence of any infection except a patient within 2 years of follow-up. The recurrent patient (%4,2) has facet joint arthritis who was over 60 years old and was performed root blockade before. The wound was reopened in this patient and VAC treatment was applied and the wound was left to secondary healing.

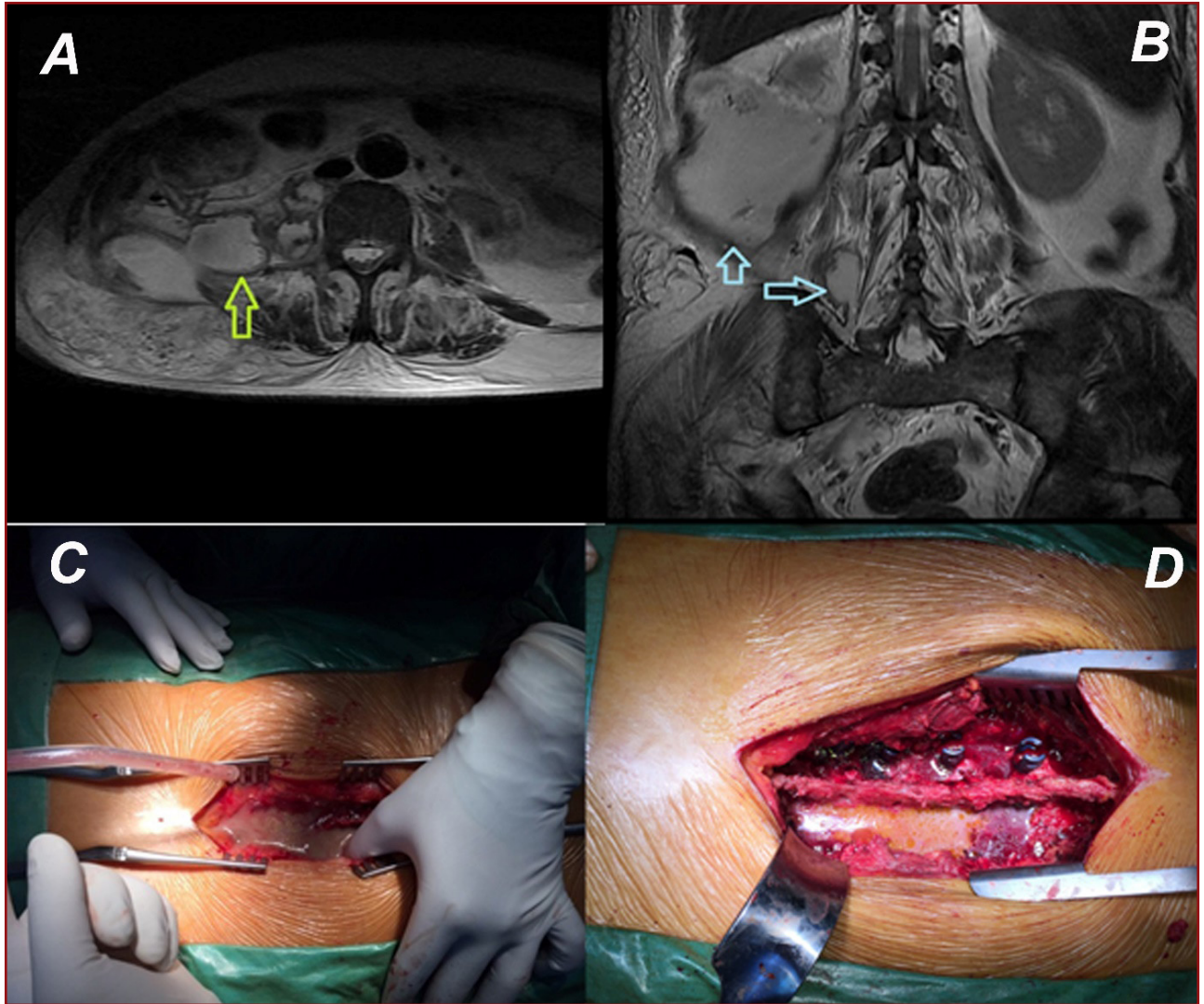


Figure-1. A) Epidural apse formasyonu gelişen ve retroperitoneal bölgeye apse yayılımı olan hastanın preoperatif aksiyel, **B)** koronal MR görüntüleri. Aps ok ile işaret ediliyor. **C)** Epidural apse drenajı için dekompresyon ve **D)** debridmanı takiben yapılan enstrümantasyon görülüyor.

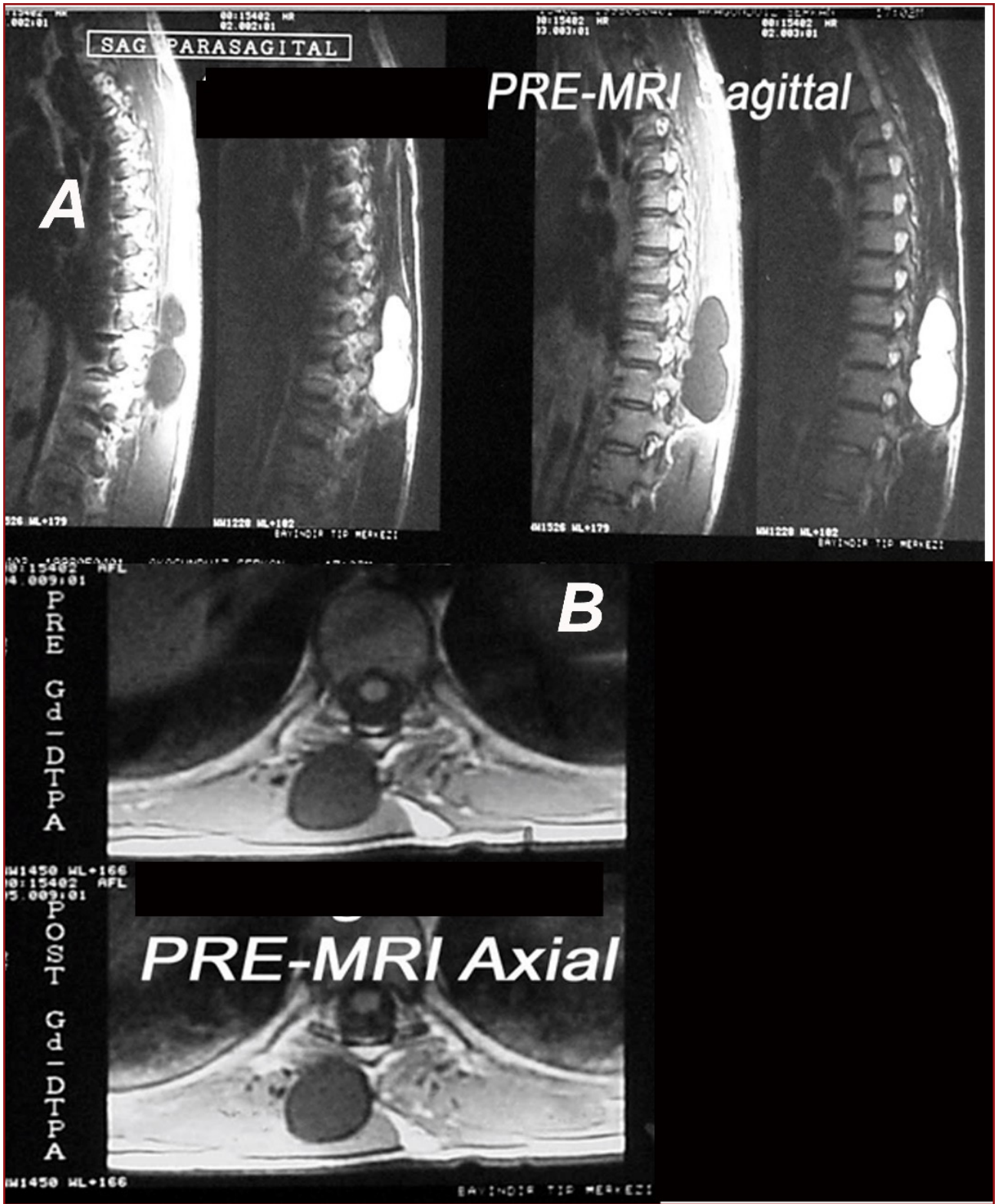


Figure-2. Paravertebral adele içinde apse formasyonu gelişen hastanın **A)** sagittal ve **B)** aksiyel MR görüntüleri.

Table-1. Hastaların epidemiyolojik bilgileri, laboratuvar değerleri, klinik bulguları ve predispozan faktörlerin var olup olmadığı görülmüyor.

P-no.	Name	Sex	Age	AI	SI	CRP	ESR	MO	Where	TA (week)	Smoking	DM	ID	Operation	Recurrence	Last CRP	Last ESR
1	DF	F	66	FJI	FJA	7,7	64,6	SA	OPC	3	(+)	(+)	(-)	D+FJA	(-)	0,11	4,6
2	EG	M	74	FI	EA	22,4	105	PA	OPC	6	(+)	(+)	(-)	D+L+PE	(+)	0,42	3,2
3	FG	M	60	FI	EA	12,6	53	SA	OPC	3	(+)	(+)	(-)	D+L+PE	(-)	0,05	3,4
4	DD	M	92	FI	EA	16,4	102	EC+P	OPC	6	(+)	(+)	(-)	D+L+PE	(+)	0,5	4,4
5	AC	F	75	FI	EA	9,9	78	SA	OPC	6	(+)	(+)	(-)	D+L	(-)	0,5	4,9
6	SS	M	46	FI	PSA	17,5	44,4	(-)	OPC	6	(+)	(+)	(-)	Drenage	(-)	0,5	5
7	AG	M	49	FI	PSA	11,6	56,2	SA	OPC	6	(+)	(+)	(-)	Drenage	(-)	0,01	3,4
8	SD	M	65	PSM	PSA	6,5	44,9	SA	OPC	4	(+)	(+)	(-)	Drenage	(-)	0,04	0,5
9	DE	F	61	PSM	PSA	5,7	48,9	(-)	OPC	4	(-)	(-)	(-)	Drenage	(-)	0,1	0,5
10	KA	M	62	FI	PSA	7,4	44,2	(-)	OPC	4	(+)	(+)	(-)	Drenage	(-)	0,22	0,5
11	ST	F	73	PSM	PSA	4,4	62,4	SA	OPC	3	(-)	(-)	(-)	Drenage	(-)	0,05	0,5
12	SR	M	51	FJI	FJA	11,4	68,8	KP	OPC	4	(+)	(+)	(-)	D+FJA	(-)	0,42	0,5
13	CF	F	56	FJI	PSA	11,9	69,7	SA	OPC	4	(+)	(+)	(-)	Drenage	(-)	0,44	0,5
14	SH	M	61	FJI	FJA	11,9	74,1	SA	OPC	4	(+)	(+)	(-)	D+FJA	(-)	0,44	0,5
15	BA	M	77	FJI	PSA	11,3	68,2	SA	OPC	4	(+)	(+)	(-)	D+FJA	(-)	0,43	0,5
16	BT	M	45	FI	PSA	18,4	89,8	SA	OPC	6	(+)	(+)	(-)	Drenage	(-)	0,33	0,5
17	YY	F	62	FI	FJA	25,6	86,9	SA	OPC	8	(+)	(+)	(-)	Drenage	(-)	0,49	4,9
18	YG	M	66	PSM	PSA	6,7	59,8	SA	OPC	4	(+)	(-)	(-)	Drenage	(-)	0,05	1,1
19	ZD	M	57	PSM	PSA	7,1	35,9	(-)	OPC	4	(+)	(-)	(-)	Drenage	(-)	0,12	2,2
20	SM	F	65	FJI	PSA	12,6	67,4	SA	OPC	6	(+)	(+)	(-)	Drenage	(-)	0,21	2,8
21	MA	M	61	FI	PSA	12,7	68,9	SA	OPC	6	(+)	(+)	(-)	Drenage	(-)	0,23	3,9
22	TE	M	49	FI	PSA	11,7	71,4	SA	OPC	6	(+)	(+)	(-)	Drenage	(-)	0,11	2,9
23	NA	F	64	FI	PSA	10,9	58,9	SA	OPC	6	(+)	(+)	(-)	Drenage	(-)	0,07	0,5
24	SK	M	66	PSM	PSA	7,7	44,8	SA	OPC	4	(+)	(+)	(-)	Drenage	(-)	0,05	3,2
Av.			62,625			11,48092077	61,0025			4,7320416						0	2,265073029
SD			10,37617			5,115662225	17,66475			1,3010412						0	1,726825725

P-No: Number of patient, AI: Algologic intervention, SI: Side of infection, MO: Mikroorganizma, TA: The time of antibiotherapy, DM: Diabetes mellitus, ID: Immun deficiency
EA: Epidural abscess, FI: Foraminal Injection, PSM: Paraspinal muscle injection, FJI: Faset joint injection, FJA: Septic arthritis of faset joint, PSA: Paraspinal abscess in the muscles
SA: Staph. Aureus, EC+P: E.Coli ve Proteus, PA: Pseudomonas Auregenesa, OPC: Outpatient clinic, OT: Operation theatre, D+FJA: Drenaj+faset eklemler arthrodezi,
D+L+PE: Laminektomi ile dekompresyon, debridman ve posterior enstrümantasyon, Av. Average, SD: Standart deviation

The age and gender of the patient were not correlated with infection rates (r -age: 0.11, r -sex: 0.06, $p > 0.05$). It was determined that the patients' diabetic status, smoking habits and injection molding environment had direct correlation with infection severity (r -diabet: 0.66, r -smoking: 0.56, r -injection environment: 0.76, $p < 0.01$) and these three variables were found to have one way similar variant analysis. ($p < 0.05$).

DISCUSSION

Pyogenic infections of the spine, especially in elderly patients, arise in the presence of predisposing factors and by micro-organisms that hematogenously originate from a primary infection site. These predisposing factors are; immunodeficiency diseases, immune suppressive treatment of the patient, diabetes mellitus, metabolic diseases malabsorption syndromes and malignancy^(1,6). Other important mechanisms in spinal infections are contaminations after surgical interventions⁽⁷⁾. Postoperative spine infections generally occur in cases where sterilization conditions are not observed and active infection focuses are ignored during the operation. That is why it is very important that the operation area, the operating room, the operators' hands, and the operating material and instruments used are as sterile as possible⁽⁷⁾. In general, infection is very rare in spinal and epidural anesthesia^(5,9). The main complication of such attempts is that the risk of injury to the neural structures and anesthesia are maintained at higher levels than desired⁽⁸⁾. Infection in paravertebral algological injections is even less common. Minor infections occur in less than 1 % to 2 % of all injections. Severe infections are rare, occurring in 0.1 % to 0.01 % of injections^(2,8). In this study, it was determined that there were 24 cases of infection after algological invasive procedures and that the prevalence of infection rate was 2.34 %, which is consistent with the rates given in the literature.

In this study, 4 (16.7 %) patients had epidural abscesses, 4 (16.7 %) facet joint septic arthritis and 16 (66.6 %) paravertebral intramuscular abscesses. All of the 4 (16.7 %) patients who developed epidural abscess were found in 12 (50 %) patients who underwent root blockade. Four (16.7 %) of the patients with facet joint septic arthritis were also found to be from patients with root blockade. Almost all of the paravertebral intramuscular injection models have localized abscess formation in the muscle. Although no significant statistical correlation was found, it is thought that foraminal injections were more risky for epidural abscess and facet joint arthritis.

Paravertebral injection for back pain is wide spreading with clinicians for severe back pain diseases. It is believed that interarticular steroid injection is the important way for the diagnosis and treatment of the paravertebral facet and other joint inflammatory disease. Paraspinal abscess are rare seen diseases and delay in diagnosis. The main aim of the paraspinal abscess is eradication of the infection, measuring of recurrent and neurologic deficit, remove of the back pain and stabilization of the spinal and paraspinal integrity. Although diagnosis is delay, surgical treatment and correct antibiotherapy results is successful and have good prognosis. In this study, the

microbiologic agent is generally *Staphylococcus Aureus* (70.8 %).

No growth was detected in culture in 4 cases. In the literature, negative culture rate is reported very high (8). In these patients, empirical antibiotherapy was started until the antibiotic susceptibility test. Parenteral antibiotics are used for 3-4 weeks to the patients with paravertebral intramuscular abscesses and 6 weeks to the patients with epidural abscess and facet joint arthritis, and subsequently oral antibiotics were used for 2 weeks. antibiotherapy continued until the level of CRP decreases below 0.5.

Four patients (16.7%) were diagnosed as epidural abscess, all underwent extensive decompression and three were treated surgically by posterior instrumentation. Postoperative neurological situations were completely resolved in these patients with various grades of neurological deficits.

There are about 40 cases published in the literature until the present day that septic arthritis develops after intra-articular steroid injections. Two facet joint arthritis included in this study are 2 new cases participating in this issue. Both of these cases developed after injection of facet joints and were surgically treated. Cook and colleagues published cases of paraspinal abscesses in 1999⁽⁴⁾.

Alcock et al.⁽³⁾ reported that epidural abscess formation developed in a patient with facet joint infection in 2003, and Rhue et al. (2011) presented a case of epidural abscess and paraspinal abscess in 2011.⁽¹⁰⁾ Pilleul and Garcia mentioned about the importance of MR in early diagnosis in patients with facet joint arthritis⁽⁸⁾. In this study, the entire paravertebral abscess formations were diagnosed with MR.

As with all pyogenic post-operative infections, the predisposing factors for infection development after algological processing are approximately the same⁽²⁾. In this study, it was determined that age and gender did not play a role in the predisposition. Especially in patients with diabetes, smoking and outpatient clinics were found to be statistically significant ($p < 0.05$). According to the data of this study, patients with diabetes must quit smoking and algological procedures should be performed under positive pressure surgical theater conditions.

The most important limitation of this study is that the rate of predisposing factors in all algological treated patients is not taken into consideration and there is no comparison with infected patients. For this reason, it is clear that a prospective study will be more realistic in terms of determining the incidence of paraspinal infection in all algological procedures over a period of time. Obviously only a prevalence value obtained in this study.

Horlocker, suggest that the behavioral habits of the anesthesiologist are one of the determining factors in increasing the incidence of infection at spinal and epidural anesthesia even though all sterilization conditions are provided. It has been observed that the anesthesiologists or algologists who entered the treatment did not wash as if they

had entered an operation, they did not usually wear sterile gowns and repeated the operation with the same injectors ⁽⁵⁾.

As a result, algological procedures should be performed under maximum sterile conditions and compliance with sterilization rules, if possible in positive pressure operating rooms and prophylactic antibiotics should be used to prevent paraspinal infections if there are predisposing factors in the patient.

REFERENCES

1. Akalın S, Benli IT, Erken Y. Spinal enfeksiyonların cerrahi tedavisinde genel prensipler. In: Benli IT (Ed.). Omurga Enfeksiyonları. Türk Omurga Derneği Yayınları-4, Genişletilmiş 2. Baskı, Rekmay Yayıncılık, Ankara 2016; pp: 341-368.
2. Akkaya T, Sayın M. Transforaminal epidural steroid injection and its complications. *Ağrı* 2005; 17(3): 27-39.
3. Alcock E, Regaard A, Browne J. Facet joint injection: a rare from cause of epidural abscess formation. *Pain* 2003; 103: 209-210.
4. Cook NJ, Hanrahan P, Song S. Paraspinal abscess following facet joint injection. *Clin Rheumatol* 1999; 18: 52-53.
5. Horlocker TT Complications of spinal and epidural anesthesia. *Anesthesiol Clin North Am* 2000;18(2): 461-485.
6. Kaya A, Benli IT, Bayraktar MK. İmmün yetmezlikli hastalarda omurga enfeksiyonları. In: Benli IT (Ed.). Omurga Enfeksiyonları. Türk Omurga Derneği Yayınları-4, Genişletilmiş 2. Baskı, Rekmay Yayıncılık, Ankara 2016; pp: 427-442.
7. Kaya A, Erken Y, Benli IT. Postoperatif omurga enfeksiyonları. In: Benli IT (Ed.). Omurga Enfeksiyonları. Türk Omurga Derneği Yayınları-4, Genişletilmiş 2. Baskı, Rekmay Yayıncılık, Ankara, 2016, pp: 397-416.
8. Perruchoud C, Albrecht E, Moret V. *Manuel pratique d'algologie: Prise en charge de la douleur chronique*. Elsevier Health Sciences, Montpellier 2017.
9. Pilleul F, Garcia J. Septic arthritis of spine facet joint; early positive diagnosis on magnetic resonance imaging. Review of two cases. *Joint Bone Spine* 2000; 67: 234-237.
10. Raj V, Foy J. Paraspinal abscess associated with epidural in labour. *Anaesth Intensive Care* 1998; 26: 424-426.
11. Rhyu KW, Park SE, Ji JH, Park I, Kim YY. Pyogenic arthritis of the facet joint with concurrent epidural and paraspinal abscess: a case report. *Asian Spine J* 2011; 5(4): 245-249.
12. Sangbong K, Chae, Seungbum C. Successful treatment of paraspinal abscess with percutaneous drainage and parenteral antibiotic therapy: three cases and a review of the literature. *Curr Orthop Pract* 2016; 27(6): 710-715.