



PERIOPERATIVE CARDIAC ARREST OF A YOUNG MALE DURING KYPHOSIS OPERATION: CASE REPORT

M. Bülent BALİOĞLU¹,
Osman ÇİMEN²,
Özgür KORKMAZ³,
Deniz Akşahin KARATAŞ⁴,
Şenol YAZICI⁴,
M. Akif KAYGUSUZ⁴

¹*Istinye University LIV Hospital,
Department of Orthopaedics and
Traumatology, İstanbul, Turkey.*

²*Elazığ Hayat Hospital, Department of
Orthopaedics and Traumatology, Elazığ,
Turkey.*

³*Or-Ahayım Balat Hospital,
Department of Orthopaedics and
Traumatology, İstanbul, Turkey.*

⁴*SB Metin Sabancı Baltalimanı
Hospital of Bone and Joint Disease,
Department of Orthopaedics and
Traumatology, İstanbul, Turkey.*

Address: İstinye University LIV Hospital,
Department of Orthopaedics and
Traumatology, İstanbul, Turkey.
Phone: +90 532 252 14 83
E-Mail: mbbalibey@gmail.com
Received: 18th October, 2017.
Accepted: 11th December, 2017.

ABSTRACT

There are complications related to blood loss, impaired liquid-electrolyte balance, drug side effects due to anesthetic applications and overdose complications due to airway and ventilation problems, central venous intervention, iatrogenic neurological and vascular injuries, internal organ injuries, cardiac arrest due to vagal reaction or any other idiopathic causes in spinal surgery. The aim of our study is to pass on our experience about cardiopulmonary arrest development, which is a rare complication in a perioperative period, and treatment of this situation in a patient with Scheuermann's kyphosis who is planned to operate with posterior surgery. Our patient was a male, 17 years old, 170 cm long, weighing 50 kg with a T3-T12 lateral cobb angle of 77 degrees thoracic kyphosis without waist and back pain. During the operation, hyperkalemia, which was thought to be related to hemolysis and massive blood transfusion, was noticed as a pathological finding in the blood tests. The patient intervened with the defibrillator after starting ventricular fibrillation and spontaneous breathing after 45 minutes of resuscitation. He was taken to intensive care unit immediately. He was transferred to in-room service after 9 days. Post-operative evaluation of the patient did not reveal any neurological deficits due to global ischemia secondary to cardiac arrest or because of the surgical procedure. He was discharged after 4 days and started to work after 5 months. We thought that cardiac arrest development is associated with massive transfusion and /or hyperkalemia secondary to hemolysis. The cause of hemolysis was not clearly demonstrated.

Key words: Perioperative, cardiac arrest, kyphosis, spinal, Scheuermann

Level of Evidence: Case Report, Level IV

INTRODUCTION

In spinal deformity surgery there are complications related to blood loss, impaired liquid-electrolyte balance, drug side effects due to anesthetic applications and overdose complications due to airway and ventilation problems, central venous intervention, iatrogenic neurological (cauda equina syndrome, spinal cord injury, nerve root damage) and vascular injuries, internal organ injuries (bowel, bladder injury etc.) ,dead, malignant hypothermia, cardiac arrest due to vagal reaction or any other idiopathic causes ^(6,8).

Surgeon should be prepared for the potential complications of the surgery while preparing the patients for spinal surgery and the medical condition of the patient needs to be evaluated carefully. The most important determinants of the patient's health status and perioperative

complications are comorbid diseases of the patient⁽¹⁾. These diseases include lung diseases such as asthma, heart diseases such as coronary artery disease and cardiomyopathy, diabetes mellitus, hypertension, spinal cord injury and other chronic diseases ⁽¹⁾. Internal medicine doctors, anesthesiologists, should carefully assess patients pre-operatively and pediatric physicians for pediatric patients, and psychiatric doctors for patients who are taking medicines, and drug modifications should be recommended in patients with regular medication use.

It is important to describe the perioperative period and cardiac arrest terms in this study. The definition of perioperative period varies in many studies. It is defined as only intraoperative period ⁽³⁾, intraoperative period and time until wake up after anesthesia ⁽⁷⁾, postoperative

first 24 hours ⁽⁸⁾, postoperative first 2 days ⁽⁴⁾, postoperative first week and postoperative first month ⁽²⁾. In our study, we mean intraoperative period by using the perioperative period term. Cardiac arrest can be defined as a condition requiring resuscitation by either closed or open heart massage ⁽¹⁰⁾.

The aim of our study is to pass on our experience about cardiopulmonary arrest development, which is a rare complication in a perioperative period, and treatment of this situation in a patient with Scheuermann's kyphosis who is planned to operate with posterior surgery.

CASE REPORT

Our patient was a male, 17 years old, 170 cm long, weighing 50 kg with a T3-T12 lateral cobb angle of 77 degrees thoracic kyphosis without waist and back pain. The patient underwent central venous catheter under general anesthesia. The patient were placed in the prone position with both shoulder and iliac crests with appropriate cushion supports. After the patient's paraspinal muscles were stripped, the thoracic spine vertebrae left-side T3-L1 facet joints vertebrae were revealed. Facet joint osteotomies were performed. Polyaxial screws were inserted into the left side vertebral pedicles up to T3 to L1. Approximately 2 hours and 15 minutes after the start of the operation, the anesthesia team stated that the cardiopulmonary

arrest of the patient with mild restrictive pulmonary disease in the previous pulmonary function test was developed. The patient had no cardiac problems before the operation at the same time. The patient's incision was closed with a sterile sponge and pads and the patient's face was turned down and resuscitation was performed. Blood samples for blood gas and biochemical examination were taken while resuscitation was ongoing. Hyperkalemia, which was thought to be related to hemolysis and massive blood transfusion, was noticed as a pathological finding in the blood tests. The patient intervened with the defibrillator after starting ventricular fibrillation and spontaneous breathing after 45 minutes of resuscitation. Thoracal rib fractures and pneumothorax were noted during resuscitation. The patient was again turned over and the skin was closed with a stapler and taken to intensive care unit immediately. He was transferred to in-room service after 9 days. Post-operative evaluation of the patient did not reveal any neurological deficits due to global ischemia secondary to cardiac arrest or because of the surgical procedure. He was discharged after 4 days and started to work after 5 months.

We assessed the patient 10 months after the operation. He said there was no backache or backache. The lateral Cobb angle between the T3-T12 vertebrae was found to be 78 degrees (**Figure-1**).

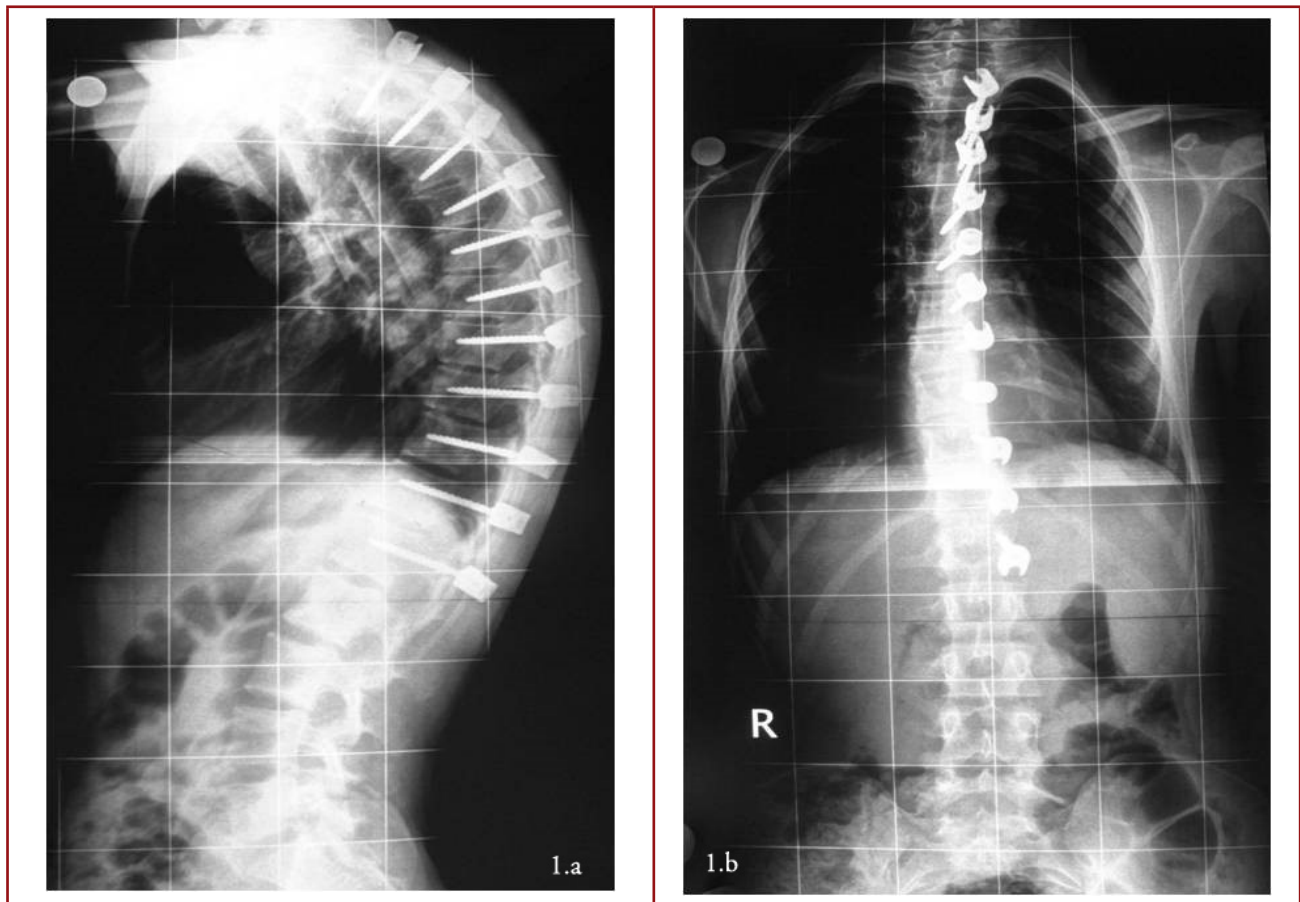


Figure-1. a. Postoperative lateral radiographic image. **b.** Postoperative AP radiographic image

DISCUSSION

A large number of studies have been reported involving large, multi-center and large number of patients with perioperative cardiac arrest development. The incidence of perioperative cardiac arrest in these studies has been reported at a range of 4.6 / 10000-19,7 / 10000⁽⁸⁻¹⁰⁾.

Sprung et al. is stated that perioperative cardiac arrest is not related to anesthesia in most of the cardiac arrest events⁽¹⁰⁾. The most common etiology of perioperative cardiac arrest associated with anesthesia is neuromuscular blocker drugs. It has been asserted that neuromuscular blockers also cause cardiac arrest by causing hypoxia or causing drug-induced asystole⁽¹⁰⁾. According to this study, the prognosis after cardiac arrest was not related to age⁽¹⁰⁾. In the same study, it was also reported that it is associated with poor prognosis if accompanied by asystole with cardiac arrest. However, when an asystole cardiac arrest associated with anesthesia occurs, it is reported to have a better prognosis⁽¹⁰⁾.

Newland C et al. found that about 10 % of cardiac arrest was associated with anesthesia in a large series of studies, they also found that 40 % of these anesthesia related cardiac arrest event were caused by drugs, 20 % of these by central venous interventions, 20 % by sinusoidal airway problems, 13 % by vagal reflex and unknown causes and 7 % of these by myocardial infarction⁽⁸⁾. In the same study, perioperative cardiac arrest was most commonly reported to occur at the operations, which are performed under general anesthesia.

Morgan et al. presented in their study that the most important cause of anesthesia-related cardiac arrest development is perioperative drug use. Other causes are vagal stimulation, hypoventilation, bleeding, and anaphylaxis⁽⁶⁾. These results support Newland et al. Since there are very few studies published in the field of orthopedic and spinal surgery related to the development of perioperative cardiac arrest, most of our literature searches were from sources related to anesthesia. Because the studies we have included in the article are extensive studies involving a large number of centers with a large patient population, the results they have concluded become a guide for us. As noted in most studies, we did not entirely blame the factors related to anesthesia for the development of cardiac arrest. Massive transfusion and / or hyperkalemia secondary to hemolysis are held responsible for asystole cardiac arrest development in our study. The cause of hemolysis was not clear.

One of the most important points in our study was that the patient responded to resuscitation 45 minutes after the onset of cardiopulmonary arrest. Although anesthesia and reanimation specialists mentions that the long duration of resuscitation may lead to brain death or neurological damage, knowing that patients return to life without any neurological sequelae will be used as a beneficial experience for surgeons dealing with spinal surgery.

REFERENCES

1. Glassman SD, Hamill CL, Bridwell KH, Schwab FJ, Dimar JR, Lowe TG. The impact of perioperative complications on clinical outcome in adult deformity surgery. *Spine* 2007; 32(24): 2764-2770.
2. Hu SS, Berven SH. Preparing the adult deformity patients for spinal surgery. *Spine* 2006; 31(19 Suppl): 5126-5131.
3. Keenan RL, Boyan CP. Cardiac arrest due to anesthesia: a study of incidence and causes. *JAMA* 1985; 253(16): 2373-2377.
4. Lagasse RS. Anesthesia Safety: Model or myth? A review of the published literature and analysis of current original data. *Anesthesiology* 2002; 97(6): 1609-1617.
5. Lunn JN, Devlin HB. Lessons from the confidential enquiry into perioperative deaths in three NHS regions. *Lancet* 1987; 2(8572): 1384-1386.
6. Morgan CA, Webb RK, Cockings R, Williamson JA. The Australian Incident Monitoring Study. Cardiac arrest: an analysis of 2000 incident reports. *Anaesth Intensive Care* 1993; 21(5): 626-637.
7. Marray JP, Geiduschek JM, Ramamoorthy C, Haberkern CM, Hackel A, Caplan RA, Domino KB, Posner K, Cheney FW. Anesthesia-related cardiac arrest in children: Initial Findings of the Pediatric Perioperative Cardiac Arrest (POCA) Registry. *Anesthesiology* 2000; 93(1): 6-14.
8. Newland MC, Ellis SJ, Lydiatt CA, Peters KR, Tinker JH, Romberger DJ, Ullrich FA, Andreson JR. Anesthetic-related cardiac arrest and its mortality: A report covering 72,959 anesthetics over 10 years from a US teaching hospital. *Anesthesiology* 2002; 97(1): 108-115.
9. Quinn TD, Brovman EY, Aglio LS, Urman RD. Factors associated with an increased risk of perioperative cardiac arrest in emergent and elective craniotomy and spine surgery. *Clinical Neurology and Neurosurgery* 2017; 161: 6-13.
10. Sprung J, Warner ME, Contreras MG, Schroeder DR, Beighley CM, Wilson GA, Warner DO. Predictors of survival following cardiac arrest in patients undergoing noncardiac surgery: a study of 518,294 patients at a tertiary referral center. *Anesthesiology* 2003; 99(2): 259-269.