



EFFECT OF PROPOLIS APPLICATION ON POSTLAMINECTOMY FIBROSIS: AN EXPERIMENTAL STUDY

LAMİNEKTOMİ SONRASI EPİDURAL FİBROZİS GELİŞİMİNİ ÖNLEMEDE PROPOLİSİN ETKİSİ: DENEYSEL ÇALIŞMA

Ömür GÜNALDI¹,
A. Ender OFLUOĞLU¹,
Lütfi Ş. POSTALCI¹,
Şeyda ERDOĞAN²,
Bekir TUĞCU¹,
Barış ÇÖLLÜOĞLU³,
Erhan EMEL³

¹Bakırköy Mental Health and Neurological Diseases Education and Research Hospital, Department of Neurosurgery, Bakırköy, İstanbul.

²Çukurova University Faculty of Medicine, Department of Pathology, Sarıçam, Adana

³Private Rumeli Hospital, Department of Neurosurgery, Sefaköy, İstanbul

Address: Ömür GÜNALDI,
Halkalı merkez mahallesi, İkitelli
caddesi, İhlamurevleri B3 blok, Kat
3 No:15
Küçükçekmece/İstanbul
Tel.: 0505 2342666,
E-mail: omurgunaldi@gmail.com
Received: 4th May, 2013
Accepted: 20th June, 2013

SUMMARY

History: The development of epidural fibrosis is one of the most significant causes of failed back surgery syndrome. Many methods and substances have been used to prevent the development of post-laminectomy epidural fibrosis. Propolis is not only known to have positive effects on human health and regulatory properties, it also has accelerating and regulatory effects on wound healing.

Objective: This study experimentally evaluated the effects of propolis on the degree of epidural fibrosis after laminectomy in rats.

Materials and Methods: The subjects were separated into two groups: for group 1 (n=8), the control group, L1 laminectomy was performed, and for group 2 (n=8), the treatment group, L1 laminectomy with the application of propolis to the operation area was performed. The related vertebral columns were removed as a block after six weeks, and 6 mm sections were cut in paraffin blocks.

Results: In group 2, a lower rate of epidural fibrosis developed, according to the degree of scar tissue, than in group 1. The difference was statistically significant (p<0.05). When staging was done according to the number of fibroblasts, in group 2 a low grade of epidural fibrosis was determined, and the difference was statistically significant (p<0.05).

Conclusion: Many methods and substances have been used to prevent the development of post-laminectomy epidural fibrosis. Although there are many studies that have pointed out the beneficial effects of propolis on wound healing, this has never been used in neurosurgical practice. According to the results of this study, propolis reduces the development of post-laminectomy epidural fibrosis in rats. The standard formation of the gel must subsequently be tested in human studies.

Key words: Peridural, epidural, fibrosis, laminectomy, propolis

Level of evidence: Prospective experimental study, Level II

ÖZET

Geçmiş bilgiler: Başarısız bel cerrahisi sendromunun en önemli sebeplerinden biri epidural fibrosis gelişimidir. Laminektomi sonrası epidural fibrosis gelişimini engellemeye yönelik pek çok yöntem ve madde kullanılmıştır. İnsan sağlığına olumlu etkileri olduğu bilinen propolisin yara iyileşmesini hızlandırıcı ve düzenleyici özelliği vardır.

Amaç: Bu çalışmada, propolisin deneysel olarak laminektomi sonrası epidural fibrosis derecesine etkisi sıçanlarda değerlendirildi.

Materyal metod: Denekler iki gruba ayrıldı: Grup-1 (n=8) (Kontrol grubu); L1 seviyesine sadece laminektomi yapıldı, grup 2 (n=8) (Tedavi grubu); L1 laminektomi yapılarak, laminektomi sahasına propolis uygulandı. İlgili vertebral kolonlar 6 hafta sonra blok olarak çıkarıldı. Parafin bloklardan 6 mm kalınlığında seviyeli kesitler alındı.

Bulgular: Skar dokusunun derecesine göre yapılan evrelemede, grup 2'de grup 1'e göre EF'in daha düşük oranda geliştiği gösterildi. Aradaki farkın istatistiksel olarak anlamlı olduğu görüldü (p <0.05). Fibroblast sayısına göre yapılan evrelemede, grup 2'de grup 1'ye göre daha düşük derecede epidural fibrosis geliştiği ve aradaki farkın istatistiksel olarak anlamlı olduğu tespit edildi (p <0.05).

Sonuçlar ve çıkarımlar: Omurga cerrahisi sonrası oluşan epidural fibrosis önlemek amacıyla günümüze kadar birçok çalışma yapılmış ve bir çok madde kullanılmıştır. Propolisin, yara iyileşmesinde yararlı etkileri birçok çalışmada gösterilmiştir. Laminektomi sonrası epidural fibrosis gelişiminde ve diğer nöroşirüjik prosedürleri içeren çalışmalarda propolis hiç kullanılmamıştır. Çalışmamızın sonuçlarına göre propolis, sıçanlarda laminektomi sonrası epidural fibrosis gelişimini azaltmaktadır. Propolisin laminektomi sonrası insan çalışmalarında kullanılabilmesi için, standart jel formu oluşturulmalıdır.

Anahtar kelimeler: Peridural, epidural fibrozis, laminektomi, propolis

Kanıt Düzeyi: Prospektif deneysel çalışma, Düzey II

INTRODUCTION

Failed low back surgery syndrome (FLBSS) after lumbar disc hernia surgery has been reported in the literature with an incidence of 5–40% (5-6,9,23). One of the most important causes of FLBSS is the development of epidural fibrosis (EF). 24% of patients develop FLBSS due to adhesion, stretching and compression effects of EF on nerve roots in the laminectomy region¹⁷. Although many substances and methods have previously been used to prevent post-laminectomy EF, these applications have not been greatly clinically accepted.

Propolis is a chemical mixture that is produced by honey bees, and includes flavonoids that regulate the immune system during wound healing¹⁸. Studies have shown that propolis has anti-inflammatory effects, accelerates wound healing, and prevents the formation of scar tissue, particularly due to the flavonoids found in its structure^{8,22}.

In this study, it is investigated whether propolis had a preventive effect on EF development as a result of poor wound healing in a post-laminectomy EF model.

MATERIALS AND METHODS

The study was performed with the permission of the twentieth Local Ethics Committee for Animal Experiments at the Medical School of Çukurova University, held on 19.06.2012. In this study, propolis produced by the *Leptospermum scoparium* species of honey bees sourced from New Zealand and found in the Taurus Mountains was used in the study.

In the study, a total of 16 Wistar Albino rats were used, aged 10–12 weeks old and weighing 200–250 g.

SURGICAL PROCEDURE

Thirty minutes prior to surgery, one dose of 50 mg/kg ceftriaxone (Rocephine, Roche, Turkey) was injected intraperitoneally as prophylaxis. General anesthesia with 60 mg/kg of intraperitoneal ketamine

hydrochloride (Ketalar, Parke-Davis, Eczacıbaşı, Istanbul) and 10 mg/kg of xylazine hydrochloride (Rompun) were applied. After stabilization of the rat on the operating table, the operation area was brushed for 10 minutes with povidone iodine scrub (using a MEDICA brush and 4% chlorhexidine soap, MEDICA BV, Holland), and disinfection was applied with povidone iodine solution (POVIDO; 10% polyvinylpyrrolidone-iodine complex, Saba, Turkey). The surgical area was covered with a sterile coating. The L1 level was detected. Then an approximately 3 cm skin incision was performed over the spinous processes at the midline. The para-spinous muscles were skimmed with blunt dissection and laminectomy was performed. The subjects were separated into two groups: for group 1 (n=8, control group), L1 laminectomy was carried out, and for group 2 (n=8, treatment group), L1 laminectomy plus propolis to the operation area was performed. After the subjects were kept alive for six weeks, they were sacrificed with a high dose (75–100 mg/kg) of intraperitoneal sodium thiopental (Pentothal Sodium, Abbott, Italy). The relevant vertebral columns were removed as a block. During surgery, the rats with a rupture in the dura, injury in the nerve root, postoperative neurological deficit and injection during decapitation were excluded, and replaced with new rats. The amount of fibrosis in the laminectomy region and the relationship with the dura mater were evaluated, by comparison of the treatment group and the control group, in conformity with the histological criteria and classification defined in the literature, and the results were compared statistically.

HISTOPATHOLOGICAL REVIEW

The vertebral column removed as a block was fixed in 10% buffered formalin and decalcified for two days (10% formic acid). After completion of decalcification, a sample was taken from the area that received laminectomy, and the samples were processed with routine tissue tracking using an autotechnicon after being washed under running

water for six hours. Sections 6 mm thick were cut in paraffin blocks and stained with haematoxylin and eosin stain. Each specimen was evaluated by a pathologist by light microscopy in terms of the EF prevalence, cell density and arachnoid fibrosis. EF was evaluated as stated by He et al. (Table-1)¹⁴. The prevalence of fibrosis was evaluated in each preparation.

Table-1. Grading criteria for the scar tissue in the histological evaluation of scar tissue²⁹

Grade	Width of the scar tissue
0	No scar tissue in dura mater
1	Thin fibrous bands are present between scar tissue and dura mater
2	Adhesions holding less than 2/3 of laminectomy defect are present
3	Common scar. More than 2/3 laminectomy defect is affected

Table-2. Grading according to fibroblast number

Grade	Mean fibroblast number (40x)
1	<100
2	100-150
3	>150

Table-3. Fibrosis degrees of the rats in control and treatment groups

No	Grade acc. to Table-1		Grade acc. to Table-2	
	Group 1	Group 2	Group 1	Group 2
1	2	1	2	1
2	3	1	3	2
3	3	2	2	1
4	2	1	3	1
5	3	2	3	1
6	3	0	3	1
7	3	1	3	1
8	3	2	3	2

The scar tissue cell density was evaluated as stated by He et al. and Hinton et al.^{14,15}. Fibroblasts were

counted at 40× magnification by a pathologist. This process was performed for three areas of each specimen, including one middle area and two laminectomy edges. The mean fibroblast number for these three areas was graded as in Table-2.

Similarly, the inflammatory cell density was evaluated at 40×. Moreover, the presence of bone renewal, wrapping of the nerve root with scar tissue, and adhesion between the dura and arachnoid was examined. It was observed that less inflammation developed in the group treated with honey than the control group.

STATISTICAL EVALUATION

The data was evaluated in the SPSS 15.0 packet program. The EF prevalence, cell density and arachnoid involvement between the groups were evaluated with the chi-square test. P-values less than 0.05 were accepted as statistically significant.

RESULTS

The grades of each rat in the control and treatment groups were separately revealed according to the scar tissue level and fibroblast number determined by a pathologist (Table-3). In both grading systems, while the EF level of all rats in group 2 was 2 or lower, it was 2 or more in group 1.

By light microscopy evaluation, greater EF thickness, inflammatory cell density and arachnoid adhesions were seen in group 1 than group 2 (Figure-1,2).

When grading according to scar tissue degree, for group 1, there was no grade 0 or 1 EF, 25% of the subjects had grade 2 and 75% had grade 3. No grade 3 EF was observed in group 2. 37.5% had grade 2 and 62.5% had grade 1 and grade 0 fibrosis (Table 4). This shows that the rate of EF development was lower in group 1 than group 2. The difference was statistically significant ($p < 0.05$).

Table-4. The number of rats of each grade when grading according to scar tissue degree

Group	Grade 0	Grade 1	Grade 2	Grade 3
Group 1	0 (0%)	0 (0%)	2 (25%)	6 (75%)
Group 2	1 (12.5%)	4 (50%)	3 (37.5%)	0 (0%)
P	0.011			

Table-5. The number of rats of each grade when grading according to fibroblast number

Group	Grade 0	Grade 1	Grade 2	Grade 3
Group 1	(0%) 0	(0%) 0	(25%) 2	(75%) 6
Group 2	(0%) 0	(75%) 6	(25%) 2	(0%) 0
P	0.002			

When grading according to fibroblast number, while there was no EF of grade 0 or 1 seen in group 1, 25% of the subjects had grade 2 and 75% had grade 3. In group 2, there was no grade 0 or grade 3 EF. 75% of the subjects had grade 1 and 25% had grade 2 EF (Table 5). According to this grading system, a lower degree of EF developed in group 2 than group 1, and the difference was statistically significant ($p < 0.05$).

DISCUSSION

One of the most important causes of FLBSS is the development of epidural fibrosis (EF). EF is composed of fibroblasts, collagen produced by fibroblasts, and cellular elements including inflammatory cells. Nerve withdrawal or compression effects occur due to contraction of adhesions caused by scar formation wrapping the nerve. These adhesions can disrupt axoplasmic transportation, arterial supply and venous drainage^{4,11,24,27}. The wound healing process is grouped into three stages: inflammation, proliferation, and remodeling^{1,2}. Collagen fiber

production, resulting in granulation tissue formation, is activated from factors produced in the inflammatory phase, fibroblasts and endothelial cells¹². The accumulation and maturation of collagen fibers in the granulation tissue matrix results in scar tissue formation^{10,21}. Propolis is a chemical mixture that is produced by *Apis mellifera* honey bees, and includes flavonoids regulating the immune system during wound healing¹⁸.

Previously, many studies have been performed and many substances have been used to prevent EF occurring after spine surgery. For that purpose, solid barriers such as fatty grafts, polyvinyl alcohol, hydrogel membranes, polytetrafluoroethylene membranes, polylactic acid membranes and vicryl mesh, viscous solutions such as sodium hyaluronate, fibrinolytic agents such as gel recombinant tissue plasminogen activator urokinase, hemostatic agents such as gelatin sponges and microfibrillar collagen, anti-inflammatory agents such as methylprednisolone, triamcinolone, prednisolone, ketoprofenin and dexamethasone, and antineoplastic and immune suppressors such as cisplatin, temazolamide and bevasizumab, have been used^{3,13,16,25,26}. Although the use of these substances has been shown successfully in animal models, it has not been observed that they provide a decrease in the occurrence of EF with clinical healing, and they have not taken a place in routine practice.

Propolis includes more than 200 substances in varying ratios, such as polyphenols, terpenoids, steroids, sugars and amino acids, benzoic acid, flavonoids and cinnamic acid, according to the geographic and seasonal conditions^{20,28}.

In many studies, the biological activity and safety of propolis have been revealed, and its use in live tissue has been demonstrated⁷. Propolis is used by honey bees to prepare an aseptic environment in the beehive and to protect the eggs of the queen bee¹⁹. Studies have shown that propolis has anti-inflammatory effects, accelerates wound healing and

prevents scar tissue, particularly due to flavonoids found in its structure²².

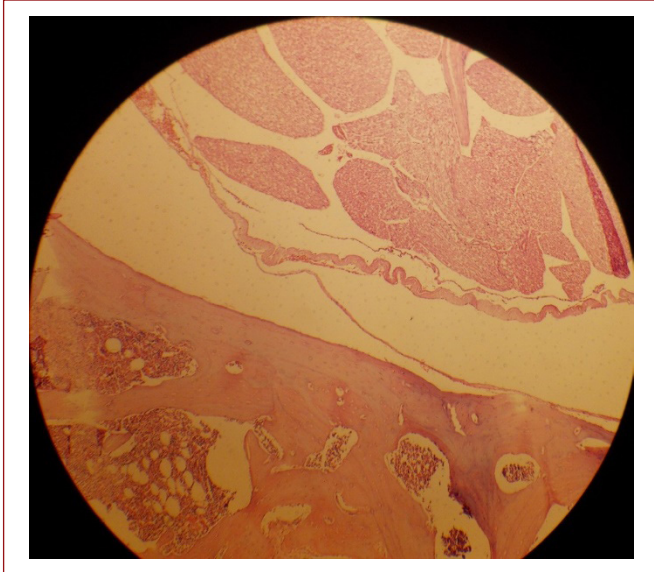


Figure-1. Grade III fibrosis in a spine section of the control group under light microscopy. Epidural fibrosis is directly adhered to the dura mater (HE×100).

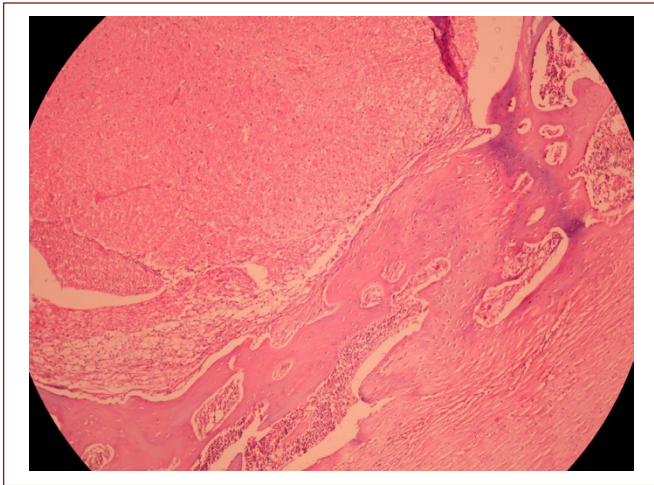


Figure-2. Grade I fibrosis in a spine section of the control group under light microscopy. No direct adhesion of epidural fibrosis to the dura mater can be seen (HE×100).

Despite these useful effects of propolis, there are some significant problems with its application.

The most important problem is that propolis is a solid. In order to be applied to a laminectomy region,

propolis should be a spreadable gel. In addition, the active substances in propolis are closely related to the geographical conditions and flora of the honey bees. In this study, solid propolis produced in the Taurus Mountains was powdered and mixed with honey produced in the same region, and not subjected to any intervention in order to become gel-like. Although the study was standardized in terms of the propolis and honey ratio, the production of both propolis and honey in standard conditions is required, to determine the active substances in propolis and to define a standard mixture ratio. Moreover, the effect of the mixture on EF and the effect of honey on EF should be compared, and how and at which ratios honey changes the effect of the mixture on EF should be determined.

The statistical results showed that the application of propolis to rats after laminectomy significantly reduced the degree of epidural fibrosis. We think that further studies can be performed on humans, due to previous use of propolis on humans that showed no harmful effects.

REFERENCES

1. Abreu AM, Oliveira DW, Marinho SA, Lima NL, de Miranda JL, Verli FD. Effect of topical application of different substances on fibroplasia in cutaneous surgical wounds. *ISRN Dermatol* 2012; 2012:282973.
2. Aukhil I. Biology of wound healing. *Periodontology* 2000; 22:(1): 44–50.
3. Aydincak O, Yilmaz MB, Emmez H, Kurt G, Sepici A, Memis L, Baykaner K. The effect of temozolomide on the prevention of epidural fibrosis developing after lumbar laminectomy in rats. *Turk Neurosurg* 2012; 22(6): 706–711.
4. Bartynski W, Petropoulou K. The MR imaging features and clinical correlates in low back pain-related syndromes. *Magn Reson Imaging Clin N Am* 2007; 15: 137–154.
5. Burton CV, Kirkaldy-Willis WH, Yong-Hing K, Heithoff KB. Causes of failure of surgery on the lumbar spine. *Clin Orthop Relat Res* 1981; 191-199.

6. Choi HJ, Kim KB, Kwon YM. Effect of amniotic membrane to reduce post-laminectomy epidural adhesion on a rat model. *J Korean Neurosurg Soc* 2011; 49(6): 323-328.
7. de Barros MP, Sousa JPB, Bastos JK, de Andrade SF. Effect of Brazilian green propolis on experimental gastric ulcers in rats. *J Ethnopharmacology* 2007; 110(3): 567-571.
8. de Moura SA, Negri G, Salatino A, Lima LD, Dourado LP, Mendes JB, Andrade SP, Ferreira MA, Cara DC. Aqueous extract of Brazilian green propolis: primary components, evaluation of inflammation and wound healing by using subcutaneous implanted sponges. *Evid Based Complement Alternat Med* 2011; 2011: 748283.
9. Fager CA, Freidberg SR. Analysis of failures and poor results of lumbar spine surgery. *Spine* 1980; 5: 87- 94.
10. Follonier L, Schaub S, Meister JJ, Hinz B. Myofibroblast communication is controlled by intercellular mechanical coupling. *J Cell Sci* 2008; 20: 3305- 3316.
11. Gill GG, Scheck M, Kelley ET. Pedicle fat grafts for the prevention of scar in low-back surgery: a preliminary report on the first 92 cases. *Spine* 1985; 10: 662-667.
12. Greiling D, Clark RAF. Fibronectin provides a conduit for fibroblast transmigration from collagenous stroma into fibrin cloth provisional matrix. *J Cell Sci* 1997; 110 (7): 861-870.
13. Haktan K, Hatice OA, Selim T. Broken racz catheter during application (case report). *Agri* 2006; 18(1): 33-36.
14. He Y, Revel M, Loty BA. Quantitative model of post-laminectomy scar formation. Effects of a nonsteroidal anti-inflammatory drug. *Spine* 1995; 20(5): 557-563.
15. Hinton JL Jr, Warejcka DJ, Mei Y, McLendon RE, Laurencin C, Lucas PA, Robinson JS Jr. Inhibition of epidural scar formation after lumbar laminectomy in the rat. *Spine* 1995; 1;20(5):564-70.90
16. Karatay M, Erdem Y, Koktekir E, Erkoç YS, Caydere M, Bayar MA. The effect of bevacizumab on spinal epidural fibrosis in a post-laminectomy rat model. *Türk Neurosurg* 2012; 22(6): 753-757.
17. Kasimcan MO, Bakar B, Aktaş S, Alhan A, Yılmaz M. Effectiveness of the biophysical barriers on the peridural fibrosis of a post-laminectomy rat model: an experimental research. *Injury* 2011; 42(8): 778-781.
18. Kilicoglu SS, Kilicoglu B, Erdemli E. Ultrastructural view of colon anastomosis under propolis effect by transmission electron microscopy. *World J Gastroenterology* 2008; 14(30): 4763-4770.
19. Matsuno T, Jung SK, Matsumoto Y, Saito M, Morikawa J. Preferential cytotoxicity to tumor cells of 3,5- diprenyl-4-hydroxycinnamic acid (artepillin C) isolated from propolis. *Anticancer Research* 1997; 17 (5): 3565-3568.
20. Medana C, Carbone F, Aigotti R, Appendino G, and Baiocchi C. Selective analysis of phenolic compounds in propolis by HPLC-MS/MS. *Phytochemical Analysis* 2008; 19(1): 32-39.
21. Moura SA, Ferreira MA, Andrade SP, Reis ML, Noviello MD, Cara DC. Brazilian green propolis inhibits inflammatory angiogenesis in a murine sponge model, Evidence-Based Compl Alter Med 2011;182703:7.
22. Nakajima Y, Shimazawa M, Mishima S, Hara H. Water extract of propolis and its main constituents, caffeoylquinic acid derivatives, exert neuroprotective effects via antioxidant actions. *Life Sciences* 2007; 80(4): 370-377.
23. North RB, Campbell JN, James CS, Conover- Walker MK, Wang H, Pi-antadosi S. Failed back surgery syndrome : 5-year follow-up in 102 patients undergoing repeated operation. *Neurosurgery* 1991; 28: 685-690.
24. Robertson JT. Role of peridural fibrosis in the failed back: a review. *Eur Spine J* 1996; 5(1): S2-6.
25. Savran M, Bekar A, Cansev M, Tolunay S, Ulus IH, Taskapilioglu MO. Prevention of epidural fibrosis in rats by local or systemic administration of citicoline. *Türk Neurosurg* 2012; 22(5): 634-640.
26. Sehime GT, Ozturk C, Temiz A, Ersozlu A, Aydinli A. A new material for prevention of epidural fibrosis after laminectomy. *J Spinal Disord Tech* 2006; 19: 270-275.
27. Sizer PS, Phelps V, Dedrick G, Matthijs O. Differential diagnosis and management of spinal nerve root-related pain. *Pain Pract* 2002; 2: 98-121.
28. Zhou J, Li Y, Zhao J, Xue X, Wu L, Chen F. Geographical traceability of propolis by high-performance liquid-chromatography fingerprints, *Food Chemistry* 2008; 108(2): 749-759.