



THE HISTORY OF MINIMALLY INVASIVE SPINAL SURGERY

MINİMAL GİRİŞİMSSEL OMURGA CERRAHİSİNİN TARİHÇESİ

Mehmet ŞİMŞEK¹,
Sait NADERİ²

¹Neurosurgery Specialist, Ümraniye Training and Research Hospital, Neurosurgery Clinic, İstanbul
²Prof. Dr, Neurosurgery Specialist, Ümraniye Training and Research Hospital, Neurosurgery Clinic, İstanbul

SUMMARY

Spine procedures began to be widespread in the second half of the 19th century. With time, and in parallel to technological advancements, new and more complex spinal procedures were performed. Technological advancements have allowed the development of minimally invasive spine surgery in the last 30 years. In this study, the history of minimally invasive spine surgery is reviewed.

Key words: Minimally invasive spine surgery, spine, spine surgery

Level of evidence: Historical article, Level V

ÖZET

19. yüzyılın 2. yarısından itibaren omurga ameliyatları yaygınlaşmıştır. Teknolojinin gelişimine paralel olarak giderek daha kompleks uygulamalar da yapılmaya başlanmıştır. Son 30 yıldaki teknolojik ilerlemeler minimal girişimsel omurga cerrahi tekniklerinin önünü açmıştır. Bu makalede minimal girişimsel omurga cerrahinin tarihi gelişimi gözden geçirilmiştir.

Anahtar sözcük: Minimal girişimsel omurga cerrahi, omurga, omurga cerrahi.

Kanıt Düzeyi: Tarihçe, Düzey V

Address: Prof. Dr. Sait Naderi,
Neurosurgery Specialist, Ümraniye
Training and Research Hospital,
Neurosurgery Clinic, İstanbul
Tel.: 0532 2621318
E-mail: saitnaderi@yahoo.com
Received: 1st January, 2013
Accepted: 30th March, 2013

INTRODUCTION

The human spine is the most important part of the skeletal system, and this bone structure perfectly provides balance, absorbs load, and protects the spinal cord. Surgical disruption of this structure can result in severe instability. With the aim of providing the least damage to the integrity of this structure, consisting of bone, joints and nerves, minimally invasive instruments and engineering have been developed over the years.

For years, every newly defined minimally invasive surgical process has been compared with classical open surgery. Sometimes no favorable outcome could be obtained or no difference was found, but some minimally invasive surgical processes have provided extreme comfort and given better results.

From ancient times to the twentieth century, many physicians and surgeons have recorded their own experiences and background, and have contributed to the development of spine surgery.

CERVICAL REGION

The development of cervical minimally invasive techniques proceeded more slowly than for other minimal approaches, because surgery of this part of the spine poses the greatest risks. This is also due to spondylosis, and whether an anterior or posterior approach is used for disc surgery.

The first endoscopic procedures began to be defined in the 21st century, due to more soft tissue and bone resection, a long hospitalization period, and high postoperative pain^{17,62}. The first minimally invasive surgery was performed with odontoid screwing by Horgan in 1999³³. The first minimally invasive posterior laminoforaminotomy with tubular retractors was conducted in cadavers by Roh in 2000⁷², and in clinics by Adamson in 2001¹. Anterior minimally invasive surgery was performed with minimal tubular retractors by endoscopic methods in 2008 by Ruetten et al.⁷⁴. In the same year, cervical nucleoplasty with percutaneous methods was reported in cadavers by Li et al.⁵⁰. Lateral mass screwing was first performed as posterior cervical instrumentation with minimal approach techniques by Wang et al.⁸⁶.

In 1982, Tsuji defined the first open laminoplasty in a patient with myelopathy⁸¹. The application of laminoplasty by minimally invasive methods began with application to cadavers in 2003 by Wang⁸⁶, and with clinical application in 2004 by Perez-Cruet⁶⁷.

A. Endoscopic Transoral Surgery:

In 1962, Fang and Ong reported the results of microscopic transoral decompression in patients with atlantoaxial anomalies¹⁸. In 1989, Hadley et al. published upper cervical decompression using the same technique in a clinical series with 53 patients²⁷. The use of microscopy has increased the safety and reliability of this operation and decreased morbidity. However, due to the distance between the working area and lens, and the narrow transoral area, Frampong-Boadu et al. published a clinical series with seven patients who received endoscopic surgery by a transoral route in 2002²⁴.

In 2000, Tong et al. applied transoral vertebroplasty to a patient with an upper cervical compression fracture⁸⁰. In the present day, Leng et al. treated os odontoideum by an endonasal technique for the first time in 2009⁴⁹.

B. Cervical Microendoscopic Posterior Approach:

Initially, although posterior cervical disc surgery was the first method defined, anterior cervical surgery has become more popular over time. This has maintained efficacy for certain patients, including those with no lateral hernia disc fragments, isolated foraminal stenosis, central stenosis with continuous root pain after anterior surgery, and multiple foraminal stenosis. However, the paraspinal muscle spasm pain complaint with this surgery is greater, due to a great deal of muscle dissection.

The microendoscopic discectomy (MED) system has been developed to minimize muscle spasm pain and soft tissue trauma, and to provide postoperative comfort. Complication ratios similar to open discectomy have been reported. In a clinical series in which Roh et al. performed open surgery and MED in 2000, they obtained equal results for root symptoms and facet movement, and better results using MED in cadavers⁷². Muscle dilatation with endoscopic tubular canal minimized postoperative pain. Similar excellent results were also reported in the first clinical studies, including a study by Adamson and Fessler, and a series by Khoo in 2002^{1,21,44}.

In posterior cervical instrumentation, minimally invasive surgery was defined for the first time by Wong et al. in 2000^{54,90}. In applications with cervical instrumentation, minimally invasive approaches with microendoscopy and video have been developed and published within the last five years^{86,87}.

THORACIC REGION

A. Thoracoscopic Spine Surgery:

Jacobaeus defined the first thoracoscopic procedure in Stockholm, Sweden, in 1910³⁶. He performed this first approach using cystoscopy and a platinum loop for pleural adhesion caused by tuberculosis in an internist. In the 1990s, the first modern thoracoscopy approach began with standard endoscopy after video imaging (Figure-1). Regan et al. (ABD) and Rosenthal et al. (Europe)⁷³ reported the first video thoracoscopic surgery techniques, in 1993 and 1994, respectively.

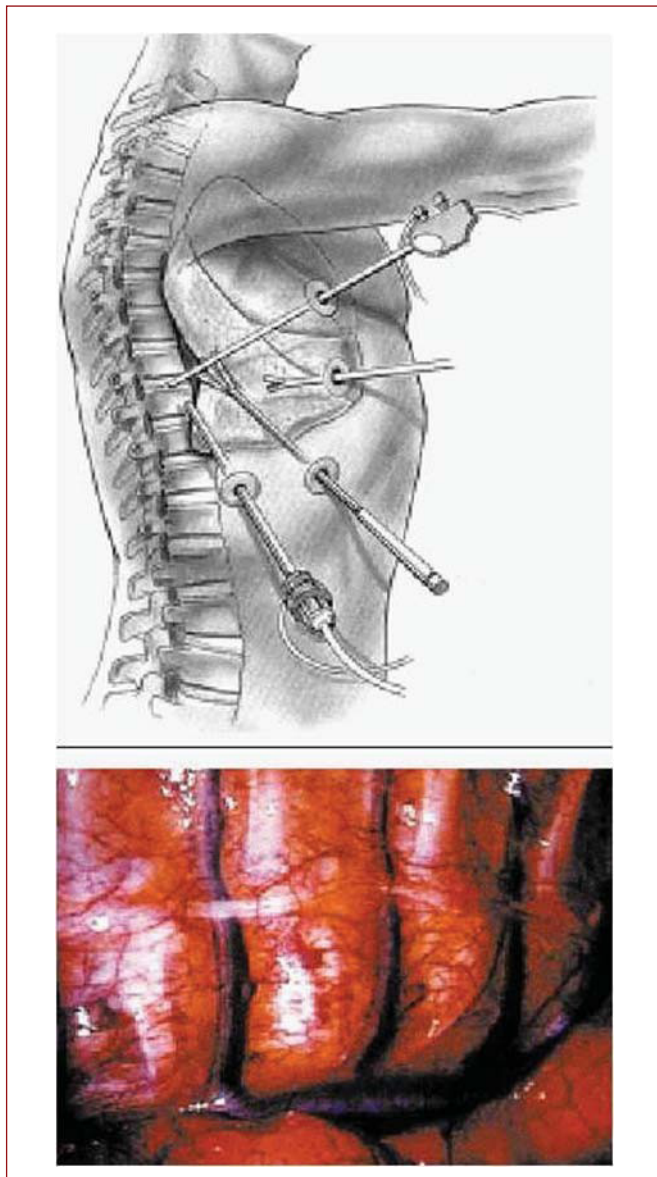


Figure-1. An image from thoracoscopic spine surgery

Thoracoscopic surgical procedures were used for thoracic disc hernias, thoracic sympathectomies, vertebral pathologies, abscess drainage, and tumor biopsies. In the years following, they have been used for scoliosis correction, anterior interbody fusion, osteotomies, corpectomy, and tumor and vertebral instrument applications after fracture.

Thoracic disc hernia surgery was reported for the first time by Benjamin in 1983⁶. The first minimally invasive thoracic discectomy with minimally invasive tubular retractors was performed in cadavers in 1994 by Horowitz³⁴. The first clinical surgery was performed by Rosenthal in the same year⁷³, followed by Jho in 1999⁴⁰. However, the morbidity of the minimally invasive approaches defined and performed in these years was found to be higher than for open approaches (thoracotomy costotransversectomy, far-lateral extracavitary approaches). In 2005, less morbidity was reported for thoracic discectomy with the use of a minimally invasive tubular retractor performed by Lidar et al.⁵². Midline or lateral positioning and disc calcification have been decisive for minimally invasive surgery.

The first applications of minimally invasive thoracic pedicular screws led to morbid consequences. The minimally invasive approach used a thin pedicle with an improper choice of positioning resulting in spinal cord damage and neurological loss, could not remove instability in extrapedicular applications, and was not sufficient. After 2008, a minimally invasive thoracic pedicle approach has been successfully performed using CT-guided cannulated screws^{57,77}. In the same year, placement of a percutaneous rod to these screws, as defined by Sextant, further improved the system. In 2008, Anand et al. performed scoliosis surgical treatment using this CT-guided minimally invasive system for the first time³. For chance-type fractures, this percutaneous system provides successful treatment. The minimally invasive tubular retractor-guided system used for lumbar stenosis, which will be described in detail later, remains the minimally invasive choice for thoracic decompression surgery.

B. Posterior and Posterolateral Endoscopic Surgery:

This was developed to provide a direct posterior and posterolateral approach for thoracic disc hernias. In 1997, Jho defined the endoscopic transpedicular thoracic discectomy technique using a 4 mm endoscope with 0° and 70°⁴⁰. This method is effective because there is no need for a second incision in the chest for a thoracoscopic approach.

Chiu and Clifford defined safe and effective posterolateral endoscopic thoracic discectomy with a 4 mm endoscope with 0°, in order to minimize a thoracic disc with a low-energy non-ablative laser (laser thermo-discoplasty)¹⁰. The same approach with the METRx (Medtronic Sofamor Danek, Memphis, Tennessee) system was defined in cadavers by Isaacs et al.³⁵, and in the clinic by Perez-Cruet et al.⁶⁶. Similarly, Kin et al. have been performing thoracic corpectomy and reconstruction by a minimally invasive approach in patients with tumors and trauma and in cadavers since 2008⁴⁵.

LUMBAR REGION:

A. Lumbar Microdiscectomy:

In the second half of the 1960s, Yaşargil (Figure-2) attempted to reduce the morbidity risk using microscopy and microsurgery⁹¹. The microsurgery methods developed by Yaşargil provided less bleeding, smaller incisions, good mastery of the pathological area, a low hospitalization period, postoperative comfort and an early return to activity. As a result, minimally invasive spine surgery is provided using microscopy.




Figure-2. Dr. Gazi Yaşargil

In 1968, the use of binocular microscopy was begun in Sachdev lumbar discectomies⁷⁵. After the initial documentation, microdiscectomy procedures were

reported by Yaşargil⁹¹ and Caspar⁹ in 1977, but the worldwide recognition of this technique came about due to a clinical series including 532 patients that was reported by Williams in 1978⁸⁸. In this report, the successful removal of hernia disc fragments alone from the interlaminar window by a microdiscectomy method for show girls in Las Vegas gave popularity to the method. Then, unsuccessful studies using a microdiscectomy technique were asserted. McCulloch defined laminoplasty using these techniques in the 1990s⁵⁶. Contralateral, central and foraminal stenosis could be decompressed with ipsilateral laminectomy. After that, these techniques were improved by developments such as stereotactic lumbar microdiscectomy and microdiscectomy with intraoperative MR.

B. Microendoscopic Discectomy (MED):

The first spine endoscopic approach was performed by defining the myelotomy concept to visualize the spinal cord in 1931 by Burman⁷. In 1938, Pool⁷⁰ improved on Burman's study and reported myeloscopic inspection of the dorsal nerve roots in cauda equina. Pool also defined intradiscal endoscopy. Morbidity with myelotomy is high, because it is performed in the dura cavity using a wide approach. Ooi et al. tried endoscopy of the intrathecal region before surgery, and stated that endoscopy can provide a possibility of understanding pathologies such as arachnoiditis and spinal stenosis⁶¹. In the 1970s, the defined use of microscopy began to be commonly used^{16,56,62}.

The lumbar disc tubular approach was defined for the first time in 1991 by Faubert and Caspar^{9,19}, and led to the improvement of the tubular system and small hand tools. The first microendoscopic discectomy (MED) with tubular retraction was reported by Foley and Smith. The first MED was carried out by Foley and Smith in 1997, and became popular after arthroscopic approaches were learnt rapidly by orthopedists (Figure-3)²². In 2002, the first lumbar stenosis was treated with minimally invasive tubular retractors by Fessler et al.²¹ and Palmer et al.⁶⁴. Adapting the use of microscopy with tubular retractors provided many brain surgeons with the possibility of using these techniques after 2003, and this can be combined with standard microdiscectomy for lateral stenosis and disc hernias with free fragments. MED provides a comfortable postoperative process due to a small incision and less tissue damage, and reduces the hospitalization period.

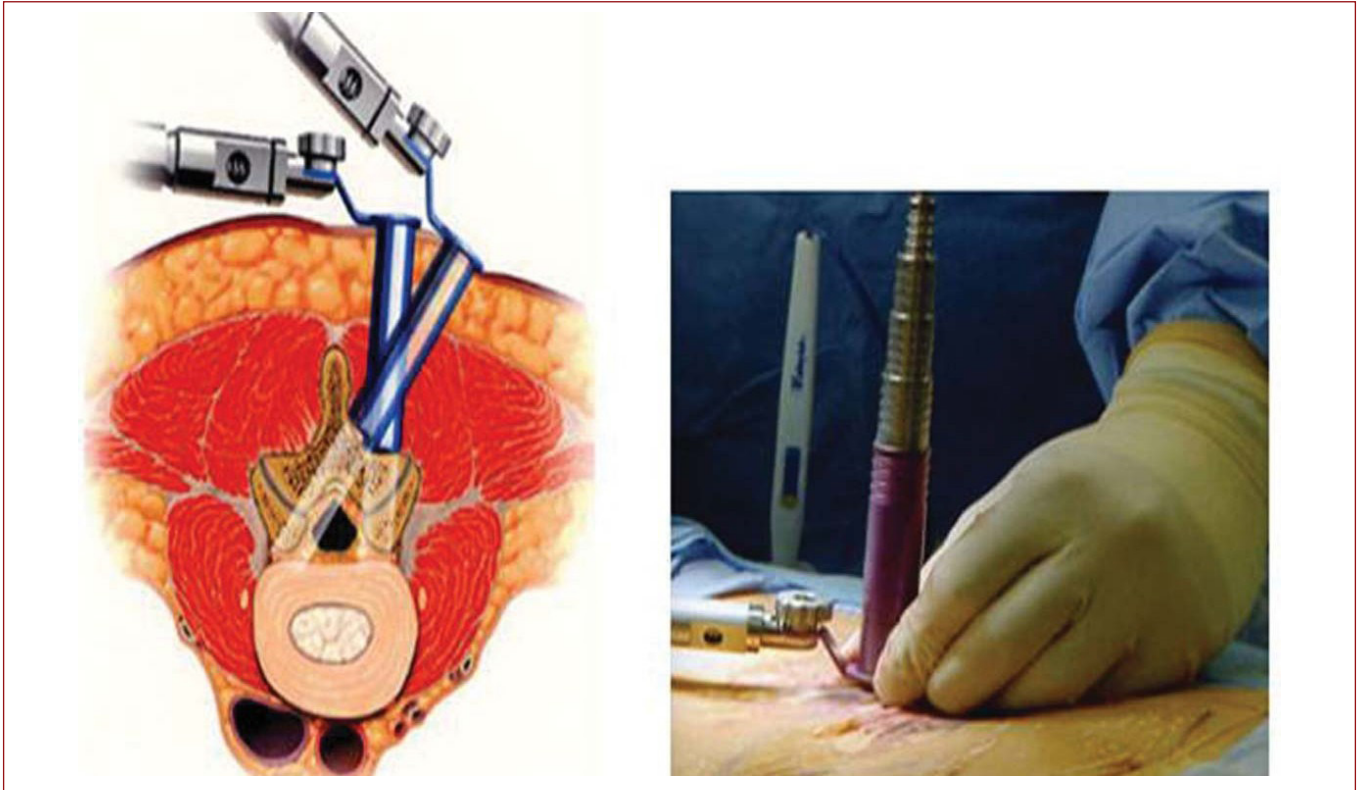


Figure-3. An image from microendoscopic disc surgery.

Guiot et al. applied bilateral decompression in spinal stenosis in cadavers with percutaneous microendoscopy by a unilateral approach²⁶, and Khoo and Fessler⁴³ successfully applied this method in the clinic. The MED method has also been used for lateral disc herniation, synovial cysts, and recurrent disc herniation.

C. Percutaneous Arthroscopic Discectomy:

The first spinal posterolateral and anterior biopsies were performed by Ottolenghi (Argentina) in 1955⁶³ and Cragg¹⁷ in 1956, respectively. In 1975, Hijikata et al. defined percutaneous nucleotomy by removing the disc from posterocentral and paracentral disc hernias using an intradiscal arthroscopic method under local anesthesia³¹. With this technique, entry was performed using a circular incision in the lateral annulus with a 4 mm cannula after discography with Evans blue, and drainage of the blue-stained nucleus pulposus was applied using pituitary forceps. In 1983, Kambin (Figure-4) and Gellman performed discectomy by entering with a Craig cannula after laminectomy⁴¹. In 1985, Onik et al. performed percutaneous discectomy at the L4-5 and upper levels with a 2 mm blunt-type probe in animal experiments, and reported a 75% success rate and a 1% complication rate⁶⁰. Then, the combination of video-discoscopy was

developed over a single portal with a 2-7 mm glass arthroscope. Arthroscopic disc surgery also provided disc removal in a biportal way by a posterolateral approach. In the same year, Maroon published a nucleotomy procedure termed percutaneous lumbar discectomy using a self-developed procedure⁵⁴. Kambin performed the first percutaneous lumbar discectomy guided by fluoroscopy in 1987⁴².

D. Percutaneous Laser Discectomy:

Choy et al. defined percutaneous laser discectomy using the same approach as the arthroscopic percutaneous discectomy procedure¹². Ascher and Heppner defined the first percutaneous laser discectomy for lumbar disc hernia treatment⁵. In their technique, they first measured the intradiscal pressure before the process, and then performed laser discectomy with a saline manometer. The aim was to remove the least amount of disc required to reduce the intradiscal pressure.

E. Chemonucleolysis:

Chemonucleolysis is the hydrolysis of non-collagen proteins, such as chondroitin sulfate and keratin sulfate, found in the nucleus pulposus.

In 1941, this was developed with the kemopapain enzymatic reaction from the papa plant, by Jansen and Balls³⁹. In 1956, Thomas intravenously gave kemopapain to rabbits and recorded tear release⁷⁸. In 1963, Smith et al. injected this for the first time to the nucleus pulposus in a hip treatment⁷⁶. It was detected that this reduced the extracellular fluid amount of the nucleus pulposus by interacting with stored proteoglycan and glycoprotein macromolecules.



Figure-4. Prof. Dr. Parviz Kambin

F. Lumbar Instrumentation and Fusion:

The first spinal instrumentation was performed using a lumbar spinous process wiring operation in a Pott patient by Hadra in 1891²⁸. In 1949, Michele and Krueger defined the first pedicle fixation, and the first percutaneous pedicle screwing was performed with external fixators by Magerl in 1982⁵³. In open surgery, developments regarding the placement of rods and screws after paraspinal muscle retraction have been made with technology.

After a classic midline incision, the deep screw entry site on the far lateral makes instrumentation difficult, and results in ischemic retraction of many retractor muscles, and chronic lower back pain. However, this provides possibilities for decompression, discectomy and interbody applications. Due to complications caused by the midline angle, Wiltse developed an incision between the bilateral muscles in 1988⁸⁹. In 2001, Foley developed the Sextant (Medtronic) system in 2001 from the same

incision, to place a rod minimally²³. The same minimally invasive system was modified to the Mantis (Stryker) percutaneous system in 2007. A percutaneous approach is superior, as this minimizes complications caused by muscle retraction and excess screw pulling of the medial last screw (delta angle).

Percutaneous facet fusion techniques were defined by Jang et al. in 2003³⁷. Chronologically, the ALIF procedure was defined in 1933 by Burns⁸, PLIF in 1952 by Cloward^{13,14}, artificial disc replacement in 1966 by Fernstrom²⁰, and TLIF in 1982 by Harms and Rolinger²⁹. Minimally invasive adaptation of all these interbody fusion techniques began with the publication of anterior laparoscopic discectomy in 1991 by Obenchain^{59,62}. In 1995, Matthews and Zucherman combined ALIF and artificial disc replacement and led the minimally invasive approach⁹³. In 2002, Khoo reported the first minimally invasive PLIF process⁴⁴. In 2006, Holly and Schwender reported a minimally invasive TLIF operation with tubular retractors and obtained better results³². With the definition of percutaneous reduction screws, Park and Foley applied the TLIF procedure to grade 1 and 2 isthmic spondylolisthesis cases with a PEEK cage using this technique in 2008, and stated that it gave better results, similar to the open laminectomy techniques for deformity correction⁶⁵.

More rare fusion approaches have also been defined. One of these is the distant lateral extracavitary transpsoas approach. A direct lateral transpsoas approach, DLIF, was defined in 1997 by Mayer⁵⁵, and improved in 1998 by McAfee and Pimenta⁶⁸. In company with AP and lateral fluoroscopy, approaches have been performed using retroperitoneal minimally invasive long tubular retractors. With this approach, the relationship between the anatomy of the lumbosacral plexus and psoas should be well known. In 2004, the AxialIF procedure was defined with a transaxial approach by Cragg¹⁷. This is performed with L5-S1 fusion from the sacrum and coccyx anterior way by a perianal incision. This way is avascular, but it is long. This approach was approved by the FDA for fusion between the L4 level and the sacrum.

The first successful fusion with lumbar arthrodesis was performed in 1911 by Albee² and Hibbs³⁰. In 1939, Venable and Stuck defined internal fixation⁸⁴. The first minimally invasive procedures for fusion were performed with frozen bone and anterior cervical fusion from cadavers in 1958 by Cloward¹⁵. Then, the fusion materials began to be improved. In 1965, Urist obtained the first demineralized bone matrix protein (BMP) from rabbit in 1965. After 19 years of laboratory experience, 14 types of BMP have been isolated⁸³.

Another minimally invasive technique is the use of an interspinous decompression device, performed by Kondrashov et al. in 2006⁴⁶.

This process is applied by the placement of a device with a diameter of 8/10/12/14 mm in the spinolaminar junction of the interspinous region of stenosis segment under local anesthesia.

VERTEBROPLASTY:

The hard spinal cortex consists of a spongy trabecular structure in a cage. Collapse of the vertebral structure occurs after exposure to compressive forces and tensile stress. This can cause osteoporosis and neoplasm vertebral compression fractures, resulting in pain, deficit, instability and deformity. Surgery is more risky for these patients due to comorbidity factors. Open pedicular screw fixation is not satisfactory, due to the large incision, technical difficulties in fixation to osteoporotic vertebrae, and failure of arthrodesis. In 1989, although Prior treated collapse fractures non-invasively with absolute bed rest, difficulties with this application were reported, such as wound problems, deep vein thrombosis, pulmonary emboli, and a high cost of the hospitalization period.

In 1984, Galibert and Deramond performed the first percutaneous vertebroplasty in France²⁵. After five years, the first applications were reported by Lapras et al. Polymethyl methacrylate (PMMA) was injected by a transpedicular route. This approach rapidly became popular in Europe, but it was not applied in the USA until 1994.

KYPHOPLASTY

In the second half of the 1990s, Reiley et al. defined kyphoplasty, due to cement extravasation, an increase in infection rate, cement toxicity, adjacent fractures and disruption of the sagittal balance⁸⁴. In 2000, this was clinically applied by Wong et al.⁹⁰.

OTHER MINIMALLY INVASIVE APPROACHES

A. Video-Guided System Applications:

After the discovery of radiography in 1895 by Roentgen, fluoroscopy in 1896 by Edison, and computerized tomography in 1972 by Hounsfield, imaging devices began to be used intraoperatively, and have advanced until the use of the Medtronic navigation O-Arm in 2005^{62,79}.

The first operation using video-guided technology was performed at the cervicomedullar junction in 1995 by Pollack⁶⁹, and with lumbar pedicle screwing by Nolte⁵⁸. In the second half of the 1990s, imaging systems developed for intracranial operations were adapted for screw fusion surgery. Characterization of the bone anatomy should be performed with a preoperative CT, in order to use this system.

Nolte et al. defined the first CT-guided pedicle screw fixation operation. They stated that the general accuracy was 1.74 mm because they used CT at 2 mm intervals in their systems⁵⁸. The entrance point is visualized with an infrared camera by a pedicle probe. A dynamic reference fixated to the spinous process is determined. Preoperative CT correlation is obtained with normal bone landmarks, and screw application is performed. In this first clinical series, the ratio of incorrectly positioned screws was reported to be 4.3%. Choi et al.¹¹ reported pedicle screw fixation with a fluoroscopic target point in conjunction with CT. The entrance point and depth are calculated using intraoperative AP and lateral fluoroscopy, and these are compared with CT. No change in success rates was observed.

B. Robotic Spine Surgery:

Many studies were conducted on pedicle screwing with a first generation CT-guided video system for intraoperative navigation. In a randomized and controlled clinical series conducted by Laine et al. in 2000 including 100 patients, pedicle perforation was found to occur in 13.4% with the conventional method and in 4.6% with a CT-guided navigation method⁴⁷. In many studies, a lower risk potential for pedicle screwing with a CT-guided navigation system was reported compared with the conventional method, except for studies conducted in 2001 by Arand et al. and in 2009 by Li et al.^{4,42}. In the study by Li et al., a 4 mm pedicle perforation was found in 1.4% (4/277) of cases with the conventional method, and not found with the CT-guided navigation system. These results were not found to be statistically significant. In the study, they stated that morbidity increased with use of a CT-guided navigation system, due to the extended period⁵¹.

Pedicle screwing is the most common and best method for scoliosis surgery. In recent years, the conventional method has been replaced with CT-guided navigation systems for scoliosis correction surgery. It is known that neural and vascular injury and screw malpositioning are the most important complications of this surgery. Meroz et al. used this navigation with scoliosis for the first time in 1998, and reported malpositioning of four

of 28 pedicle screws⁵⁷. In 2009, Nakanishi et al. detected 11 total deviations according to the Neo classification in a clinical series including 264 patients, and no neural or vascular injury was reported. In a study by Kotani et al., comparing the conventional method with the CT-guided navigation system in a retrospective cohort, they detected 11% and 1.8% screw perforation, respectively. In a study including 19 patients, Yang et al. obtained similar results for adolescent scoliosis surgery⁹². In a meta-analysis performed by Tian in 2011, high accuracy rates were reported using CT-guided navigation systems in many studies⁷⁷. In a meta-analysis study including 23 published reports performed by Verma et al. in 2010, the accuracy rate of 1,838 screws with a navigation system was reported to be 93.3%, while the accuracy rate of 2,437 screws without a navigation system was reported to be 84.7%⁸⁵. There have been studies reporting accuracy rates reaching 99%.

In the last ten years, CT-guided navigation systems have been commonly used in the sacral-lumbar and thoracic regions, and there have been studies into its use in the cervical region, and also the craniocervical region. The most recent study involved C1–2 transarticular screw fixation performed by Uehara with the Magerl method for 20 cases of atlantoaxial instability in 2012⁸². In 2000, Lee carried out a transoral robotic surgery cadaver study⁴⁸.

In the last 1–2 years, second generation CT-guided robotic surgery has become common, but there have been no randomized studies concerning this technology.

REFERENCES

1. Adamson TE. Microendoscopic posterior cervical laminoforaminotomy for unilateral radiculopathy: results of a new technique in 100 cases. *J Neurosurg* 2001; 95 (1 Suppl): 51–57.
2. Albee FH. Transplantation of a portion of the tibia into the spine for Pott's disease. A preliminary report. *JAMA* 57: 885–886, 1911
3. Anand N, Baron EM, Thaiyananthan G, Khalsa K, Goldstein TB. Minimally invasive multilevel percutaneous correction and fusion for adult lumbar degenerative scoliosis: a technique and feasibility study. *J Spinal Disord Tech* 2008; 21: 459–67.
4. Arand M, Hartwig E, Hebold D, Kinzl L, Gebhard F. Precision analysis of navigation-assisted implanted thoracic and lumbar pedicled screws. A prospective clinical study. *Unfallchirurg* 2001; 104: 1076–1081.
5. Ascher PW, Heppner F. CO₂-Laser in neurosurgery. *Neurosurg Rev* 1984; 7: 123–133.
6. Benjamin V. Diagnosis and management of thoracic disc disease. *Clin Neurosurg* 1983; 30: 577–605.
7. Burman MS. Myelotomy or the direct visualization of the spinal cord and its contents. *J Bone Joint Surg* 1931; 13: 695–696.
8. Burns BH. An operation for spondylolisthesis. *Lancet* 1933; 1: 1233.
9. Caspar W. A new surgical procedure for lumbar disc herniation causing less tissue damage through a microsurgical approach. *Advances in Neurosurgery* 1977; 4: 74–80.
10. Chiu JC, Clifford TJ, Greenspan M, Richley RC, Lohman G, Sison RB. Percutaneous microdecompressive endoscopic cervical discectomy with laser thermolysis. *Mt Sinai J Med* 2000; 67: 278–282.
11. Choi WW, Green BA, Levi AD. Computer-assisted fluoroscopic targeting system for pedicle screw insertion. *Neurosurgery* 2000; 47: 872–878.
12. Choy DS. Response of extruded intervertebral herniated discs to percutaneous laser disc decompression. *J Clin Laser Med Surg* 2001; 19: 15–20.
13. Cloward RB. The treatment of ruptured lumbar intervertebral disc by vertebral body fusion. III. Methods and use of banked bone. *Ann Surg* 1952; 136: 987–992.
14. Cloward RB. The treatment of ruptured lumbar intervertebral discs by vertebral body fusion. I. Indications, operative technique, after care. *J Neurosurg* 1953; 10: 154–168.
15. Cloward RB. The anterior approach for removal of ruptured cervical discs. *J Neurosurg* 1958; 15: 602–617.
16. Coric D, Adamson T. Minimally invasive cervical microendoscopic laminoforaminotomy. *Neurosurg Focus* 2008; 25: E2.
17. Cragg A, Carl A, Casteneda F, Dickman C, Guterman L, Oliveira C. New percutaneous access method for minimally invasive anterior lumbar surgery. *J Spinal Disord Tech* 2004; 17: 21–28.
18. Fang HSY, Ong GB. Direct anterior approach to the upper cervical spine. *J Bone Joint Surg* 1962; 44-A: 1588–1604.
19. Faubert C, Caspar W. Lumbar percutaneous discectomy. Initial experience in 28 cases. *Neuroradiology* 1991; 33: 407–410.

20. Fernström U. Arthroplasty with intercorporeal endoprosthesis in herniated disc and in painful disc. *Acta Chir Scand* 1966; 357: 154-159.
21. Fessler RG, Khoo LT. Minimally invasive cervical microendoscopic foraminotomy: an initial clinical experience. *Neurosurgery* 2002; 51 (5 Suppl): S37-45.
22. Foley KT, Smith MM. Microendoscopic discectomy. *Tech Neurosurg* 1997; 3: 301-307.
23. Foley KT, Gupta SK, Justis JR, Sherman MC. Percutaneous pedicle screw fixation of the lumbar spine. *Neurosurg Focus* 2001; 10(4): E10.
24. Frempong-Boadu AK, Faunce WA, Fessler RG. Endoscopically assisted transoral-transpharyngeal approach to the craniovertebral junction. *Neurosurgery* 2002; 51(5 Suppl): S60-66.
25. Galibert P, Deramond H, Rosat P, Le Gars D. Preliminary note on the treatment of vertebral angioma by percutaneous acrylic vertebroplasty. *Neurochirurgie* 1987; 233: 166-168 (Fr).
26. Guiot BH, Khoo LT, Fessler RG. A minimally invasive technique for decompression of the lumbar spine. *Spine* 2002; 27: 432-438.
27. Hadley MN, Spetzler RF, Sonntag VK. The transoral approach to the superior cervical spine. A review of 53 cases of extradural cervicomedullary compression. *J Neurosurg* 1989; 71: 16-23.
28. Hadra BE. Wiring the spinous process in Pott's disease. *Trans Am Orthop Assoc* 1891; 4: 206-208.
29. Harms J, Rolinger H. A one-stager procedure in operative treatment of spondylolistheses: dorsal traction-reposition and anterior fusion (author's transl)[Article in German]. *Z Orthop Ihre Grenzgeb* 1988; 120(3): 343-347.
30. Hibbs RA. An operation for progressive spinal deformities. *NY Med J* 1911; 93: 1013-1016.
31. Hijikata S. Percutaneous nucleotomy. A new concept technique and 12 years' experience. *Clin Orthop* 1989; 238: 9-23.
32. Holly LT, Schwender JD, Rouben DP, Foley KT. Minimally invasive transforaminal interbody fusion: indications, technique, and complications. *Neurosurg Focus* 2006; 20(3): E6.
33. Horgan MA, Hsu FP, Frank EH. A novel endoscopic approach for anterior odontoid fixation: technical note. *Minim Invasive Neurosurg* 1999; 42: 142-145.
34. Horowitz MB. Thoracic discectomy using video assisted thoracoscopy. *Spine* 1994; 19: 1082-1086.
35. Isaacs RE, Podichetty VK, Sandhu FA, Santiago P, Spears JD, Aaronson O, Kelly K, Hrubes M, Fessler RG. Thoracic microendoscopic discectomy: a human cadaver study. *Spine* 2005; 30: 1226-1231.
36. Jacobaeus HC. Possibility of the use of the cystoscope for investigation of serious cavities. *Munch Med Wochenschr* 1910; 57: 2090-2092.
37. Jang JS, Lee SH, Lim SR. Guide device for percutaneous placement of translamina facet screws after anterior lumbar interbody fusion. Technical note. *J Neurosurg* 2003; 98: 100-103.
38. Jang JS, Lee SH. Clinical analysis of percutaneous facet screw fixation after anterior lumbar interbody fusion. *J Neurosurg Spine* 2005; 3(1): 40-46.
39. Jansen EF, Balls AK. Chymopapain: a new crystalline proteinase from papaya latex. *J Biol Chem* 1941; 137: 459-460.
40. Jho HD. Endoscopic transpedicular thoracic discectomy. *Neurosurg Focus* 2000; 9 (4): e4.
41. Kambin P, Gellman H. Percutaneous lateral discectomy of the lumbar spine: a preliminary report. *Clin Orthop* 1983; 174: 127-132.
42. Kambin P, Brager MD. Percutaneous posterolateral discectomy. Anatomy and mechanism. *Clin Orthop Relat Res* 1987; 223: 145-154.
43. Khoo LT, Fessler RG. Microendoscopic decompressive laminotomy for the treatment of lumbar stenosis. *Neurosurgery* 2002; 51 (5 Suppl): S146-S154.
44. Khoo LT, Palmer S, Laich DT, Fessler RG. Minimally invasive percutaneous posterior lumbar interbody fusion. *Neurosurgery* 2002; 51 (5 Suppl): 166-171.
45. Kim DH, O'Toole JE, Ogden AT, Eichholz KM, Song J, Christie SD, Fessler RG. Minimally invasive posterolateral thoracic corpectomy: cadaveric feasibility study and report of four clinical cases. *Neurosurgery* 2009; 64: 746-753.
46. Kondrashov DG, Hannibal M, Hsu KY, Zucherman JF. Interspinous process decompression with the X-STOP device for lumbar spinal stenosis. A 4-year follow-up study. *J Spinal Disord Tech* 2006; 19: 323-327.
47. Laine T, Lund T, Ylikoski M, Lohikoski J, Schlenzka D. Accuracy of pedicle screw insertion with and without computer assistance: a randomised controlled clinical study in 100 consecutive patients. *Eur Spine J* 2000; 9: 235-240.
48. Lee JY, O'Malley BW, Newman JG, Weinstein GS, Lega B, Diaz J. Transoral robotic surgery of craniocervical junction and atlantoaxial spine: a cadaveric study. *J Neurosurg Spine* 2010; 12: 13-18.

49. Leng LZ, Anand VK. Endonasal endoscopic resection of an os odontoideum to decompress the cervicomedullary junction: a minimal access surgical technique. *Spine* 2009; 34: E139-143.
50. Li J, Yan DL, Zhang ZH. Percutaneous cervical nucleoplasty in the treatment of cervical disc herniation. *Eur Spine J* 2008; 17: 1664-1669.
51. Li SG, Sheng L, Zhao H. Computer-assisted navigation technique in the spinal pedicle screw internal fixation. *J Clin Rehabil Tissue Eng Res (Chin)* 2009; 13: 3365-3369.
52. Lidar Z, Lifshutz J, Bhattacharjee S, Kurpad SN, Maiman DJ. Minimally invasive, extracavitary approach for thoracic disc herniation: technical report and preliminary results. *Spine J* 2006; 6: 157-163.
53. Magerl F External skeletal fixation of the lower thoracic and lumbar spine. In: Uthoff HK, Stahl E (eds). *Current Concepts of External Fixation of Fractures*. Springer-Verlag, New York 1982; pp: 353-366.
54. Maroon JC. Current concepts in minimally invasive discectomy. *Neurosurgery* 2002; 51 (Suppl 2): 137-145.
55. Mayer HM. A new microsurgical technique of minimally invasive anterior lumbar spine fusion. *Spine* 1997; 22: 691-699.
56. McCulloch JA. Microsurgery for lumbar disc disease. In: An HS, Riley LH (Eds.) *An Atlas of Surgery of the Spine*. London (UK), Martin Dunitz Ltd., 1998.
57. Merloz P, Tonetti J, Pittet L, Coulomb M, Lavalloé S, Sautot P. Pedicle screw placement using image guided techniques. *Clin Orthop Relat Res* 1998; 354: 39-48.
58. Nolte LP, Zamorano LJ, Jiang Z, Wang Q, Langlotz F, Berlemann U. Image-guided insertion of trans-pedicular screws. A laboratory setup. *Spine* 1995; 20: 497-500.
59. Obenchain TG. Laparoscopic lumbar discectomy: case report. *J Laparoendosc Surg* 1991; 1: 145-149.
60. Onik G, Helms CA, Ginsberg L, Hoagland FT, Morris J. Percutaneous lumbar discectomy using a new aspiration probe. *Radiology* 1985; 155: 251.
61. Ooi Y, Sato Y, Morisaki N. Myeloscopy: the possibility of observing the lumbar intrathecal space by use of an endoscope. *Endoscopy* 1973; 5: 901-906.
62. Oppenheimer JH, De Castro I, McDonnell DE. Minimally invasive spine technology and minimally invasive spine surgery: a historical review. *Neurosurg Focus* 2009; 27 (3): E9.
63. Ottolenghi CE. Diagnosis of orthopaedic lesions by aspiration biopsy; results of 1,061 punctures. *J Bone Joint Surg* 1955; 37: 443-464.
64. Palmer S, Turner R, Palmer R. Bilateral decompression of lumbar spinal stenosis involving a unilateral approach with the microscope and tubular retractor system. *J Neurosurg* 2002; 97 (2 Spine Suppl): 213-217.
65. Park P, Foley KT. Minimally invasive transforaminal lumbar interbody fusion with reduction of spondylolisthesis: technique and outcomes after a minimum of 2 years' follow-up. *Neurosurg Focus* 2008; 25: E16.
66. Perez-Cruet MJ, Kim BS, Sandhu F, Samartzis D, Fessler RG. Thoracic microendoscopic discectomy. *J Neurosurg Spine* 2004; 1: 58-63.
67. Perez-Cruet MJ, Wang MY, Samartzis D. Microendoscopic cervical laminoplasty and laminectomy. In: Kim DH, Fessler RG, Egan JJ (eds), *Endoscopic Spine Surgery and Instrumentation*. New York, Thieme, 2004; pp: 74-87.
68. Pimenta L, Diaz RC, Guerrero LG. Charité artificial disc retrieval: use of a lateral minimally invasive technique. Technical note. *J Neurosurg Spine* 2006; 5: 556-561.
69. Pollack IF, Welch W, Jacobs GB, Janecka IP. Frameless stereotactic guidance. An intraoperative adjunct in the transoral approach for ventral cervicomedullary junction decompression. *Spine* 1995; 20: 216-220.
70. Pool JL: Direct visualization of dorsal nerve roots of the cauda equina by means of a myeloscope. *Arch Neurol Psychiatr* 39: 1308-1312, 1938
71. Regan JJ, Mack MJ, Picetti GD II. A comparison of VAT to open thoracotomy in thoracic spinal surgery. Presented at the *Scoliosis Research Society Meeting*. Dublin, September 18-23, 1993.
72. Roh SW, Kim DH, Cardoso AC, Fessler RG. Endoscopic foraminotomy using MED system cadaveric specimens. *Spine* 2000; 25: 260-264.
73. Rosenthal D, Rosenthal R, de Simone A. Removal of a protruding thoracic disc using microsurgical endoscopy. A new technique. *Spine* 1994; 19: 1087-1091.

-
74. Ruetten S, Komp M, Merk H, Godolias G. Full-endoscopic anterior decompression versus conventional anterior decompression and fusion in cervical disc herniations. *Int Orthop* 2009; 33: 1677–1682.
 75. Sachdev VP. Microsurgical lumbar discectomy: a personal series of 300 patients with at least 1 year follow-up. *Microsurgery* 1986; 7: 55–62.
 76. Smith L, Garvin PJ, Gesler RM, Jennings R.B. Enzyme dissolution of the nucleus pulposus. *Nature* 1963; 198: 1311–1312.
 77. Tian NF, Huang QS, Zhou P, Zhou Y, Wu RK, Lou Y, Xu HZ. Pedicle screw insertion accuracy with different assisted methods: a systematic review and meta-analysis of comparative studies. *Eur Spine J* 2011; 20: 846–859.
 78. Thomas L. Reversible collapse of rabbit ears after intravenous papain, and prevention of recovery by cortisone. *J Exp Med* 1956; 104: 245–252.
 79. Thongtrangan I. Minimally invasive spinal surgery: a historical perspective. *Neurosurg Focus* 2004; 16 (1): 13.
 80. Tong FC, Cloft HJ. Transoral approach to cervical vertebroplasty for multiple myeloma. *AJR Am J Roentgenol* 2000; 175: 1322–1324.
 81. Tsuji H. Laminoplasty for patients with compressive myelopathy due to so-called spinal canal stenosis in cervical and thoracic regions. *Spine* 1982; 7: 28–34.
 82. Uehara M, Takahashi J, Hirabayashi H, Hashidate H, Ogihara N, Mukaiyama K, Kato H. Computer-assisted C1-C2 transarticular screw fixation “Magerl technique” for atlantoaxial instability. *Asian Spine J* 2012; 6: 168–177.
 83. Urist MR. Bone: formation by autoinduction. *Science* 1965; 150: 893–899.
 84. Venable CS, Stuck WG. Electrolysis-controlling factor in the use of metals in treating fractures. *JAMA* 1939; 3: 349.
 85. Verma R, Krishan S, Haendlmayer K, Mohsen A. Functional outcome of computer-assisted spinal pedicle screw placement: a systematic review and meta-analysis of 23 studies including 5,992 pedicle screws. *Eur Spine J* 2010; 19: 370–375.
 86. Wang MY, Green BA, Coscarell E, Baskaya MK, Levi AD, Guest JD. Minimally invasive cervical expansile laminoplasty: an initial cadaveric study. *Neurosurgery* 2003; 52: 370–373.
 87. Wang MY, Prusmack CJ, Green BA, Gruen JP, Levi AD. Minimally invasive lateral mass screws in the treatment of cervical facet dislocations: technical note. *Neurosurgery* 2003; 52: 444–448.
 88. Williams RW. Microlumbar discectomy: a conservative surgical approach to the virgin herniated lumbar disc. *Spine* 1978; 3: 175–182.
 89. Wiltse LL, Spencer CW. New uses and refinements of the paraspinous approach to the lumbar spine. *Spine* 1988; 13: 696–706.
 90. Wong WH, Reiley MA, Garfi SR. Vertebroplasty/kyphoplasty. *J Women's Imaging* 2000; 2: 117–124.
 91. Yasargil MG. Microsurgical operation of herniated lumbar disc. *Adv Neurosurg* 1977; 4: 81.
 92. Yang LL, Chen HJ, Chen DY. Clinical applications of computer assisted navigation technique in scoliosis surgery. *Orthop J Chin (Chin)* 2007; 15: 1773–1776.
 93. Zucherman JF, Zdeblick TA, Bailey SA, Mahvi D, Hsu KY, Kohrs D. Instrumented laparoscopic spinal fusion. Preliminary results. *Spine* 1995; 20: 2029–2035.
-