



HISTOPATHOLOGICAL CHANGES IN THE LIGAMENTUM FLAVUM OF PATIENTS OPERATED ON FOR LUMBAR SPINAL STENOSIS

LOMBER SPİNAL DAR KANAL NEDENİYLE OPERE EDİLEN HASTALARIN LİGAMENTUM FLAVUMUNDAKİ HİSTOPATOLOJİK DEĞİŞİKLİKLER

Ergün KARAVELİOĞLU¹,
Ahmet Metin ŞANLI²,
Olca ESER¹,
Zeki ŞEKERCİ³

¹Neurosurgery Specialist, Afyon Kocatepe University, Medical School, Afyon.

²Neurosurgery Specialist, S.B Dışkapı Yıldırım Beyazıt Training and Research Hospital, Ankara.

³Assoc. Dr., Neurosurgery Specialist, S.B Dışkapı Yıldırım Beyazıt Training and Research Hospital, Ankara.

SUMMARY:

The most common spinal disorder in adult patients is lumbar spinal canal stenosis (LSCS), causing lower back and leg pain and paresis. Canal stenosis partly results from hypertrophy of the ligamentum flavum. There are only a few studies about ligamentum flavum hypertrophy in the literature, and the exact pathomechanism of hypertrophy is still unknown. A multidisciplinary study involving both clinical and histological approaches was planned. Histological evaluation was performed on 22 ligamentum flavum samples which were collected during surgery for LSCS (12 patients) and lumbar disc hernia (10 patients).

Masson's trichrome and Verhoeff-Van Gieson elastic stains were performed for each ligamentum flavum to understand the degree of fibrosis and elastic fiber status. There were no statistically significant differences in fibrosis and elastic fiber loss between the two groups. Considering the groups independently, histology showed that with age, ligamentum flavum fibrosis increased and the elastic fibers decreased. In conclusion, increased fibrosis with age is the main cause of ligamentum flavum hypertrophy.

Key words: Ligamentum flavum, lumbar spinal stenosis, histopathology, elastin, collagen

Level of evidence: Retrospective histopathological study, Level III

ÖZET:

Erişkin hastalarda en sık bel ve bacak ağrısı ve pareziye neden olan spinal bozukluk lomber spinal dar kanaldır. Kanal daralmasının en önemli nedenlerinden birisi ligamentum flavum hipertrofidir. Ligamentum flavum hipertrofinin histopatolojisi hakkında literatürde yapılmış çok az çalışma mevcut olup hipertrofinin patolojik mekanizması hakkında kesin bir bilgi yoktur. Bu amaçla klinik ve histolojik yaklaşımları içeren multidisipliner bir çalışma planlanmıştır.

Lomber spinal dar kanal (12 hasta) ve lomber disk hernisi cerrahisi (10 hasta) esnasında toplanan 22 ligamentum flavum örneklerinde histolojik değerlendirme yapılmıştır. Fibrosis ve elastik lif derecesini anlamak için her bir ligamentum flavum örneğine Mason Trikrom ve Verhoaff-van Gieson elastik boyama yapılmıştır.

Her iki grup arasında fibrozis ve elastik lif kaybı açısından herhangi bir fark bulunmadı. Gruplardan bağımsız olarak yaşla birlikte histolojik olarak ligamentum flavumda fibroziste artış ve elastik liflerde azalış tespit edildi. Sonuç olarak yaş arttıkça artan fibrozis ligamentum flavum hipertrofinde ana nedenlerden biri olduğu fikri edildi.

Anahtar Kelimeler: Ligamentum flavum, lomber spinal dar kanal, histopatoloji, elastin, kollajen

Kanıt Düzeyi: Retrospektif histopatolojik çalışma, Düzey III

Address: Op. Dr. Ergun Karavelioğlu,
Afyon Kocatepe Üniversitesi, Tıp
Fakültesi, Afyon.

Tel.: 0505 4546055

E-mail: ergunkara@hotmail.com

Received: 14th July, 2012

Accepted: 26th August, 2012

INTRODUCTION:

The most common spinal disorder in adult patients is lumbar spinal canal stenosis (LSCS), causing lower back and leg pain and paresis. As the mean age of the human population increases, the incidence of LSCS will also increase. In 1913, Elsberg stated that ligamentum flavum (LF) hypertrophy, which is one of the causes of LSCS, causes lower back and sciatic pain by mechanically compressing the nerve root and caudal equine fibers⁵. LSCS develops due to degenerative changes such as LF hypertrophy and bone proliferation of the facet joints in the posterior elements of the lumbar spinal region^{12,17}.

The ligamentum flavum surrounds the posterior and lateral parts of the lumbar spinal canal, and morphological and histological changes to the LF can result in LSCS development⁷. In studies that have been carried out using techniques including intraoperative findings, myelogram results, computerized tomography (CT) and MRI, a hypertrophied ligamentum flavum was reported to be one of the most important causes of spinal canal stenosis^{1,3,16-20}.

Histologically, the LF contains 70% elastin fibers and 30% collagen fibers¹¹. LF hypertrophy is a multifactorial process, and age, activity and mechanical stress play important roles¹⁴. The processes of degeneration and fragmentation of elastin fibers, structural disruption, and reduction, in particular due to mechanical stress, cause changes in the extracellular matrix of the LF^{6,10,20}. There have been limited studies on hypertrophy of the LF in the literature, and no accurate information about the pathological mechanism of hypertrophy. Therefore, this study aims to examine the features of patients

that received surgery due to LSCS, and histopathological changes to the ligamentum flavum.

MATERIALS AND METHODS:

12 patients who were admitted due to lower back and/or leg pain to the Neurosurgery clinic between 1 and 30 August 2008, and who received total laminectomy due to a diagnosis of LSCS, were included in the study. A total of ten patients, including one patient who received surgery due to a lumbar spinal mass and nine patients who received surgery due to a lumbar spinal disc hernia, were included as a control group. Detailed neurological examinations of all patients were performed and their anamneses were recorded.

All patients underwent two-way lumbar radiography, lumbar dynamic X-ray and lumbar MRI. A CT was taken from the patients with suspected LSCS and the canal diameter was measured. All patients were informed about the study before surgery and their permission was granted. They were also told that no other tissue sample would be taken except for tissue that was routinely taken during the planned surgery.

For the patients receiving LSCS surgery, the spinous process was taken during surgery, and then a classic total laminectomy was performed. The facet joint was preserved and a large bilateral foraminotomy was performed. After dissection of the LF, an approximately 5×5 mm tissue sample was taken with a size 15 scalpel. An LF sample was taken from the site in the leg that had the most pain. Classic hemilaminectomy followed by foraminotomy were applied to the patients receiving surgery due to lumbar disc

hernia, and an LF sample was taken by the same process used in LSCS patients.

Eight LSCS patients (66.6%) were admitted due to lower back pain and pain in both legs. Two LSCS patients (16.7%) were admitted due to lower back and right leg pain, and two (16.7%) were admitted due to lower back and left leg pain. In the control group, five patients (50%) were admitted due to lower back and right leg pain and five (50%) were admitted due to lower back and left leg pain. In the LSCS patients, eight (66%) received single-level (L4) total laminectomy and four (34%) received two-level (L3 and L4) total laminectomy. Transpedicular fusion was applied to one patient with single-level total laminectomy and two patients with two-level total laminectomy. In the control group, L2 hemilaminectomy was performed in one patient due to a mass caused by the nerve root, and right L4–5 hemipartial laminectomy was performed in two patients, right L5–S1 hemipartial laminectomy in two patients, left L4–5 hemipartial laminectomy in three patients and left L5–S1 hemipartial laminectomy in two patients.

Histopathological Examination:

The obtained ligamentum flavum materials were taken from 10% formaldehyde solution in the pathology laboratory and embedded into paraffin blocks after a routine alcohol xylene tissue track series. 5–7 micron serial sections were taken from the embedded paraffin block with a Leica RM 2255 microtome. During sectioning, sections were taken from the ligamentum flavum, ensuring that both the dural surface and the bone surface appeared in a section, as the collagen and elastin levels could be different at these two surfaces. The sections

were stained with haematoxylin and eosin, Masson's trichrome (Bio-Optica) and Verhoeff-Van Gieson (Bio-Optica) pathological dye kits, and were examined under a light microscope (Olympus).

In the stained ligamentum flavum samples, the collagen fiber and elastin fiber structures were evaluated under a light microscope using the Masson's trichrome (Bio-Optica) stain and the Verhoeff-Van Gieson (Bio-Optica) stain. The calcification was evaluated using the haematoxylin and eosin stain.

The collagen and elastin fibers in the ligamentum flavum samples were evaluated according to the grading system by Sairyo et al.¹⁴. According to this grading system, with Masson's trichrome staining the evaluations are as follows: Degree 0: normal tissue without fibrosis, Degree 1: fibrosis in less than 25% of displayed area, Degree 2: fibrosis in between 25–50% of displayed area, Degree 3: fibrosis in between 50–75% of displayed area, Degree 4: fibrosis in more than 75% of displayed area.

In Verhoeff-Van Gieson elastic staining, the evaluations are as follows: Degree 0: no elastic fiber loss, Degree 1: elastic fiber loss in less than 25% of displayed area, Degree 2: elastic fiber loss in between 25–50% of displayed area, Degree 3: elastic fiber loss in between 50–75% of displayed area, Degree 4: elastic fiber loss in more than 75% of displayed area.

While grading using this system, at least five regions for each pathology preparation were examined. These five regions were graded separately, and all the pathology samples were graded by taking the average of these regions.

Statistical Analysis:

Analyses of the data were performed with SPSS (SPSS Inc., Chicago, IL, United States) for Windows 1.5 statistical package program. Descriptive statistics were presented as mean \pm standard deviation for continuous variables, as median (minimum–maximum) for sortable variables and as case number and percentage for nominal variables. The Mann-Whitney U test was used to determine whether the elastin and collagen scores showed any significant differences in terms of the study groups, age and gender. Fisher's absolute Chi-Square test was used to evaluate nominal variables. $p < 0.05$ was accepted as significant.

RESULTS:

Ten of the 12 patients (83%) who received surgery due to LSCS were female, and two (17%) were male. The mean age was 60.3 ± 11.8 (38–78). In the control group, five of the ten patients (50%) were female and five (50%) were male. The mean age was 46.3 ± 15.4 (24–64). There was a significant difference between the groups in terms of the mean age ($p = 0.025$) (Table-1).

Histopathological Evaluation:

The stained ligamentum flavum samples were evaluated under the light microscope to evaluate the collagen fiber structure, elastic fiber structure and calcification. As described in the Materials and Methods section, the grading was performed using the system defined by Sairyo et al. No calcification or inflammation was detected

in the sections stained with haematoxylin and eosin (Figure-1).

According to the staining with Masson's trichrome (Bio-Optica), the collagen fiber degrees of the patients that received surgery due to LSCS varied between degree 1 and 4, and the mean was found to be 2.42. In the control group, the collagen fiber degree varied between 1 and 2 with Masson's trichrome (Bio-Optica) staining, and the mean was 1.7.

According to the Verhoeff-Van Gieson (Bio-Optica) staining, the elastic fiber loss degrees of the patients that received surgery due to LSCS varied between degree 0 and 3, and the mean was 1.58. In the control group, the degree of elastic fiber loss varied between 0 and 2 according to the Verhoeff-Van Gieson (Bio-Optica) staining, and the mean was 1.

There were no statistically significant differences between the LSCS and control patients in terms of the elastin and collagen levels ($p = 0.180$, $p = 0.093$). When patients were separated into groups of those over 50 and those less than 50 years old, a statistically significant difference was found between the elastin levels ($p = 0.005$), but no significant difference was found between the collagen levels ($p = 0.110$). Between males and females, there were no statistically significant differences in terms of the elastin and collagen levels ($p = 0.056$, $p = 0.210$) (Table-2).

When the LSCS patients were grouped into those over 50 and those less than 50 years old, there were no significant differences between

Table-1. Demographic data

Variables	Control Group (n=10)	LSCS Group (n=12)	P
Age groups			0.378
≤50 years old	5 (50%)	3 (25%)	
>50 years old	5 (50%)	9 (75%)	
Gender			0.172
Male	5 (50%)	2 (16.7%)	
Female	5 (50%)	10 (83.3%)	

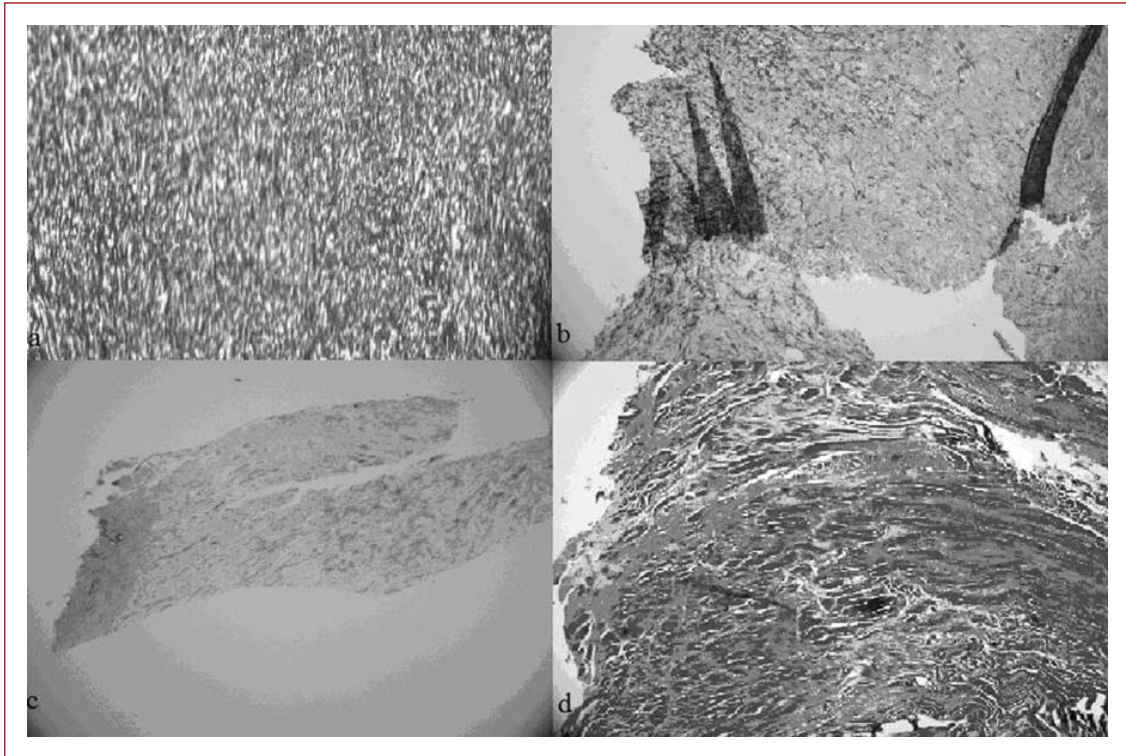


Figure-1. a) Image of Degree 0 in elastic fiber loss grading (10× resolution), b) Image of Degree 3 in elastic fiber loss grading (10× resolution), c) Image of Degree 1 in collagen fiber grading (10× resolution), d) Image of Degree 4 in collagen fiber grading (10× resolution).

the elastin or the collagen levels ($p=0.373$, $p=0.864$). When the control patients were grouped into those over 50 and those less than 50 years old, the collagen levels were not significantly different ($p=0.151$), although there was a statistically significant difference in terms of the elastin level ($p=0.008$). When the control and LSCS patients were compared, no statistically significant differences were

found between the elastin and collagen levels of the patients over and less than 50 years old (Table-3).

DISCUSSION:

LSCS, which generally develops due to degenerative changes to the vertebral column with advanced age, is gaining importance due

to the increase in the mean age of the human population. The functional activities of patients with sciatica complaints with or without neurogenic claudication are limited, and patients are bedridden.

Lumbar spinal stenosis typically develops as a result of complex degenerative processes that cause compression of neural elements¹⁹.

Spinal stenosis is encountered as central cord stenosis, lateral recess stenosis, degenerative spondylolisthesis, or all three. It is thought that degenerative stenosis and lumbar spondylosis occur due to facet hypertrophy, ligamentum

flavum thickening and degeneration and osteophyte formation as a result of repetitive axial loading and rotational difficulties¹⁸. Spinal stenosis can occur due to postoperative, posttraumatic, neoplastic, or infectious reasons, due to bone disease (as in Paget's disease), or due to congenital stenosis (achondroplasty form).

In a study conducted by Sairyo et al., the thickness of 308 ligamentum flavum samples were measured using MRI, and the elastin and collagen levels were examined in 20 ligamentum flavum samples taken from patients receiving surgery for similar reasons to those included in this study¹⁴.

Table-2. Elastin and collagen scores according to study groups, age and gender among all cases

Variable Groups	Elastin	p	Collagen	P
Control Group	1 (0-2)	0.180	2 (1-2)	0.093
LSCS Group	2 (0-2)		2 (1-4)	
Age Groups				
≤50 years old	0.5 (0-2)	0.005	1.5 (1-4)	0.110
>50 years old	2 (0-2)		2 (1-4)	
Gender				
Male	0 (0-2)	0.056	2 (1-3)	0.210
Female	2 (0-2)		2 (1-4)	

Table-3. Elastin and collagen scores according to study groups and age

Variables	Control Group	LSCS Patients	pa
Elastin			
≤50 years old	0 (0-1)	1 (1-2)	0.071
>50 years old	2 (1-2)	2 (0-2)	0.898
pb	0.008	0.373	
Collagen			
≤50 years old	1 (1-2)	2 (1-4)	0.393
>50years old pb	2 (2-2)	2 (1-4)	0.364
	0.151	0.864	

a: comparisons between control and LSCS among age groups.

b: comparisons between age groups among study groups.

A significant increase was observed in the thickness of the ligamentum flavum with age, especially at the L3–4 and L4–5 levels. As the thickness of the ligamentum flavum increased histologically, an increase in the fibrosis degree and a decrease in the elastin fibers were detected¹⁴. There was no control group in this study.

In another study carried out by Bademci et al., ligamentum flavum samples from 40 patients that received surgery at the lumbar region due to disc hernia or other reasons were evaluated by electron microscope².

In histological evaluation, it was observed that the elastin fibers were thin and regular, and there were thin collagen fibers in the LF sections taken from patients with no discopathy. In the LF samples of the patients that received surgery due to disc hernia and discopathy, the thickness and irregularity of elastin fibers increased with age, there were increased collagen fibers and chondrocytes, and calcification signs were detected between the fibers, particularly in elderly patients. There was no inflammation².

In a biochemical study conducted by Güner et al., ligamentum flavum and disc materials of 25 patients with lumbar disc hernia were collected, and the collagen and elastin levels were biochemically examined⁸. This study showed that while the elastin and collagen levels were 54.6% and 7.98%, respectively, in the ligamentum flavum, their levels were 1.68% and 6.15%, respectively, in the disc material⁸. In a study by Çoşkun et al., ligamentum flavum samples of 8, 16 and 6 patients that received surgery for extruded discs, protruded discs and spinal tumors (control group), respectively, were biochemically analyzed and the collagen levels were found to be 8.7% in the extruded

disc group, 13.7% in the protruded disc group, and 23.1% in the control group⁴. No significant relationship between age and collagen content was found on statistical analysis⁴.

In a study conducted by Kosaka et al., ligamentum flavum samples were taken from five young patients with LSCS (18–47 years old), five elderly patients (78–92 years old) and one fetus, as a control⁹. These 11 LF samples were stained with haematoxylin and eosin, elastic Von Gieson and Masson's trichrome. This showed that more than 75% elastic fibers were detected in the fetal ligamentum flavum. In the young and the elderly population, approximately 75% elastic fibers were detected, and a decrease in elastic fibers was observed with an increase in age⁹.

In a study including 31 patients conducted by Schrader et al., 38 ligamentum flavum samples taken from 21 LSCS patients, and 20 ligamentum flavum samples taken from ten cadavers as a control, were examined with a special image analysis program¹⁵. This showed a statistically significant difference between the two groups.

In another study conducted by Okuda et al., 50 ligamentum flavum samples taken from patients with degenerative lumbar spinal disorder were examined¹³. The examined ligament samples were classified as mild, moderate or severe in terms of elastic fiber loss, elastic fiber degeneration, and collagen fiber proliferation. The results showed that 19 were mild, 30 were moderate, and one was severe in terms of elastic fiber loss. 12 were mild, 37 were moderate, and one was severe in terms of elastic fiber degeneration. 11 were mild, 37 were moderate and one was severe in terms of collagen fiber proliferation¹³.

In this study, the mean age of the LSCS patients was 60.3 ± 1.8 (38–78), similar to other studies. The mean elastin level of the LSCS patients in this study was 1.58. In the study conducted by Sairyo et al., this was 1.47, and a similar result was found in our study¹⁴. According to the collagen grading system, the mean was 2.42 in this study. Similarly, this was 1.95 in the study by Sairyo et al., and this was lower than our value¹⁴. The reason for this could be due to the different patient age distribution.

In studies including patients with lumbar disc hernia and LSCS, Bademci et al. and Schrader et al. detected calcification, but there was no calcification in this study. There was no sign of inflammation in either of the studies^{2,15}.

A significant reduction and irregularity were found in the parallel placement of elastin fibers in LSCS patients with age. In the same study, calcification was evaluated, and no statistically significant increase in the incidence of calcification was observed with increasing age¹⁵.

In this study, the collagen levels increased and the elastin levels decreased with age in the LSCS and control patients. Regardless of the patient group, when the patients were grouped based on whether they were over or less than 50 years old, the collagen level increased with age and the elastin level reduced ($p=0.008$). Regardless of the patient group, when the patients were grouped by gender, the elastin loss was lower in males and greater in females. Both groups were the same in terms of the collagen levels. Among these results, only the elastin level significantly decreased with age, and the other results were not found to be statistically significant. This could be due to an insufficient patient number. When we grouped LSCS patients by whether they were

over or less than 50 years old, the collagen level remained same and the elastin level decreased in the group over 50 years old. In the control group, the collagen level and elastin fiber loss increased in the group over 50 years old. Among these results, only the decrease in elastin level with age was found to be statistically significant in the control group, and the other results were not statistically significant. The reason for this could also be insufficient patient numbers. When the LSCS patients less than 50 years old and the control group were compared, the elastin fiber loss and collagen levels were found to be lower in the control group. The reason could be the lower mean age of the control group. However, these results were not found to be statistically significant. When the LSCS patients over 50 years old and the control group were compared, the elastin fiber loss and collagen levels were found to be the same for both groups, and this result was not statistically significant.

In this study, the low number of patients could affect the detection of statistically significant results. More reliable results can be obtained by increasing the patient numbers in the LSCS and control groups.

In conclusion, this suggests that an increase in fibrosis with age could be the main cause of ligamentum flavum hypertrophy.

REFERENCES:

1. Avrahami E, Wigler I, Stern D, Caspi D, Yaron M. Computed tomographic (CT) demonstration of the ligamenta flava of the lumbosacral spine associated with protrusion of the intervertebral disc. *Spine* 1990; 15: 21–23.
2. Bademci G, Batay B, Erdemli E, Erdoğan A. Lomber diskopatilerde ligamentum flavumdaki erken histopatolojik değişikliklerin incelenmesi. *Türk Nöroşirurji Derg* 2001; 1(1): 23–26.
3. Beamer YB, Garner JT, Shelden HS. Hypertrophied ligamentum flavum. *Arch Surg* 1973; 106: 289–292.
4. Çoşkun E, Süzer T, Oktay G, Tokgöz Z, Köseoğlu M.H. Collagen contents in lumbar intervertebral disc protrusion and free fragments. *J Neurological Sci* 2000; 17(3): 1–6.
5. Elsberg CA. Experiences in spinal surgery. *Surg Gynecol Obstet* 1913; 16: 117–132.
6. Fukuyama S, Nakamura T, Ikeda T, Takagi K. The effect of mechanical stress on hypertrophy of the lumbar ligamentum flavum. *J Spinal Disord* 1995; 8(2): 126–130.
7. Giles LG, Kaveri MJ. Some osseous and soft tissue causes of human intervertebral canal (foramen) stenosis. *J Rheumatol* 1990; 17: 1474–1481.
8. Güner A, Oktay G, Pabuçcuoğlu U, Kerman M, Güner G. Microscopic and molecular study of elastin and collagen in human intervertebral disc. *Turkish Neurosurgery* 1995; 5(3-4): 45–49.
9. Kosaka H, Sairyo K, Biyani A, Leaman D, Yeasting R, Higashino K, Sakai T, Katoh S, Sano T, Goel VK, Yasui N. Pathomechanism of loss of elasticity and hypertrophy of lumbar ligamentum flavum in elderly patients with lumbar spinal stenosis. *Spine* 2007; 32(25): 2805–281 .
10. Löhr M, Hampl AJ, Lee JY, Ernestus RI, Deckert M, Stenzel W. Hypertrophy of the ligamentum flavum is associated with inflammation-related TGF- β expression. *Acta Neurochir (Wien)* 201; 153(1): 134–141
11. Nachemson AL, Evans JH. Some mechanical properties of the third human lumbar interlaminar ligament (ligamentum flavum). *J Biomech* 1968; 1: 21 –220.
12. Nakatani T, Marui T, Hitora T. Mechanical stretching force promotes collagen synthesis by cultured cells from human ligamentum flavum via transforming growth factor β . *J Orthop Res* 2002; 20: 1380–1386.
13. Okuda T, Baba İ, Fujimoto Y, Tanaka N, Sumida T, Manabe H, Hayashi H, Ochi M. The pathology of ligamentum flavum in degenerative lumbar disease. *Spine (Phila Pa 1976)* 2004; 29(5): 1689–1697.
14. Sairyo K, Biyani A, Goel KV, Leaman D, Booth R Jr, Thomas J, Gehling D, Vishnubhotla L, Long R, Ebraheim N. Pathomechanism of ligamentum hypertrophy: a multidisciplinary investigation based on clinical, biochemical, histologic, and biologic assessments. *Spine* 2005; 30(23): 2649–2656.
15. Schrader KP, Grob D, Rahn AB, Cordey J, Dvorak J. Histology of the ligamentum flavum in patients with degenerative lumbar spinal stenosis. *Eur Spine J* 1999; 8(4): 323–328.
16. Sortland O, Magnaes B, Hauge T. Functional myelography with metrizamide in the diagnosis of lumbar spinal stenosis. *Acta Radiol Suppl* 1977; 355: 42–54.
17. Spurling RG, Mayfield FH, Rogers JB. Hypertrophy of the ligamenta flava as a cause of low back pain. *JAMA* 1937; 109: 928–933.
18. Teng P, Papatheodorou C. Myelographic findings in spondylosis of the lumbar spine. *Br J Radiol* 1963; 36: 122–128.

-
19. Towne EB, Reichert FL. Compression of the lumbosacral roots of the spinal cord by thickened ligamenta flava. *Ann Surg* 1931; 94: 327–336.
20. Yoshida M, Shima K, Taniguchi Y, Tamaki T, Tanaka T. Hypertrophied ligamentum flavum in lumbar spinal canal stenosis. *Spine* 1992; 17: 1353–1360.