



LUMBAR PERINEURAL CYST WITH RADICULOPATHY: A CASE REPORT:

RADİKÜLOPATİYLE SEYREDEN LOMBER PERİNÖRAL KİST: OLGU SUNUMU

Forhad Hossain
CHOWDHURY¹,
Mohammad Raziul
HAQUE¹

¹MD, Dr. Forhad Hossain
Chowdhury FCPS (surgery), MS
(Neurosurgery), Department of
Neurosurgery, Dhaka Medical
College & Hospital, Dhaka,
Bangladesh

SUMMARY:

Perineural cysts occur most frequently at the sacral level. Sacral perineural cysts, also known as Tarlov cysts, were first described by Tarlov in 1938. We report a rare lumbar perineural cyst causing L5 radiculopathy, along with a short review of the literature.

Key Words: Lumbar radiculopathy, perineural cyst, Tarlov cyst.

Level of Evidence: Case report, Level IV

ÖZET:

Perinöral kistler sıklıkla sakral bölgede oluşur. Tarlov kisti de denilen sakral perinöral kist, ilk kez 1938 yılında Tarlov tarafından tariflenmiştir. Bu çalışmada bu kistin nadir bir yerleşimi olan lomber yerleşimine sahip bir vaka sunulmuş ve literatür ışığında hastalık ve tedavisi tartışılmıştır.

Anahtar Kelimeler: Lomber radikülopati, perinöral kist, Tarlov kisti

Kanıt Düzeyi: Olgu sunumu, Düzey IV

Address: Dr. Forhad Hossain
Chowdhury, C6, rupayan
angel, 152, shantinagar,
Dhaka, Bangladesh
Tel.: +880 171 194 95 70
E-mail: forhadchowdhury74@
yahoo.com
Received: 12th June, 2012.
Accepted: 10th August, 2012.

INTRODUCTION:

Perineural cysts occur most frequently at the sacral level. The sacral perineural cyst, also known as the Tarlov cyst, was first described by Tarlov in 1938. Since then, about 100 cases of symptomatic perineural cysts have been reported¹³. Langdown et al. reported Tarlov cysts as a relatively common finding on lumbosacral MRIs, with a prevalence of 1–2%, while only 13% of cysts were directly responsible for symptoms⁶. Perineural cysts are very rare in the lumbar spine.

Here, we report a case of a lumbar perineural cyst with radiculopathy, along with a short review of the literature.

CASE REPORT:

A 40-year-old man presented with a seven-year history of progressively increasing left lower back pain along with radiation to the left lower

leg. A physical examination was unremarkable except for a positive straight-leg-raising test on the left side and mild tenderness of the lower lumbar spine.

Magnetic resonance imaging (MRI) showed a small extradural cyst on the left side of the spinal canal, near the L4–5 intervertebral foramen, that was compressing the left L5 root along with the dural sac. It was hypointense in T1W images and hyperintense in T2W images (Figure-1.a-b).

We approached the lesion through the left L4 lamina fenestration with flavectomy followed by subtotal removal of the cyst wall (which was thin) with evacuation of its contents (CSF-like) that decompressed the nerve root and the dural sac. Postoperative histopathology reported that it was a perineural cyst (Figure-2.a-d). Postoperatively, the patient recovered uneventfully, and was free of symptoms for 1.5 years after the operation.

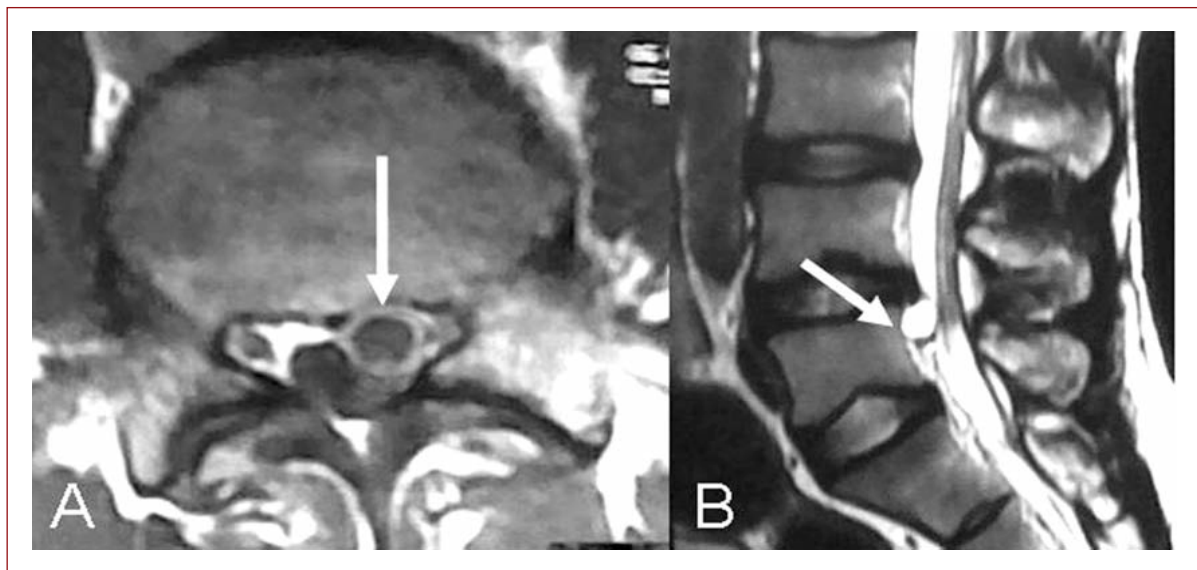


Figure-1. Preoperative MRI of lumbosacral spine. **a.** Axial T1W image showing perineural cyst (marked with an arrow). **b.** Sagittal T2W image showing the perineural cyst (marked with an arrow).

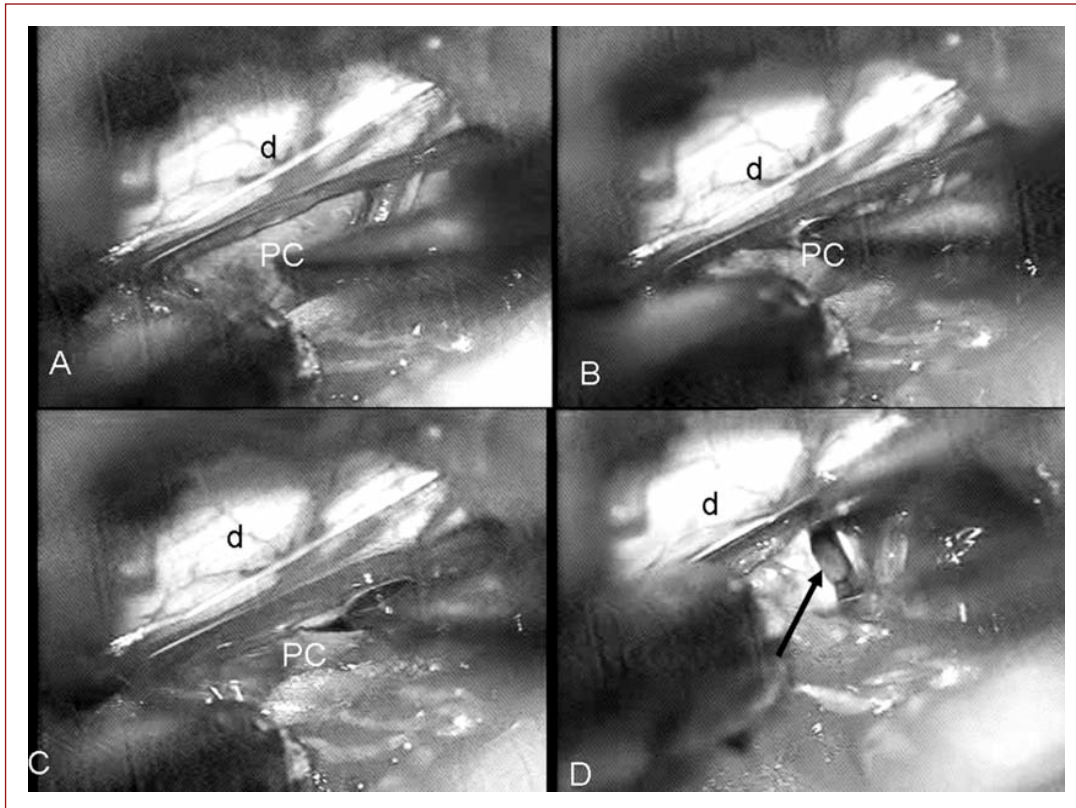


Figure-2. Perioperative pictures (d: dura mater, pc: perineural cyst). **a-b.** Intact cyst, **c.** Incision on the cyst wall, **d.** After opening of cyst and evacuation of content, the inside can be seen (marked with an arrow).

DISCUSSION:

Perineural cysts, also known as Tarlov cysts⁵, are sacs filled with cerebrospinal fluid (CSF) located in the spinal canal in the S1–4 region of the spinal cord, and can be distinguished from other meningeal cysts by their nerve-fiber-filled walls.

Tarlov cysts are defined as cysts formed within the nerve root sheath at the dorsal root ganglion². The etiology of these cysts is not well understood. Tarlov cysts are considered to be Type II lesions, defined as extradural meningeal cysts with nerve fibers⁸.

The walls of Tarlov cysts are thin and fibrous, and they are prone to rupture when touched, which

makes surgery difficult. The nerve fibers are embedded in the walls of the cysts¹. Histological examination has revealed that the outer wall of Tarlov cysts is composed of vascular connective tissue, and the inner wall is lined with flattened arachnoid tissue. Additionally, the part of the lining that contains nerve fibers also occasionally contains ganglion cells⁹.

Perineural cysts are located in the S1 and S4 region of the spinal cord. They usually form on the extradural components of the sacrococcygeal nerve roots at the junction of the dorsal root ganglion and the posterior nerve roots, and arise between the endoneurium and perineurium³.

Occasionally, these cysts are observed in other parts of the spine⁹.

However, these cysts most commonly arise at the S2 or S3 junction of the dorsal nerve root ganglion^{4,10}. The cysts are often multiple, extending around the circumference of the nerve, and can enlarge over time to compress neighboring nerve roots and cause bone erosion¹⁴.

There are several hypotheses proposed regarding the formation of Tarlov cysts, including inflammation within the nerve root cysts followed by inoculation of fluids, developmental or congenital origin, arachnoidal proliferation along and around the existing nerve root, and breakage of venous drainage in the perineurium and epineurium secondary to hemosiderin deposition after trauma³. Tarlov himself theorized that perineurial cysts form as a result of blockage of the venous drainage in the perineurium and epineurium secondary to hemosiderin deposition after local trauma^{12,14}. Another theory that has gained increasing popularity over the past decade was postulated by Fortuna et al., who described perineurial cysts to be the results of congenital arachnoidal proliferation along the existing sacral nerve roots¹¹. The cause of these cysts is still unknown, and the proposed theories have not been tested or challenged.

Tarlov cysts are known to have the tendency to enlarge over time. The main theory to explain this phenomenon suggests that the enlargement of the cysts is due to cerebrospinal fluid being pushed into the cyst during systole pulsation, and then being unable to escape during the diastole phase, resulting in enlargement over time¹¹.

Tarlov cysts are relatively common when compared to other neurological cysts, but they are usually asymptomatic. These cysts are often

detected incidentally during MRI or CT scans for other medical conditions. Cysts with diameters of greater than 1.5 cm (0.6 inch) are more likely to be symptomatic. The reported symptoms of symptomatic Tarlov cysts include back pain, perineal pain, sciatica, cauda equina syndrome, dysuria, urinary incontinence, coccygodynia, sacral radiculopathy, radicular pain, headaches, retrograde ejaculation, paresthesia, hypesthesia, motor disorders in the lower limbs and genital, perineal or lumbosacral areas, sacral or buttock pain, vaginal or penile paraesthesia, sensory changes in the buttocks, perineal areas and lower extremities, difficulty walking, and severe lower abdominal pain^{7,9-11,14}.

There is no consensus on the optimal treatment for symptomatic perineurial cysts. There are a few treatments available to alleviate the symptoms caused by these cysts, but their effectiveness is debatable. It has been reported that a positive filling defect and a larger cyst size (>1.5 cm or 0.6 inch) are good indicators for successful treatment outcome^{1,3,11}. Although fibrin-glue therapy has been shown to be a promising therapy for the treatment of these cysts, there have been cases of the fibrin seeping back into the spine and affecting other nerves. The risks of surgical treatment include neurological deficits, infection and inflammation, spinal headache, urinary disturbances, and leakage of cerebrospinal fluids¹¹.

Surgical treatment should be considered if all other symptom-relieving options have been exhausted. No current treatment has yet proven to be effective, due to the unclear pathogenesis and pathophysiology of Tarlov cysts, but microsurgical excision is preferable¹¹.

The current treatment options include CSF aspiration, complete or partial removal and

fibrin-glue therapy, among other surgical treatment approaches¹¹.

Perineural cysts are a very rare cause of radiculopathy, but they should be considered an important cause.

REFERENCES:

1. Donlin Long. The Johns Hopkins Hospital Dept. of Neurosurgery, interviewed by Hsuan Chen, Oct. 6th, 2009.
2. Goyal RN, Russell NA, Benoit BG, Belanger JM. Intraspinal cysts: a classification and literature review. *Spine* 1987; 12: 209-213
3. Guo DS, Shu K, Chen RD, Ke CS, Zhu YC, Lei T. Microsurgical treatment of symptomatic sacral perineural cysts. *Neurosurgery* 2007; 60(6): 1059-1065.
4. Hefti M, Landolt H. Presacral mass consisting of a meningocele and a Tarlov cyst: successful surgical treatment based on pathogenic hypothesis. *Acta Neurochirurgica* 2006; 148(4): 479-483.
5. Ju CI, Shin H, Kim SW, Kim HS. Sacral perineural cyst accompanying disc herniation. *J Korean Neurosurg Soc* 2009; 45 (3): 185-187.
6. Langdown AJ, Grundy JR, Birch NC. The clinical relevance of Tarlov cysts. *J Spinal Disord Tech* 2005; 18: 29-33.
7. Moldes MR, Rodriguez-Losada JS, Garcia DL, Agudo VC, Pais JM, Martin MG. Tarlov Cyst and Symptomatic Bladder Disfunction. *Actas Urologicas Espanolas* 2008; 32(10): 1035-1036.
8. Nabors MW, Pait TG, Byrd EB, Karim NO, Davis DO, Koblinc AI and Rizzoli HV. Updated Assessment and Current Classification of Spinal Meningeal cysts. *J Neurosurg* 1988; 68: 366-377.
9. Nadler SF, Bartoli LM, Stitik TP, Chen BQ. Tarlov cyst as a rare cause of S1 radiculopathy: A case report. *Arch Physical Med Rehab* 2001; 82(5): 689-690.
10. Singh PK, Singh VK, Azam A, Gupta S. Tarlov Cyst and Infertility. *J Spinal Cord Med* 2009; 32(2): 191-197.
11. Tao Z, Zhenhua L, Weiming G, Bingwei S, Shuheng L, Kai Z, Dezhen Y, Peng X, Tanghong J. Percutaneous fibrin glue therapy for meningeal cysts of the sacral spine with or without aspiration of the cerebrospinal fluid. *J Neurosur Spine* 2007; 7: 145-150.
12. Tanaka M, Nakahara S, Ito Y, Nakinishi K, Sugimoto Y, Ikuma H, Ozaki T. Surgical results of sacral perineural (Tarlov) cysts. *Acta Medica Okayama* 2006; 60(1): 65-70.
13. Tarlov IM. Perineural cysts of the spinal root. *Arch Neurol Psychiatry* 1938; 40: 1067-1074.
14. Tarlov IM. Spinal perineural and meningeal cysts. *J Neurol* 1970; 33: 10.