

SPLEEN RUPTURE AFTER ANTERIOR THORACOTOMY AND POSTERIOR INSTRUMENTATION FOR TUBERCULOSIS SPONDYLITIS

TÜBERKÜLÖZ SPONDİLİTİ TANISI İLE ANTERİOR TORAKOTOMİ VE POSTERİOR ENSTRÜMANTASYON YAPILAN HASTADA DALAK RÜPTÜRÜ

Alihan DERİNCEK*, Metin ÖZALAY**,
Murat ÇINAR*, Mustafa UYSAL**

SUMMARY:

Spleen rupture occurred in a 54 year old woman who underwent anterior thoracotomy and posterior instrumented fusion for T11-12 tuberculosis spondylitis. The spleen was also involved with necrotizing granulomatous inflammation. Splenectomy was performed for hemodynamic instability due to spleen rupture. Splenic rupture should be considered as part of the differential diagnosis for patients with hemodynamic instability after spinal surgeries.

Key words: Spleen, tuberculosis, anterior thoracotomy, spine

Level of evidence: Case report, Level IV

ÖZET:

54 yaşındaki bayan hastaya, T11-12 Tüberküloz spondilit tanısı ile anterior torakotomi + abse drenajı ve posterior enstrümantasyon uygulanmıştır. Ameliyat sonrası erken dönemde hemodinamik instabilite gelişen hastada dalak rüptürü saptanarak splenektomi uygulanmıştır. Patolojik incelemede sonrasında dalakta ilaveten nekrotizan granülomatöz inflamasyon saptanmıştır. Omurga ameliyatları sonrası gelişen hemodinamik instabilitelerde dalak rüptürü mutlaka akla getirilmelidir.

Anahtar Kelimeler: Dalak, tüberküloz, anterior torakotomi, omurga.

Kanıt Düzeyi: Olgu sunumu, Düzey IV.

(*) Ortopedi ve Travmatoloji Uzmanı, Başken Üniversitesi Tıp Fakültesi, Adana Hastanesi, Adana.

(**) Doç. Dr., Ortopedi ve Travmatoloji Uzmanı, Başken Üniversitesi Tıp Fakültesi, Adana Hastanesi, Adana.

INTRODUCTION:

Spleen trauma usually occurs after penetrating, non-penetrating or operative trauma. Indirect injury of the spleen after thoracotomy for spinal surgery is extremely rare. Tuberculosis as a cause of pathological spleen rupture has been described in a few case reports^(2,10-11).

CASE REPORT:

A 54-year-old woman presented to the hospital with dorsalgia, bilateral leg pain, fatigue and anorexia for 6 months. She had an arthroscopic meniscectomy for a year ago. Her sister was diagnosed as pulmoner tuberculosis 5 years ago.

On the physical examination; tenderness on mid-thoracic and upper lumbar area, paravertebral spasm, walking difficulties and bilateral babinski reflex were assigned. There was no motor and sensory deficit. Standard radiographs revealed fracture of T11. Magnetic Resonance Imaging also showed both right and left sided para-vertebral and anterior epidural abscess at T11 and T12 levels and pathologic fracture of the T11 (Figure-1,2). Increased uptake is obtained at the T11 and T12 levels at the bone scintigraphy. Sedimentation and CRP levels were increased to 80 and 47 respectively. White blood cell and thrombocyte count was normal. Preoperative hemotocrit was 33 %. Brucella agglutination test was negative but PPD test was positive. No active pulmoner tuberculosis was diagnosed.

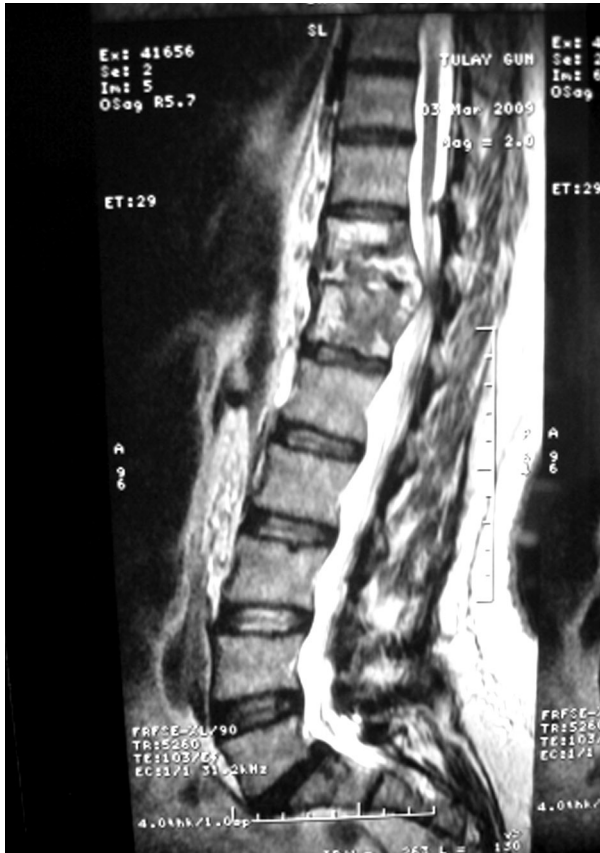

Figure-1

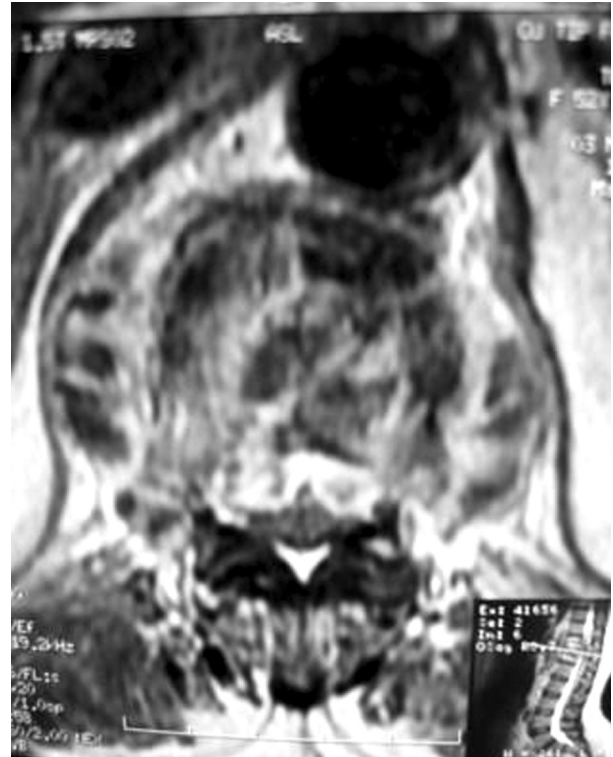

Figure-2

Figure-1,2. Sagittal and axial view of thoracolumbar MRI. Paravertebral and anterior epidural abscess at T11 and T12 levels and pathologic fracture of the T11.

After performing left anterior thoracotomy at the level of T10 rib, para-vertebral purulent material was drained under parietal pleura. Following infected soft tissue resection, T11-12 corpectomy+ expandable cage+ anterior instrumentation was completed. The surgeon did not need to thoraco-phreno-lumbotomy for instrumentation for this reason diaphragma was not dissected. Before the closure, 32 F chest tube was inserted. Following the anterior thoracotomy, the patient was repositioned in prone position. T8-L3 posterior midline incision was performed. Posterior instrumentation was completed with bilateral T9, T10, L1, L2 pedicle screws (under fluoroscopic control) and two rods. No inadvertent pedicle or anterior wall perforation was manifested. After instrumentation, T9-L2 posterior decortications was performed and 30 cc allograft was inserted. Before closure, a hemovac drain was inserted. The total operation time was 5 hours. The average amount of bleeding was 1000 ml. Four unite of erythrocyte suspension and 1 unite of fresh frozen plasma were given to the patient.

Postoperatively, the patient was extubated. She was cooperated and neurologically intact. She was admitted to the intensive care unit for close monitoring. Early postoperative hemotocrite was 30%. Due to the progressive hemotocrite decrease (30 to 25%) in 3 hours, massive erythrocyte suspension was started. At that time, patient was re-entubated and thoraco-abdominal computerized tomography (CT) was obtained (Figure-3). The spleen rupture was confirmed on abdominal CT and the patient underwent splenectomy in 4 hours after spinal surgeries. The spleen capsule was ruptured and spleen was pulled away from capsule that resulting in a profound intra-peritoneal bleeding was approximately

1500cc. During the splenectomy; the patient had successfull cardiac resuscitation because of cardiac arrest. After the second surgery, the patient was monitored in intensive care unit and plasmapheresis and pacemaker were applied. Death was occurred the day after surgery due to the second cardiac arrest.

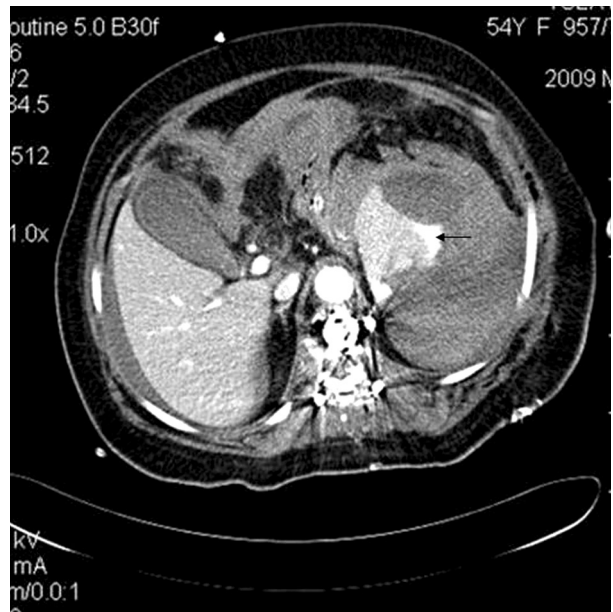


Figure-3. Axial contrast CT showing active spleen bleeding (arrow) and post-hemorrhagic hematoma around spleen.

The biopsy from anterior thoracal spine and spleen pathology had reported as necrotizing granulomatous inflammation (Pathology no: B.02876.09) and reactive lymphoid hyperplasia (Pathology no: B.02905.09) respectively. Both *Stafilococcus Aureus* and *Mycobacterium Tuberculosis* were identified in abscess culture. Polymerase chain reaction was also compatible with tuberculosis.

DISCUSSION:

The spleen has extreme fragility and vascularity therefore even minor trauma may cause significant bleeding especially if the spleen is enlarged or diseased. The spleen can get ruptured in the following circumstances: due to trauma to a diseased spleen; trauma to a normal spleen; spontaneous rupture of a diseased spleen (pathological rupture) and spontaneous rupture of a normal spleen (spontaneous rupture) ⁽⁹⁾. In this case, the cause of spleen rupture can be classified in trauma to a diseased spleen.

Spontaneous spleen rupture has been attributed to many causes that infections, hematologic conditions, metabolic disorders, malignancy, drug therapy or iatrogenic. Most common cause of pathologic spleen rupture are infectious mononucleosis and malaria ^(3,8-9). Tuberculosis may cause spontaneous spleen rupture but fortunately it is rare (10-11).

The first reported series of thoracotomies for transthoracic access to the spine were performed by Hodgson and Stock in 1956 for the treatment of spinal tuberculosis ⁽⁶⁾. Since then, advances in surgical technique and instrumentation have dramatically reduced the morbidity and mortality of this procedure, making it one of the first choices in many clinical situations. As a general rule, the upper thoracic spine (T2-9) is better approached from the right side because of the location of the heart, aortic arch and great vessels. Conversely, in the case of the thoracolumbar spine (T10-L2) a left-sided thoracotomy is preferred to avoid liver retraction. The main disadvantage of this procedure is related to the potential pulmonary morbidity of a thoracotomy and the possible need for a second operation in case decompression and

stabilization of the posterior elements of the spine are needed.

The major complications of thoracotomy are pneumothorax, infection, air leaks, bleeding and respiratory failure. There is only one report in literature about splenic rupture as a complication after thoracotomy ⁽⁷⁾. In this case, Klotz et al did not find any explanation for spleen rupture after left side pulmonary lobectomy (T5 thoracotomy). There was no pathologic process in spleen and no evidence of an iatrogenic injury of the diaphragm. We also did not observe any injury of the diaphragm during anterior thoracotomy.

Use of the anterior thoraco-lumbar approach in spinal deformity surgery has become increasingly popular in recent year. However, numerous possible complications, including injury to vital intra-abdominal structures such as bowel, ureter, aorta, vena cava etc. can be occurring. The incidence of spleen injury after anterior thoraco-lumbar surgery is unknown. Based on literature search, there are only 4 cases with spleen rupture after anterior spine surgery. Hodge et al reported 2 spleen injuries in 1983. One of the cases was noticed during anterior surgery and treated at the same time. The authors recommended that check the spleen for hemorrhage by direct observation during the procedure ⁽⁵⁾. Heyworth et al also reported a spleen rupture after anterior thoraco-lumbar scoliosis surgery ⁽⁴⁾. Even no exact reason was found for the spleen rupture, they estimated that traction of the spleen or its adjacent viscera caused avulsion of one of the vessel in the suspensory ligaments of the spleen. The last case was recently reported by Sin et al ⁽¹²⁾. Large metallic retractor blades which placed against to visceral organs were accused for spleen injury.

A 14 years old girl with Marfan syndrome who operated for scoliosis had spleen rupture after posterior spinal surgery was reported by Christodoulou et al ⁽¹⁾. The authors had strong confidence that the injury was not caused by the blunt-ended instruments or screws. They believed that visceral capsular tears from adhesions secondary to scoliosis correction-traction or intra/postoperative positioning of the patient.

In the current case; we applied traction on thoracotomy side with using large metallic retractor blades. The incision was not extended to the lumbar retroperitoneal area so intra-abdominal organs were free from the retraction. No anterior vertebral body penetration was occurred during posterior pedicle screw insertion. On the other side, necrotizing granulomatous inflammation could have caused more sensitive spleen to the minor trauma. However, we are in doubt about the cause of spleen rupture due to over retraction of the retractor blades.

Spleen rupture is a rare but potentially deadly complication after spinal surgeries. Spine surgeon should keep in mind when using the anterior approach should consider intermittent release of retractors, avoiding overretraction and suggest the spleen rupture in case of postoperative progressive anemia.

REFERENCES:

1. Christodoulou AG, Ploumis A, Terzidis IP, Timiliotou K, Gerogianni N, Spyridis C. Spleen rupture after surgery in Marfan syndrome scoliosis. *J Pediatr Orthop* 2004; 24(5): 537-540.
2. Debnath D and Valerio D. Atraumatic rupture of the spleen in adults. *J R Coll Surg Edinb* 2002; 47: 437-445.
3. Gedik E, Girgin S, Aldemir M, Keles C, Tuncer MC, Aktas A. Non-traumatic splenic rupture: report of seven cases and review of the literature. *World J Gastroenterol* 2008; 21; 14(43): 6711-6716.
4. Heyworth BE, Schwab JH, Boachie-Adjei OB (2008) Case reports: splenic rupture after anterior thoracolumbar spinal fusion through a thoracoabdominal approach. *Clin Orthop Rel Res* 2008; 466(9): 2271-2275.
5. Hodge WA, DeWald RL. Splenic injury complicating the anterior thoracoabdominal surgical approach for scoliosis: a report of two cases. *J Bone Joint Surg* 1983; 65-A: 396-397.
6. Hodgson AR, Stock FE. Anterior spinal fusion: a preliminary communication on the radical treatment of Pott's disease and Pott's paraplegia. *Br J Surg* 1956; 44: 266-275.
7. Klotz S, Semik M, Senninger N, Berendes E, Scheld HH. Spontaneous splenic rupture after a left-side thoracotomy: report of a case. *Surg Today* 2003; 33(8): 636-638.
8. Mokashi AJ, Shirahatti RG, Prabhu SK, Vagholkar KR (1992) Pathological rupture of malarial spleen. *J Postgrad Med* 1992; 38(3):141-142.
9. Nicholl J, McAdam G, Donaldson D. Three cases of early spontaneous splenic rupture associated with acute viral infection. *J R Coll Surg Edin* 1993; 38 (6): 351-352.
10. Ram R, Swarnalatha G, Prasad N, Murty KV. Pathological rupture of spleen in a haemodialysis patient due to tuberculosis. *Nephrol Dial Transplant* 2006; 21(10): 2994-2995. Epub 2006 Jul 22.
11. Safioleas MC, Stamatakos MC, Safioleas CM, Diab AI, Agapitos EB. Co-existence of spontaneous splenic rupture and tuberculosis of the spleen. *Saudi Med J* 2006; 27(10): 1588-1590.
12. Sin A, Smith D, Nanda A. Iatrogenic splenic injury during anterior thoracolumbar spinal surgery. Case report. *J Neurosurg Spine* 2007; 7(2): 227-229.

