

CORRECTION OF THE RIB-HUMP and HRSF APPLICATION AT THE SAME STAGE IN THORACAL SCOLIOSIS

M. F. Akyıldız

In thoracal and thoracolumbar scoliosis, the first aim was always the correction of the lateral curve and thus the rib prominence remained uncorrected usually. The use of costectomy before or after Harrington Instrumentation for better correction versus cosmetic advantages was reported by several authors. In the following article the advantages of costectomy at the same stage with the Harrington Instrumentation in thoracal scoliosis for better correction and some other facilities are noticed.

CORRECTION OF THE RIB HUMP is the partial resection of the ribs at the apex of the prominence, causing the hump deformity. The technique is described below.

Costectomy and Harrington Inst, is done AT THE SAME STAGE to reduce the number of operations for better correction, the latter applied secondly. HRSF term is been used in general, thus only the distraction rod is applied, not the compression potion because of rib resection.

The role of costectomy in the management of scoliosis has been discussed for many years. Most authorities consider that either a single stage Harrington procedure (5) with spinal fusion or Luque posterior instrumentation is a satisfactory choice in most cases of scoliosis which need operation. Manning, Prime and Zorab (9) and Owen, Turner and Bbamforth (11) have found that many patients, particularly adolescent girls continue to complain about their rib prominence even after their scoliosis has been well corrected at operation. Neither the patient nor the parents ever want to see the rib hump remained as a psychological and cosmetic embarrassment. Moreover many patients complain of neuralgic pain associated with the scar produced by taking bone grafts from the iliac crest.

Excision of rib prominence before Harrington Inst, has some advantages. First; direct excision of the rib prominence has a cosmetic advantage and helps better correction of the spinal curve.

Second; the excised rib sections are used as grafts in a quite sufficient value and the need for a separate incision over the iliac crest is avoided.

Third; if costal periosteum is repaired carefully, the new forming ribs will remodel a better shaped symmetrical thorax.

The disadvantages are thorax complications such as Haemolhorax, Rncumothorax and intercostal neural-

gia. But these are also very rare and not more than usual complications of HRSF procedure alone.

The other complication is the increased generalized osteoporosis caused by the short additional period of recumbency necessitated by costectomy if it is done a few weeks before HRSF as a two stage operation like reported by some authors. The last disadvantage is eliminated by applying the two procedures one after the other at the same stage. Also I believe that the increase in the number of the operation from two to one is a matter of choice both related with the shortened period in recumbency and inhaling anesthetics. On the other hand the scar of the preliminary operation may be vulnerable to pressure from a localizer cast and also the two operation at the same stage would be more traumatic. These are discussed later.

MATERIALS AND METHODS

Three patients were operated between 1987 and 1990. Two were girls one was a boy. Ages between 12-24. All of the types were idiopathic and single thoracic curves, one thoraco-lumbar. The mean number of ribs removed was 4 (range 3 to 5). The highest rib removed was the fifth and the lowest was the eleventh. The instrumentation was applied between T4 the high of the patients made satisfactory recovery, one had respiratory problems in the post-operative 24 hours, but then returned to normal functions. Procedure : The patient is placed prone on operation table.

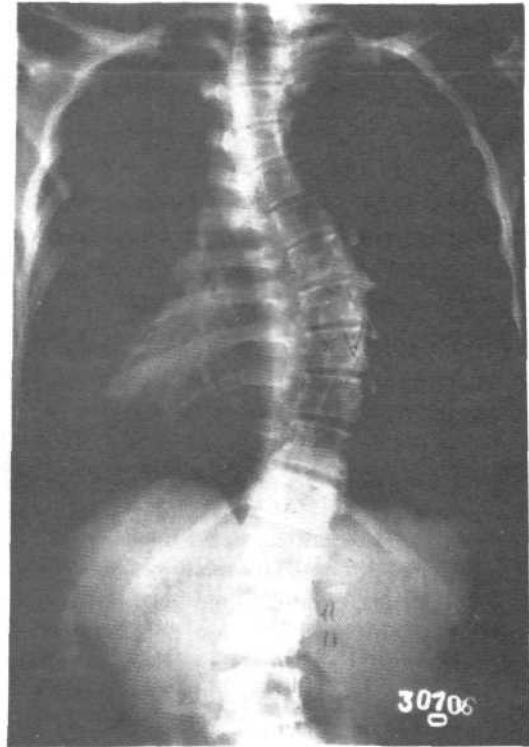
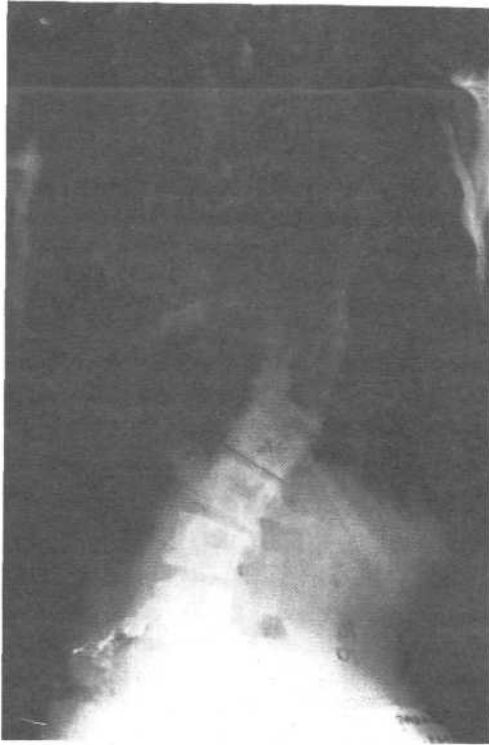

Fig. 1 Pre-operative roentgenograms of a 14 year old girl with 56° lying and 39° bending Cobb angle.

The skin is incised obliquely along Langcr's line over the apex of the rib prominence after infiltrating 1:500.000 Adrenalin solution. Take care not to reach the medial end of incision to the mid line so that the incision of spinal fusion won't cut each other. So far the triangular flap of skin between the two incisions won't go necrosis. Subcutancus tissue and muscle arc cut with elecrokoter to the bone. The periosteum is elevated carefully with a minimal damagc. Ribs arc exposed on either side of the apex of the prominence and a section of each prominent rib is excised from the posterior axillary line laterally to the neck of the rib medially, leaving the head of the rib or the medial portion may be disarticulated. But we prefare not to disarticulate bcacuse if the periosteum could be repaired carefully, the recent cases had shown that the defect caused by resection is reformed after about three months.

The wound is closed as usual and the excised ribs are prepared as grafts by cutting into chips. After then the midline incision is done for the Harrington Instrumentation and Spinal Fusion. As declared before only distraction rod is used because sufficient correction could be possible after rib resection.

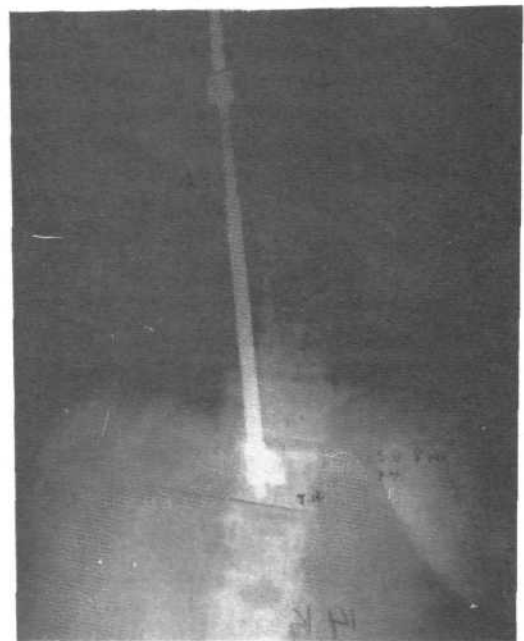


Fig.2 : The post-operative roentgenograms showing the resected ribs and the 30° Cobb angle.

RESULTS

One patient 14 year old girl had respiratory problem, like as dispne and high body temperature, (38.9°C) after 24 hours she became stabil. All the three patients were taken in Risser's localizer cast at the post operative fourteenth day when the skin sutures were taken off. No deep superficial infection is seen early or late. Cobb angle is measured pre and post operatively is shown on the table below. In every case the post-op angle is lesser than the preoperative bending roentgenograms.

Age sex	Fusion Area	pre-op Cobb-ang	post-op Cobb-ang	bending Cobb-ang	resected rib number	Correction %
12	T4-T12	44	24	31	4	55
14	T5-T12	56	30	38	3	53.5
24	T5-L1	59	34	40	5	57.6

DISCUSSION

Weatherley et. al. (1987) have a research on 47 patients with scoliosis and have regarded that inspite the reduction of the Cobb angle about 48 % after Harrington Inst., the rib hump correction is not satisfactory. Moreover there is an increase in rib deformity. Roaf (1966 and Manning (1973) have reported the use of costectomy as a cosmetic procedure after a spinal fusion and the the end of growth. Owen and Turner have reported have repoted in 42 children with preliminary costectomy a few weeks before Harrington Inst, and showed with CT scans at the level of a thorasic scoliosis before and after posterior instrumentation that the rib prominence remains unchanged. So they preferred two-stage operation, with costectomy as the first stage. They have done respiratory function tests and advice that if the curve is more than 70°, costectomy should be at risk because it reduces the total lung capacity and forced expiratory volume a little. Steel (1983) have reported in 370 patients the similar method to us and the most serious problem hacmothorax. After that he begin to use pleural drainage routinely like Owen does. He had one death from hypcrprxia and six pneumothorax who needed thorax drainage. I agree him that the procedure gratifying to note a modest improvement in pulmonary function whether from correction of the curve or excision of the rib segments, or both. Costectomy is of course applicable only to the management of thoracic curves being of no value for curves which arc mainly lumbar. When rib prominence is mild or minimal, the single-stage Harrington

or Luque instrumentation should be chosen. Cotrell-Debussy Inst, can produce some deratation of the apical thoracic vertebral bodies but in a patient with a rigid thoracic cage, derotation alone may leave the patient with a remark able prominence of the ribs.

The theoretical disadvantage of two-stage operation is increased Generalized osteoporosis, caused by the short additional period of recumbency necessitated by costectomy and the General Anesthesia for two times in a short period led me to operate at the same stage.

REFERENCES :

- Birch J.G., Hecring J.A. Cotrell-Dubouset Instrumentation in Idiopathic Scoliosis. Clin. Orthop. 227 : 24, 1988.
- Bunch W.H. Patient References in Surgery for Scoliosis. JBJS.1985; 67-A, 794-799.
- Christodoulou A.C., Prince H.G. Adolescent idiopathic Scoliosis JBJS (Br) 1987; 69-B:13-16
- Gertbein S.D. Macmichael D. Harrington Instrumentation as a Method of fixation in Fractures of the Spine. JBJS (Br) 1982; 64-B:526.
- Harrington P.R. The History and Development of Harrington Instrumentation. Clin. Orthop. 227:s, 1988.
- Harrington P.R. Treatment of Scoliosis: Correction and Internal Fixation by Spine Instrumentation. JBJS (Am)1962; 44-A:591-619.
- Jefferson R.J., Wersz I., Turner A.R. Scoliosis Surgery and its effects on Back Shape. J.BJ.S.(Br) 1988; 70-B, 261-266.
- Lovallo J.L., Banta J. V. Adolescent Idiopathic Scoliosis Treated by Harrington Rod Distraction and Fusion JBJS. 1986;68-A:1326-1330
- Manning C.W., Prime I.J., Zorab P.A. Partial Costectomy as a Cosmetic Operation in Scoliosis. JBJS (Br) 1973; 55-B:521-527
- Moe J.H., Winter R.B., Bradford D.S. Scoliosis and other Spinal Deformities, W.B. Saunders. 1978. Philadelphia and London.
- Owen R., Turner A. Costectomy as the First Stage For Scoliosis. JBJS(Br) 1987; 68-B : 91-95.
- Steel H.H. Rib Resection and Spine Fusion in Correction of Convex Deformity in Scoliosis. JBJS. 1983; 65-a : 920 - 925
- Thulboirne T., Gillespie R. The Rib Hump in Idiopathic Scoliosis. JBJS(Br) 1976; 58-B : 64-71.