

Conjunctival Necrosis Due to Subconjunctival Depot Corticosteroid Injection

Subkonjonktival Depo Kortikosteroid Enjeksiyonuna Bağlı Konjonktiva Nekrozu

Melis Palamar, Helin Yıldız, Sait Eğrilmez, Ayşe Yağcı

Department Of Ophthalmology, Ege University Faculty Of Medicine, Izmir, Turkey

Summary

This report describes an uncommon complication of subconjunctival corticosteroid injection. A 34-year-old male had undergone primary corneal suturing and crystalline lens aspiration due to trauma in his right eye. At the end of the surgery, subconjunctival methylprednisolone acetate was injected. At a follow-up visit five days later, biomicroscopic examination revealed conjunctival necrosis at the site of corticosteroid injection. Topical antibiotherapy resulted in complete healing. Ophthalmologists should always keep in mind that subconjunctival corticosteroid injection may lead to conjunctival necrosis. (*TOD Journal 2010; 40: 248-9*)

Key Words: Complication, corticosteroid, necrosis, subconjunctival injection

Özet

Bu sunu subkonjonktival kortikosteroid enjeksiyonunun nadir bir komplikasyonunu tanımlamaktadır. Travma nedeniyle 34 yaşında bir erkek olgunun sağ gözüne primer kornea sütürasyonu ve kristalin lens aspirasyonu uygulandı. Cerrahi bitiminde subkonjonktival metilprednizolon asetat enjekte edildi. Beş gün sonraki kontrolde, biyomikroskopik muayenede kortikosteroid enjeksiyonu yapılan alanda konjonktiva nekrozu izlendi. Topikal antibiyoterapi ile tam düzelme sağlandı. Oftalmologlar subkonjonktival kortikosteroid enjeksiyonunun konjonktiva nekrozuna yol açabileceğini her zaman göz önünde bulundurmalıdırlar. (*TOD Dergisi 2010; 40: 248-9*)

Anahtar Kelimeler: Komplikasyon, kortikosteroid, nekroz, subkonjonktival enjeksiyon

Introduction

Periocular corticosteroid injections are widely used after intraocular surgery and in the treatment of resistant inflammatory ocular diseases. The most frequently faced complications of corticosteroid injections are increased intraocular pressure and cataract formation. There are only few reported cases of conjunctival necrosis due to subconjunctival injection of corticosteroids (1-4).

We describe a case of conjunctival necrosis at the site of depot corticosteroid injection after surgery for penetrating trauma and lens capsule rupture.

Case Report

A 34 year-old otherwise healthy male underwent corneal primary suturing and crystalline lens aspiration combined with anterior vitrectomy for penetrating corneal injury in his right eye. As the posterior lens capsule was not intact and there was intraocular hemorrhage, intraocular lens implantation was postponed. At the end of the operation, subconjunctival methylprednisolone acetate suspension (Depo-Medrol, Pharmacia & Upjohn, Kalamazoo, MI) 20 mg in 0.5 ml

Yazışma Adresi/Address for Correspondence: Dr. Melis Palama, Ankara Cad. 35040, İzmir, Türkiye

Gsm: +90 530 408 50 51 Tel.: +90 232 390 37 88 E-posta: melispalamar@hotmail.com **Geliş Tarihi/Received:** 06.04.2010 **Kabul Tarihi/Accepted:** 26.05.2010

was injected under the inferior bulbar conjunctiva. The patient was discharged with dexamethasone and tobramycin 0.3% eye drops six times daily. Five days later, the conjunctiva overlying the subconjunctival depot corticosteroid injection appeared white, with cheesy material, and showed positive staining with fluorescein. Conjunctiva seemed to be inflamed and necrotic. The surrounding vessels were markedly congested (Figure 1A). A swab of the area was sent for culture and the result revealed growth of neither bacteria nor fungi. We did not debride the lesion, but prescribed tobramycin 0.3% ointment three times and artificial tear drops four times daily. After a follow-up of 4 weeks, the involved area healed completely with a small fibrotic scar formation (Figure 1B,C,D).

Discussion

Periocular corticosteroid injections are often used after intraocular surgery and various inflammatory ocular diseases. The main potential side effects are ocular hypertension and cataract formation. However,

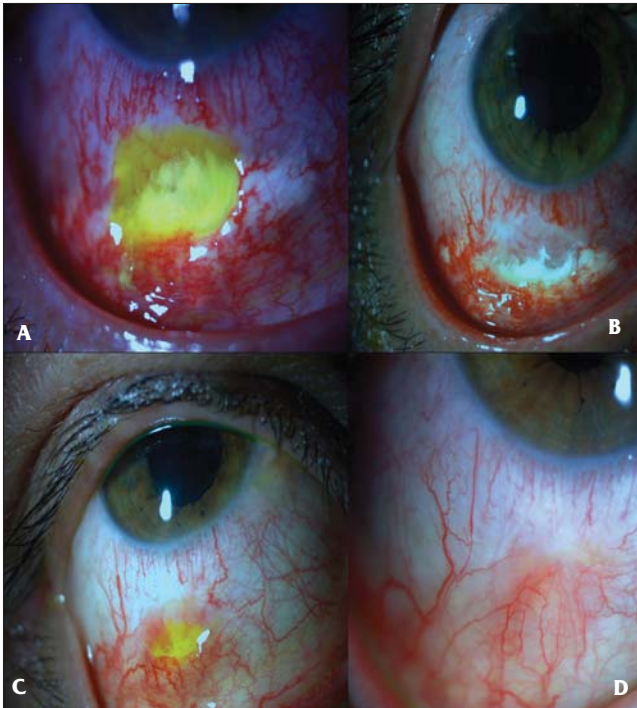


Figure 1. A 34 year-old male had undergone primary suturing for a penetrating eye injury. **a)** On postoperative 5th day, the conjunctiva overlying subconjunctival depot corticosteroid injection is covered with white cheesy material with positive fluorescein staining. Conjunctiva is inflamed and necrotic with dilated surrounding vessels. **b)** On postoperative 8th day, the cheesy material is less and the borders are more well-defined. **c)** The necrotic area is covered with fibrotic tissue in postoperative 5th week. **d)** The fibrotic scar is smaller in postoperative 6th week

conjunctival necrosis after corticosteroid injection has been reported in 5 patients with methylprednisolone (1-3), 2 patients with triamcinolone acetonide (3,4), and in 1 patient with betamethasone (5). Our patient is the next case of conjunctival necrosis due to subconjunctival methylprednisolone acetate injection.

In a recent study, [3H]-thymidine uptake in keratocytes was performed to estimate the effects of corticosteroid eye drops on cellular proliferation and thymidine uptake was found to be inhibited when treating the cells with corticosteroid eye drops (6). Although the mechanism of conjunctival necrosis following corticosteroid injection is not known, it might be related to the inhibition of thymidine uptake. Besides the delay of the healing due to corticosteroid therapy, a direct toxic effect of the corticosteroid is also proposed (2). Although we did not excise the necrotic tissue, the lesion healed without any problem. Therefore, an invasive approach is not always necessary in cases of conjunctival toxic necrosis due to corticosteroid injection. Follow-up with topical antibiotherapy is usually enough for the treatment. Although no growth in culture was detected, we still cannot exclude the possibility of infection in our case. However, it is not possible for us to know the exact mechanism of the necrosis. Unfortunately, we cannot predict in whom conjunctival necrosis will develop.

Subconjunctival injections of corticosteroids, particularly methylprednisolone, may lead to conjunctival necrosis, and ophthalmologists should be aware of this potential complication when injecting corticosteroids under the bulbar conjunctiva.

References

1. Kim T, Rapuano CJ, Romdan RC, Vander JF, Cohen EJ. Conjunctival necrosis following the administration of subconjunctival corticosteroid. *Ophthalmic Surg Lasers*. 1998;29:779-80. [Abstract]
2. Zamir E, Pe'er J. Necrotizing conjunctival ulceration following subconjunctival depot methylprednisolone injection. *Ophthalmic Surg Lasers*. 1999;30:565-6. [Abstract]
3. Fogla R, Rao SK, Biswas J. Avoiding conjunctival necrosis after periocular depot corticosteroid injection. *J Cataract Refract Surg*. 2000;26:163-4. [Full Text] / [PDF]
4. Allen QB, Lowder CY, Meisler DM. Conjunctival necrosis following the administration of subconjunctival corticosteroid (correspondence). *Ophthalmic Surg Lasers*. 1998;29:779-80. [Abstract]
5. Güngör IU, Beden Ü, Erkan D. Conjunctival necrosis due to subconjunctival injection of betametasone in treatment of graft rejection after penetrating keratoplasty. *Ophthalmic Surg Lasers*. 2005;36:348-9. [Abstract]
6. Wu K-Y, Wang H-Z, Hong S-J. Effects of antibiotics and corticosteroid eye drops on cellular proliferation in cultured human corneal keratocytes. *Kaohsiung J Med Sci*. 2006;22:385-9. [Abstract] / [PDF]