

## Multiple Pigmented Basal Cell Carcinomas - Case Report

Safa Suleman Elfaituri

Address: <sup>1</sup>Benghazi University, Dermatology Department, Benghazi, Libya

E-mail: selfaitoury@yahoo.co.uk

\* Corresponding Author: Dr. Safa Suleman Elfaituri, Western Fwayhat, Benghazi, Libya, 2026 Benghazi, Libya

Published:

J Turk Acad Dermatol 2016; **10 (2)**: 16102c7

This article is available from: <http://www.jtad.org/2016/2/jtad16102c7.pdf>

**Keywords:** Multiple basal cell carcinomas, elderly man

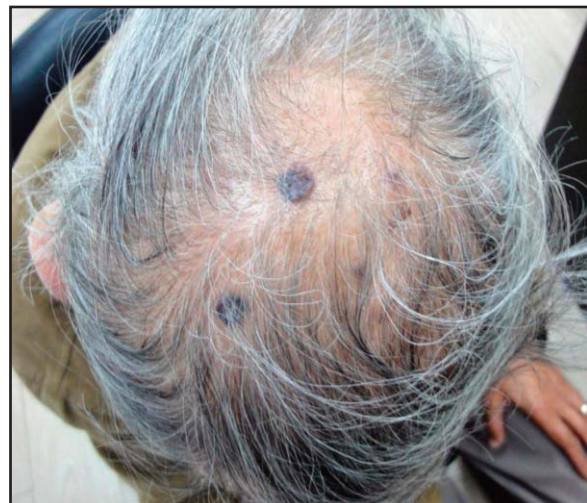### Abstract

**Observation:** Basal cell carcinoma is the most frequent skin cancer. It is observed mainly among elderly. We report a healthy 77-year-old Libyan man who presented with numerous pigmented basal cell carcinomas on his scalp. He had no history of irradiation, arsenic intake, or exposure to chemicals. There was no family history of skin cancer, xeroderma pigmentosum, or basal cell nevus syndrome. This is unusual case report of non-familial nonsyndromic multiple pigmented basal cell carcinomas in a Libyan man without any predisposing risk factors.

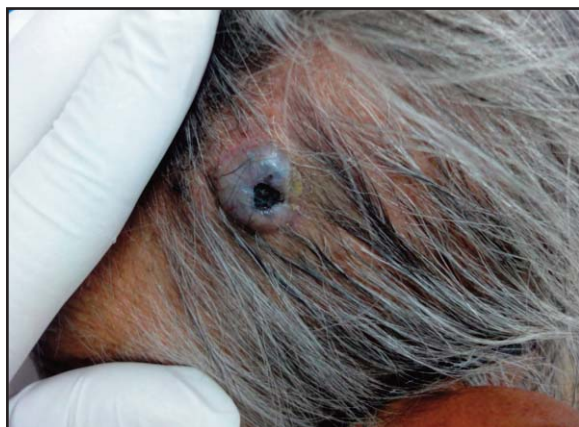### Introduction

Basal cell carcinoma (BCC) is the most common skin malignancy. It is most common among the elderly and most prevalent among Caucasians [1]. It normally has slow growth and low aggressiveness and rarely generates metastases, but it may invade locally and can result in extensive morbidity through local recurrence and tissue destruction [2,3]. There are different clinical forms which range in aspect and malignant potential, the most frequent one is nodular or nodular-ulcerative, other forms include superficial, morpheiform, micronodular, cystic and pigmented [2]. The pigmentation can be found in different clinical types, and the color varies from dark brown to black. Histopathology shows nests of basaloid cells, abundance of melanin and melanophages, and moderate inflammatory infiltrate [2]. Exogenous factors including chronic exposure to ultraviolet radiation and exposure to ionizing radiation, arsenic, industrial chemicals are considered to be predisposing factors in the development of multiple BCCs [3,4].

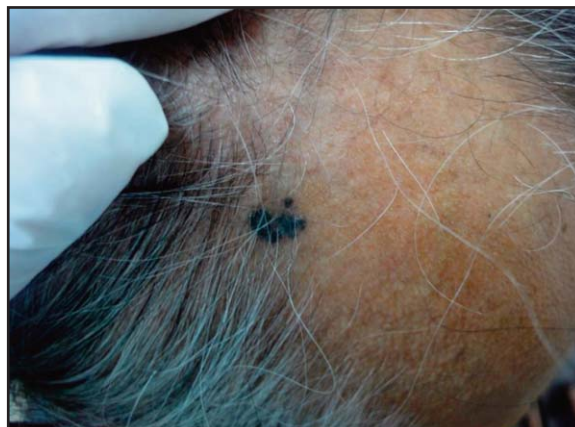Multiple BCCs are often linked to some genodermatosis, including Gorlin syndrome and xeroderma pigmentosum. A nonsyndromic type of hereditary multiple BCC was postulated recently [4].



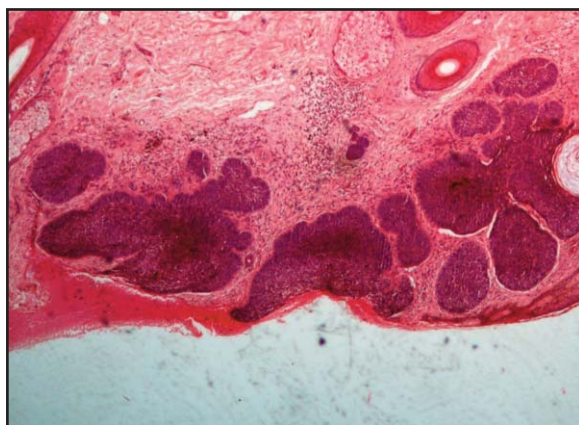
**Figure 1.** Multiple pigmented basal cell carcinomas in the scalp



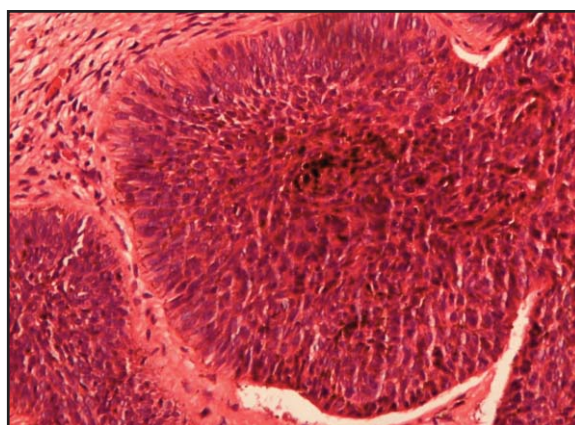
**Figure 2.** Pigmented nodulocystic basal cell carcinomas in scalp



**Figure 3.** Pigmented basal cell carcinomas in anterior scalp



**Figure 4.** Histopathology of the lesion in fig.3. (Low power)



**Figure 5.** Histopathology of the lesion in fig.3. (High power)

### Case Report

The patient had first noted a nodular pigmented lesion on his scalp 10 years previously. The tumor was excised and the pathological diagnosis was BCC. A recurrent lesion developed at the same site 5 years later and since then, other lesions had appeared in many locations on his scalp. He was otherwise healthy and without any history of exposure to arsenic, chemicals or radiation. He did not use to work under direct sunlight. There was no family history of skin cancer, xeroderma pigmentosum, or basal cell nevus syndrome. On examination, multiple (eleven) pigmented variable-sized papules, small plaques and nodules were present on his scalp. These lesions could be differentiated as nodulocystic and pigmented clinical variants of BCC (**Figures 1,2 and 3**).

Biopsy specimen showed pigmented basal cell carcinomas (**Figures 4 and 5**). Clinical workup including chest radiography, abdominal ultrasound, and brain computerized axial tomography scan did not demonstrate primary or secondary tumors.

The results of serologic and hematologic tests were within normal limits.

### Discussion

Basal cell carcinoma (BCC) is the most common malignancy in humans and it is the most common of all skin cancers [1]. It is originating in the basal cell layer and accounting for up to 70% of all cancers arising from the epidermis [2]. Although it usually occurs as a single lesion, the occurrence of multiple lesions either simultaneously or subsequently is not uncommon. Characteristically, BCC develops on sun-exposed areas, mainly on the face and neck; however, it can occur anywhere, even in covered areas [3]. Chronic exposure to ultraviolet light especially UVB trigger mutations in tumor suppressor genes P53 and PTCH in the keratinocytes resulting in BCC [2,3,5].

Exposure to ionizing radiation, arsenic, industrial chemicals as vinyl chloride, polycyclic aromatic hydrocarbonates, and alkalizing agents may cause multiple BCCs by mutations in regulatory genes [2,3]. Immune system suppression has a role in the pathogenesis of skin carcinomas since the incidence of BCC increased among immune suppressed patients [2]. Multiple basal cell carcinomas (BCCs) are often a feature of genetic syndromes including nevoid BCC syndrome, xeroderma pigmentosum, Bazex syndrome, Muir-Torre syndrome and Rombo syndrome. Syndromic BCCs have characteristic tendency for development at an early age. The genetic analysis of patients with Gorlin syndrome shows mutations in PTCH1 gene located in 9q22.3. A new autosomal dominant nonsyndromic type of multiple BCC was postulated by Happle [4]. This type is characterized by multiple superficial BCC without associated anomalies, and it was reported in several families. Unlike syndromic and sporadic BCC, the PTCH1 mutation is absent in hereditary multiple nonsyndromic BCCs. In addition there are case reports of unilateral multiple superficial BCC, suggesting somatic mosaicism which is difficult to explain without the consideration that nonsyndromic multiple superficial BCC may occur as a distinct mendelian trait [4]. Our patient presented with multiple pigmented BCCs, all were located in scalp and were developed late in life, and there were no associated syndromic anomalies. His BCCs can't be explained by chronic sun exposure, or arsenic intoxication.

Absence of family history and presence of nodulocystic lesions make the diagnosis of hereditary multiple nonsyndromic BCCs unlikely. *Chaturvedi Pankaj* et al was reported a similar case of nonsyndromic, nonhereditary multiple BCCs in an elderly Indian man; BCCs were arising from actinic keratoses on the face, neck and chest and were of superficial, nodular, pigmented and morpheaform clinical variants.

### Conclusion

We present unusual case of multiple pigmented BCC in scalp of an elderly man which was nonsyndromic, nonfamilial and occurring in the absence of environmental predisposing factors.

### References

1. Shoji T, Lee J, Hong SH, et al. Multiple pigmented basal cell carcinomas. *Am J Dermatopathol* 1998; 20: 199-202. PMID 9557792
2. Dourmishev LA, Rusinova D, Botev I. Clinical variants, stages, and management of basal cell carcinoma. *Indian Dermatol Online J* 2013; 4: 12-17. PMID: 23439912
3. Pankaj C, Amit G, Anil D'C, Prathamesh P, Devendra C, Gouri P. Nonsyndromic Type of Multiple Basal Cell Carcinoma. *Int J Head Neck Surg* 2010; 1: 25-28.
4. Happle R. Nonsyndromic type of hereditary multiple basal cell carcinoma. *Am J Med Genet* 2000; 95: 161-163. PMID:11078568
5. de Zwaan SE, Haass NK. Genetics of basal cell carcinoma. *Australas J Dermatol* 2010; 51: 81-92. PMID:20546211