

Hair Transplantation in Cicatricial Alopecia: A Preliminary Report

Iffat Hassan,^{1*} MD, Gousia Sheikh,¹ Zubair Abdullah,¹ MD, Shazia Jeelani,¹ Abid Keen,¹

Address: ¹Department of Dermatology, STD and Leprosy, Govt, Medical College, Srinagar (University of Kashmir) J&K, India

E-mail: hassaniffat@gmail.com

* Corresponding Author: Dr. Iffat Hassan, Department of Dermatology, STD and Leprosy, Govt, Medical College, Srinagar (University of Kashmir) J&K, India.

Published:

J Turk Acad Dermatol 2014; **8** (3): 1483a2.

This article is available from: <http://www.jtad.org/2014/3/jtad1483a2.pdf>

Key Words: Cicatricial alopecia, autologous hair transplant, follicular unit extraction

Abstract

Background: Cicatricial alopecia is an irreversible cosmetic insult resulting primarily from a disease or infection or secondarily from a physical injury. In recent times, the advent of hair transplantation has provided hope for patients suffering from cicatricial alopecia allowing great respite from the social embarrassment these people have to face at the hands of this disfiguring disease.

Objectives: To assess the feasibility of hair transplant in patients with cicatricial alopecia and evaluate the cosmetic improvement in terms of patient satisfaction.

Material and Methods: A total of 11 patients of cicatricial alopecia underwent autologous hair transplant by follicular unit extraction method over a period of 2 years.

Results and Conclusion: Hair transplant forms a feasible option for patients with cicatricial alopecia with excellent cosmetic results and high patient satisfaction.

Introduction

The term "cicatricial alopecia" refers to a scarring alopecia that results from a diverse group of disorders that destroy the hair follicle, replace it with scar tissue, and cause permanent hair loss, in otherwise healthy individuals [1]. Cicatricial alopecias are classified as primary or secondary. In primary cicatricial alopecias the permanent portion of the hair follicle (stem cells of the bulge area and the infundibulum) is the target of the destructive inflammatory process [2], and the cause varies from autoimmune diseases like lichen plano pilaris (LPP), discoid lupus erythematosus (DLE), pseudopelade of Brocq, to infections like folliculitis decalvans.

Secondary cicatricial alopecias, result from destruction of the hair follicle incidental to a non-follicle-directed process or external injury, such as burns, radiation, trauma or severe infections like tinea capitis [3]. Most of the conditions causing primary cicatricial alopecias are non scarring initially and can be controlled with proper timely institution of medical treatment [4]. However most of the patients present at a later stage when scarring is quite evident and the alopecia is irreversible.

Since hair loss leads to decreased self esteem and social embarrassment [5], there is an increasing psychological burden on affected individuals thus demanding active efforts at

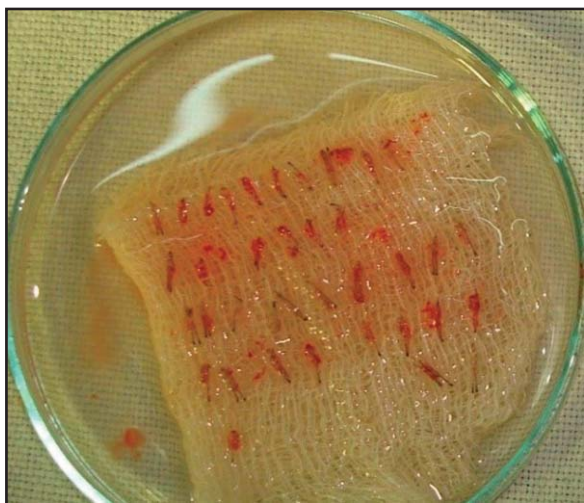

Figure 1. A series of follicular -units

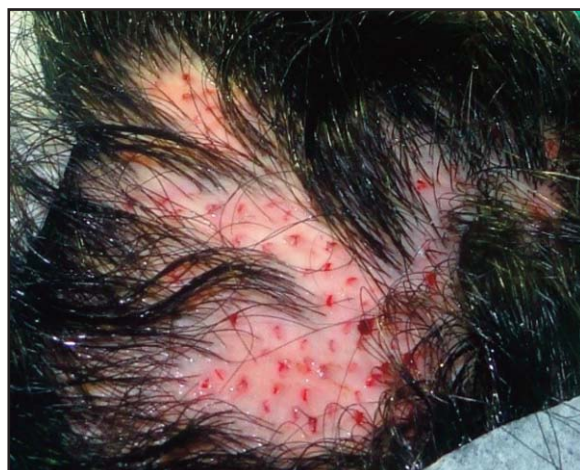

Figure 2. Implanted follicular units into the bottom of the micro-slot

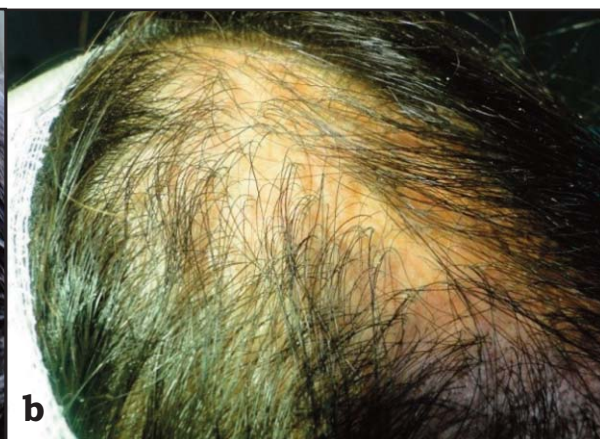
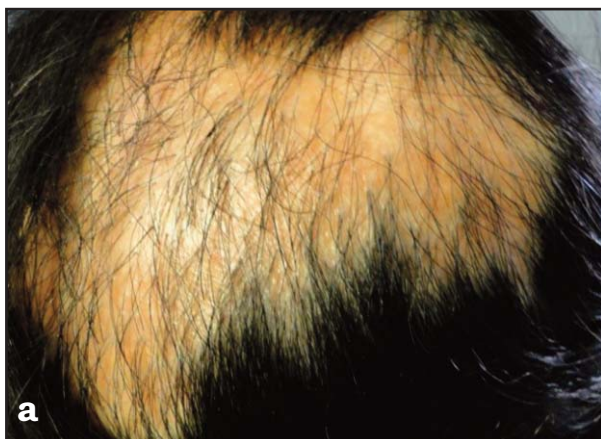

Figure 3. a) Pre-transplant picture; **b)** 1 year post transplant picture

treatment in these patients. In recent times, hair transplant has emerged as a promising and effective mode of treatment in patients of alopecia. However, in cicatricial alopecia, stability of the disease is an important consideration prior to providing the patient with the option of a hair transplant. A two year disease free remission is considered a prerequisite before taking up the patient for surgical treatment.

Materials and Methods

Eleven patients of cicatricial alopecia, with either primary or secondary alopecia, underwent hair transplant in our transplant unit over a period of 2 years from may 2010 to may 2012, by Follicular unit extraction method (Table 1). The patients with primary

alopecia taken up for surgery were the ones who had a stable disease for about 2 years and the patients of secondary alopecia were the ones in whom scar had already matured. The lesions involved 5-15 % of scalp and the size of the alopecia patches ranged from 4 cm² to 20 cm². Before taking up for surgery patients were evaluated for medical conditions with baseline hemogram, coagulogram, and hepatitis/retroviral serology.

The procedure was carried out under local anaesthesia using occipital region as the primary donor site. The patients were advised to trim the hair on the back of the head to 1-2 mm length on the day of the procedure. With the patient in prone position, on the operating table, the donor site was infiltrated with mixture of lignocaine and bupivacaine in normal saline, and grafts extracted with 0.9

Table 1. Alopecia and Treatment Results of the Patients

Cause of Alopecia	Age/Sex	Region involved	Area (cm ²)	Results
Post burn scar	27/M	Frontal	16	Satisfactory
Favus	16/M	Temporal	12	Good
Post burn scar	33/F	Parietal	20	Satisfactory
Pseudopelade of brocq	37/M	Parietal	9	Good
Lichen plano pilaris	28/F	Frontal	9	Good
Post traumatic scar	21/M	Eye brow	4	Excellent
Lichen plano pilaris	31/M	Temporal	12	Good
Post burn scar	28/F	Frontal	12	Good
Lichen plano pilaris	34/F	Parietal	8	Good
Post traumatic scar	26/M	Parietal	6	Good

mm to 1.2 mm special micropunch, with a two step procedure and preserved in saline. A series of follicular -units, each composing of 1-3 hair follicles were harvested from the occipital region of scalp (**Figure 1**). Size-matched micro-slots were made in the scarred recipient area with 16 - 20 G needles to accept the grafts. The prepared follicular-unit was synchronously implanted into the bottom of the micro-slot as the needle was being withdraw (**Figure 2**).

Results

The patients were followed for a period of 1 year months post procedure. (**Figures 3a, 3b**). There was an initial false growth of hair for 3-4 weeks which shed subsequently, and new hair reappeared after 3-4 months after procedure. The results were evaluated on the basis of patient satisfaction, where the patient graded the procedure, and marked it on a scale ranging from poor, satisfactory, good to excellent. The technique of harvesting and transplanting individual follicular-units by FUE is safe and effective method in cicatricial alopecia. It is particularly useful if the recipient area is small, like in many patients of cicatricial alopecia. The method is well accepted by patients as there is minimal pain, and a relatively faster recovery as compared to the usual hair transplant method as the donor area wound are very small.

Discussion

In cicatricial alopecia, scalp injury and scarring destroy hair follicles. If scalp scars are small, it is not a significant cosmetic problem. However, if the scars are large, some form of

hair restoration is generally warranted. There is not much of a medical management for such patients, but surgical modality like hair transplantation can provide cosmetically acceptable results [6]. As dermatologists we do not recommend hair transplantation if the disease is active and a minimum of two years of disease inactivity is advised before hair transplantation is undertaken. An important consideration in cicatricial alopecia is that a very limited and compromised blood supply exists [7]. The blood supply is assessed by sticking the scarred tissue and placing of test grafts. While doing a transplant in hypertrophic scars, the grafts should be placed deeper and in atrophic scars incisions for the graft placement should be made at more than usual acute angles. In general, multiple smaller sessions are more successful. Follicular unit extraction is preferred as it obviates the need for a linear incision, at the donor site and the small holes that remain at the donor site are left open to heal. Follicular unit extraction has led to improved graft survival and better cosmesis [8, 9]. Moreover, FUE needs less manpower, less equipment, minimal graft preparation and less post operative recovery time [10]. However, follicular unit extraction is technically demanding as there is an increased risk of follicular transection [11], inability to harvest all the hair from the mid portion of the donor area and not to speak of organizational limitations.

References

1. Ross EK, Tan E, Shapiro J. Update on primary cicatricial alopecias. J Am Acad Dermatol 2005; 53: 1-37. PMID: 15965418

2. Tan E, Martinka M, Ball N, Shapiro J. Primary cicatricial alopecias: clinicopathology of 112 cases. *J Am Acad Dermatol* 2004; 50: 25-32. PMID: 14699361
3. Sowjanya CL, Rao TN, Guruprasad P, Khopkar U. Clinico-pathological study of acquired primary cicatricial alopecias. *J Dr NTR Univ Health Sci* 2012; 1: 21-26.
4. Sperling LC, Solomon AR, Whiting DA. A new look at scarring alopecia. *Arch Dermatol* 2000; 136: 235-242. PMID: 10677100
5. Williamson D, Gonzalez M, Finlay AY. The effect of hair loss on quality of life. *J Eur Acad Dermatol Venereol* 2001; 15: 137-139. PMID: 11495520
6. Earles RM. Surgical correction of traumatic alopecia marginalis or traction alopecia in black women. *J Dermatol Surg Oncol* 1986; 12: 78-82. PMID: 3941194
7. Tyagi V, Singh PK. A new approach to treating scarring alopecia by hair transplantation and topical minoxidil. *Indian J Dermatol Venereol Leprol* 2010; 76: 215. PMID: 20228566
8. Wang JP, Fan JC, Chai JK. [The treatment of cicatricial alopecia after burn with the technique of synchronously perforating and transplanting hair follicular-units]. *Zhonghua Shao Shang Za Zhi* 2009; 25: 411-414. Chinese. PMID: 20193160
9. Meyer-Gonzalez T, Bisanga C. [Body-hair transplant for cicatricial alopecia]. *Actas Dermosifiliogr* 2012; 103: 163-164. PMID: 21872192
10. Dua A, Dua K. Follicular unit extraction hair transplant. *J Cutan Aesthet Surg*. 2010; 3: 76-81. PMID: 21031064
11. Harris JA. The SAFE System: New instrumentation and methodology to improve follicular unit extraction (FUE) Hair Transplant Forum Int 2004; 14: 163-164.