

Histopathological Survey on *Sarcocystis* Species Infection in Slaughtered Cattle of Zabol-Iran

Zabol-İran'da Kesilen Sığırlarda *Sarcocystis* Türlerinin Yol Açtığı Enfeksiyonlar Üzerine Histopatolojik İnceleme

© Ehsan Faghiri, © Aida Davari, © Reza Nabavi

University of Zabol Faculty of Medicine, Department of Pathobiology, Zabol, Iran

Cite this article as: Faghiri , Davari A, Nabavi R. Histopathological Survey on *Sarcocystis* Species Infection in Slaughtered Cattle of Zabol-Iran. Türkiye Parazit Derg 2019;43(4):182-6.

ABSTRACT

Objective: Sarcocystosis is an important zoonotic protozoal disease with worldwide distribution and wide range of hosts. The aim of the present study was to determine the intensity of *Sarcocystis* spp. infection and to show histopathological features of their cystic lesions in slaughtered cattle of Zabol- Iran.

Methods: From April to September 2018, 500 tissue samples from esophagus, heart, diaphragm, tongue and masticatory muscles were prepared from 100 slaughtered cattle. All samples were fixed in 10% neutral buffered formalin and routine tissue processing protocol was performed.

Results: The microscopic results showed that 92.2% of specimens had thin-walled cysts of *S. cruzi* and 14% had thick-walled *Sarcocystis* (*S. hirsuta* and *S. hominis*) but macrocyst was only observed in one cattle. The positivity rate of thin walled cysts was 58.8% for heart, 13.9% for masticatory muscles, 10.2% for tongue, 9.3% for esophagus and 7.8% for diaphragm. The positivity rate of thick walled cysts was 32.8% for esophagus, 28.6% for tongue, 22.9% for heart, 15.7% for masticatory muscles and 0% for diaphragm, which could represent either *S. hominis* or *S. hirsuta*. The most infected tissue was heart and the least infected tissue was diaphragm. Thin walled cysts (*S. cruzi*) were mostly found in heart and were less found in diaphragm. However, thick-walled cysts (*S. hirsuta* and *S. hominis*) were mostly detected in esophagus. No thick-walled cysts were found in diaphragm muscle .

Conclusion: A high positivity rate of sarcocystosis in slaughtered cattle in Zabol abattoir revealed heavily environmental contamination of Sistan region by this important parasitic disease.

Keywords: Cattle, sarcocystosis, thin-walled cyst, thick-walled cyst

ÖZ

Amaç: Sarkosistozis, dünya çapında yaygın bir dağılıma sahip ve çok çeşitli konakları olan önemli bir zoonotik protozoal hastalıktır. Bu çalışmanın amacı; Zabol-İran'da kesilen sığırlarda *Sarcocystis* spp. enfeksiyonunun yoğunluğunu belirlemek ve sarkosistosis kistik lezyonlarının histopatolojik özellikleri göstermektir.

Yöntemler: Nisan-Eylül 2018 tarihleri arasında kesilen 100 sığırın özofagus, kalp, diyafram, dil ve çiğneme kaslarından 500 doku örneği hazırlanmıştır. Tüm numuneler %10 nötr tamponlu formalin ile sabitlenmiştir ve tüm numunelere rutin doku işleme protokolü uygulanmıştır.

Bulgular: Mikroskopik sonuçlar, örneklerin %92,2'sinde *S. cruzi*'nin ince duvarlı kistleri, %14'ünde kalın duvarlı *Sarcocystis* (*S. hirsuta* ve *S. hominis*) olduğunu, ancak makrokistin sadece bir sığırdaki görüldüğünü göstermiştir. İnce duvarlı kistlerin pozitiflik oranı kalp için %58,8, çiğneme kasları için %13,9, dil için %10,2, özofagus için %9,3 ve diyafram için %7,8 idi. *S. hominis* ve *S. hirsuta*'yı temsil edecek şekilde kalın duvarlı kistlerin pozitiflik oranı özofagus için %32,8, dil için %28,6, kalp için %22,9, çiğneme kasları için %15,7 ve diyafram için %0 idi. En çok enfekte olan doku kalp ve en az enfekte olan doku diyaframdı. İnce duvarlı kistler (*S. cruzi*) çoğunlukla kalpte bulundu ve diyaframda en az bulundu. Ancak, özofagusta kalın duvarlı kistler (*S. hirsuta* ve *S. hominis*) tespit edildi. Diyafram kasında kalın duvarlı kist bulunmadı.

Sonuç: Zabol mezbahasında kesilen sığırlarda sarkosistosisin yüksek pozitiflik oranı, Sistan bölgesinin bu önemli paraziter hastalıkla ağır çevresel kontaminasyonunu ortaya çıkarmaktadır.

Anahtar Kelimeler: Sığır, sarkosistosis, ince duvarlı kist, kalın duvarlı kist



Received/Geliş Tarihi: 02.07.2019 Accepted/Kabul Tarihi: 26.08.2019

Address for Correspondence/Yazar Adresi: Aida Davari MD, University of Zabol Faculty of Medicine, Department of Pathobiology, Zabol, Iran
Phone/Tel: +98 5434822253 E-mail/E-Posta: davari.aida1@gmail.com ORCID ID: orcid.org/0000-0001-5598-4172

INTRODUCTION

Sarcocystosis is an important protozoan intracellular parasitic disease with global distribution in broad range of wild and domestic animal species as well as humans (1). *Sarcocystis* spp. have obligatory two-host life cycle and cause muscle cysts formation by merogony stage in herbivorous mammals (such as cattle, buffaloes, sheep and pigs) as intermediate hosts. Besides, sporogony and gamogony stages take place in carnivores and humans (by consumption of undercooked meat) as definitive hosts (2,3). In previous researches, three species of *Sarcocystis* have been reported in cattle: *S. cruzi*, *S. hirsuta*, and *S. hominis*, with canids, felids, and primates, as definitive hosts, respectively. Among these, *S. cruzi* with more than 90% prevalence in adult cattle cardiac muscle has the most occurrence reports in many countries in the world (4). *S. hirsuta* and *S. hominis* with less infection rates in comparison with *S. cruzi*, mostly have been found in esophagus and striated muscles (but less in cardiac muscle) (3,5); however, epidemiological reports have been scarce in the last few years. In Iran, there are only two reports about the occurrence of macroscopic type of sarcocystosis in cattle (*S. hirsuta*) (5,6).

Identification of *Sarcocystis* spp. is complicated. Although, molecular methods are insufficiently convenient for species identifications because of high genetic similarity; the ultrastructure observation of primary cyst wall technique is considered to be one possible reliable method for identifying *Sarcocystis* spp (6,7).

Based on the reports from different provinces of Iran, infection rate of sarcocystosis in adult bovine muscles is absolutely high (8-15), but there is no information about intensity of this parasitic disease in Sistan region. So, the present research aims to determine the intensity of infection and histopathological investigation of *Sarcocystis* spp. cystic lesions in slaughtered cattle of Zabol abattoir.

METHODS

Collection of Samples

From April to September 2018, 100 slaughtered cattle in Zabol industrial slaughterhouse were randomly examined for the presence of *Sarcocystis* macroscopically and microscopically. A total of 500 tissue samples with the size of 1x1x0.5 cm from esophagus, heart, diaphragm, tongue and masticatory muscles of these cattle were obtained.

This manuscript was conducted on slaughtered cattle and does not contain clinical or experimental studies and patient data.

Microscopic Examination

All specimens were fixed in 10% neutral buffered formalin for 24 hours, then embedded in paraffin, sectioned at 5 μ m with microtome, stained with hematoxylin and eosin staining according to routine protocol and finally submitted to light microscopy for examination of *Sarcocystis* spp. cystic lesions. Considering to the histologically differences of the wall thickness of *S. cruzi* (thin-walled sarcocyst) and *S. hirsuta*, or *S. hominis* (thick-walled sarcocyst), the found cysts were counted under light microscope and their wall thickness was measured by micrometry method using ocular micrometer (micro-scale).

Statistical Analysis

For statistical evaluation, data analysis was performed using SPSS version 20 (SPSS Inc., Chicago, IL, USA), and chi-square test. Significance level was considered as $p < 0.05$.

RESULTS

Out of 100 cattle examined, only one cattle (1%) showed macroscopic type of *Sarcocystis* spp. In this case, numerous milky-white colored spindle-shaped macrosarcysts of *S. hirsuta* were observed in the tunica muscularis of masticatory muscle (Figure 1). In microscopic evaluation, spherical shape cysts with a mean 14 μ m in diameter impacted with bradyzoites were observed. The cysts wall thickness was more than 2 μ m (Figure 2). Totally, 531 cysts were observed in 500 tissue samples and all 100 cattle (100%) were involved with *Sarcocystis* spp. at least in one of their organs, histologically. Thin-walled *Sarcocystis* corresponding with *S. cruzi* were found in 92.2% of specimens, while 14% had thick-walled cysts (*S. hirsuta* or *S. hominis*). The distribution of thin-walled and thick-walled microscopic cysts in different muscles of cattle is summarized in Table 1. The chi-square test showed significant differences between frequencies of *Sarcocystis* in different muscles ($p < 0.001$). The highest incidence of thin-walled cysts (*S. cruzi*) was in heart muscles, whereas thick-walled cysts (*S. hirsuta* and *S. hominis*) were mostly observed in the esophagus. In addition, thin-walled sarcocysts have a lower frequency (7.8%) in the diaphragm muscle compared to other muscles.

In histopathological examination, the different shapes of microcysts (spherical, oval or elongated) with thin or thick

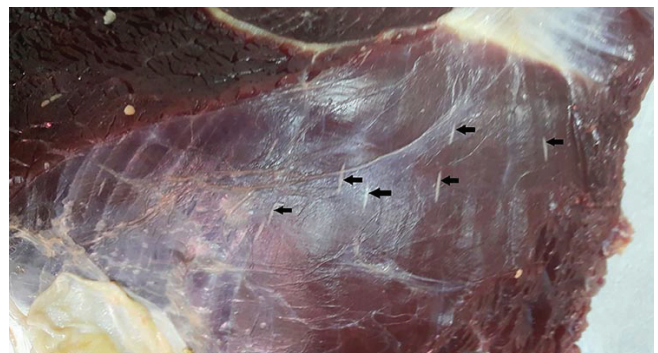


Figure 1. Masticatory muscle of cattle showing multiple macrosarcocysts (*S. hirsuta*), in the tunica muscularis (arrows)

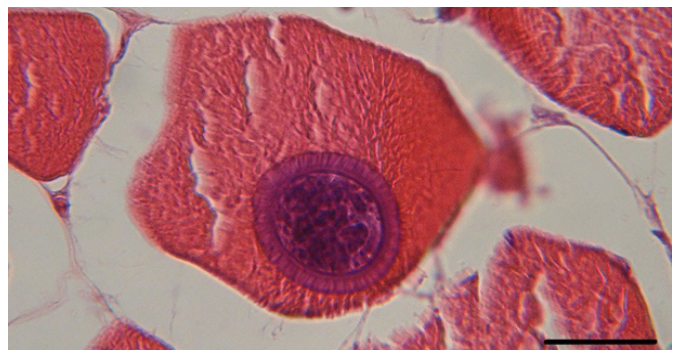

Figure 2. Microscopic section of masseter muscle of the cattle showing round shape thick-walled (more than 2 μ m) sarcocyst (*S. hirsuta* or *S. hominis*) (H&E, scale bar=35 μ m)

distinct walls were observed in over mentioned muscles but no inflammatory reaction was found around the cysts or surround the infected muscle fibers (Figures 3-5).

DISCUSSION

Sarcocystosis is an important zoonotic disease with economic impact and worldwide distribution in various animal species and human being. Many considerable researches have been conducted about the importance and prevalence of this disease in different intermediate hosts and various countries (1,2,16-21). Although, there are many reports of sarcocystosis occurrence in domestic animals (especially cattle) in Iran (9,10,13-15), but most studies have not attempted to identify the species of the parasite in cattle. Moreover, considering the popularity of cattle meat consumption in Sistan region, up to now, there has not been any study about intensity of this disease in Zabol city.

In histopathological investigation, thin-walled sarcocysts (<1 μm) identify as *S. cruzi* and Thick-walled sarcocysts (2-7 μm) identify as *S. hirsuta* or *S. hominis* using micrometry method (3,22). Based on the abovementioned method, the results of the present study revealed that all cattle and all tissue samples were infected with *Sarcocystis* spp. (92.2% of tissue samples with *S. cruzi* and 14% with *S. hirsuta* or *S. hominis*). These findings are in accordance to some investigations which have found in other countries: 100% in Brazil (23), 100% in Argentina (4), 100% in the United States (3), 97.4% in Belgium (24), 97.8% in Iraq (25) and 93.4% in

Turkey (Iran border countries) (26). Whereas, the infection rate in the present study is considerable higher than Egypt, 7.45 (20), Malaysia, 36.2% (2), Philippines, 55% (27) and Ethiopia 82% (28). Besides, in comparison to other areas of Iran, the frequency of sarcocystosis in cattle in the present study (100%) is consistent with Shiraz, 100% (9), Kerman, 100% (11), Hamadan, 100% (14), Bojnurd, 100% (13), Tabriz, 100% (5), Ahvaz, 100% (15) and higher than Isfahan, 89% (12), Shahrekord, 91% (10) and Karaj, 96/8% (29). Aforementioned researches which are conducted in various parts of Iran demonstrate that cattle contamination to *Sarcocystis* spp. is notable. The first detection of macroscopic type of sarcocystosis in cattle (*S. hirsuta*) in Iran was reported by Shekarforoush et al. (6). In this case report, several spindle-shaped macrocysts were observed in diaphragmatic muscle. In a related study, the incidence of macroscopic sarcocysts in cattle slaughtered in Tabriz was declared 8.2%, predominantly in esophagus muscle (5).

In the present study macro-sarcocysts in cattle (*S. hirsuta*) were observed in one case (1%) and in the masticatory muscle. In this study the shape and size of macrocysts were come in agree with over mentioned studies. In other studies, in Iran, no macroscopic cysts were found in cattle which were examined for *Sarcocystis* infection (11-14,17,29). The results of the microscopic examination in the current study revealed that the frequency of thin-walled sarcocysts (*S. cruzi*) and thick-walled sarcocysts (*S. hirsuta* or *S. hominis*) were 92.2% and 14%, respectively and all cattle were infected with sarcocystosis at least in one of their organs. The most infected tissue was cardiac muscle (58.8% for thin-walled cysts) and esophagus (32.8% for thick-

Table 1. Distribution of thin-walled and thick-walled microscopic sarcocysts in different muscles of cattle slaughtered in Zabol abattoir

Type of muscle	Thick-walled sarcocyst	Thin-walled sarcocyst	Total number (%)
	Number (%)	Number (%)	
Heart	16 (22.9%)	271 (58.8%)	287 (54%)
Tongue	20 (28.6%)	47 (10.2%)	67 (12.6%)
Esophagus	23 (32.8%)	43 (9.3%)	66 (12.4%)
Diaphragm	0 (0%)	36 (7.8%)	36 (6.8%)
Masseter	11 (15.7%)	64 (13.9%)	75 (14.1%)
Total number (%)	70 (100%)	461 (100%)	531 (100%)

The percentages have been prepared columnar

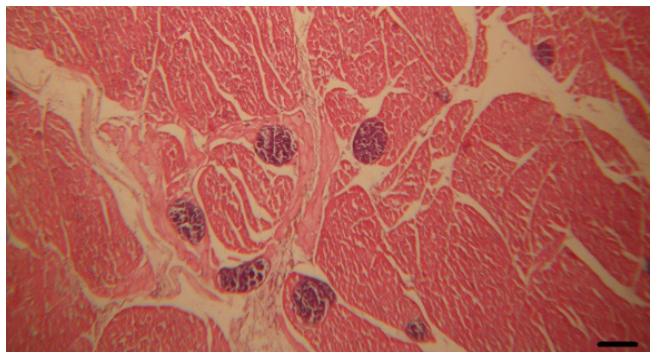


Figure 3. Cardiac muscle of a cattle showing multiple large round and oval shape thin-walled (less than 1 μm) sarcocysts (*S. cruzi*) around the Purkinje cells without any tissue reactions (H&E, scale bar=130 μm)

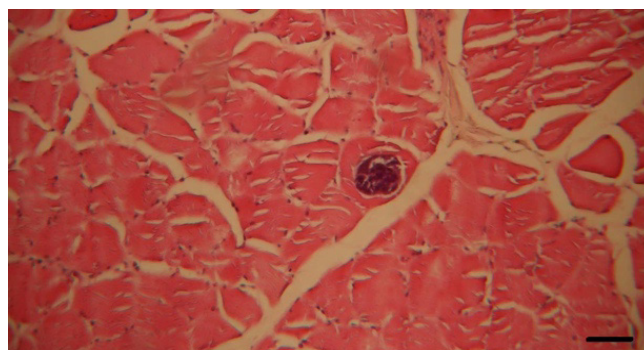


Figure 4. Spherical shape thin-walled (less than 1 μm) sarcocyst (*S. cruzi*) in the esophagus of cattle. The cyst initiated no inflammatory reaction (H&E, scale bar=70 μm)

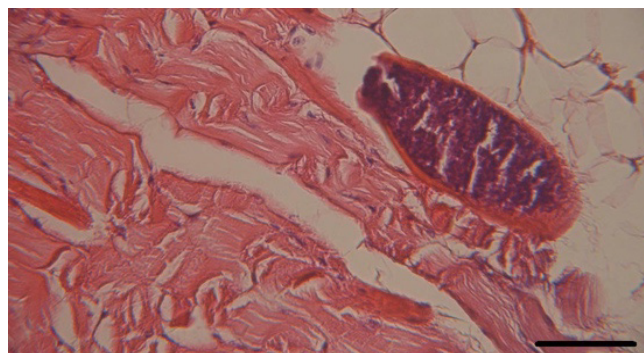


Figure 5. Elongated thin-walled (1 μm) sarcocyst (*S. cruzi*) in the tongue muscle of cattle. The cyst initiated no inflammatory reaction (H&E, scale bar=90 μm)

walled cysts) and the less was diaphragm (for both of thin and thick-walled cysts, 7.8% and 0% respectively). According to these findings, previous researches have demonstrated that *S. cruzi* is predominantly occurred in cardiac muscle (23,29,30). The frequency of thick-walled sarcocysts in the present study (14%) is lower than two other studies (12,29), 21% and 34/4%, respectively. Additionally, opposite to the results of Nourollahi Fard et al. (29) which reported that thick-walled sarcocyst mostly were detected in diaphragm, in our study diaphragm showed no thick-walled cyst. It seems useful to do accurate recognition of *S. hirsuta* and *S. hominis* thick-walled cyst but it was not possible for us considering some problems in ultrastructure observation of primary cysts wall via electron microscopy which is too expensive and difficult to access (30).

In present histopathological investigation, opposite to some studies which reported the existence of inflammatory reactions around some sarcocysts continuing to degeneration (18,21,29), no inflammatory reaction was found.

CONCLUSION

The results of present study demonstrate high frequency of *S. cruzi* in comparison with low frequency of *S. hirsuta* and *S. hominis*. Considering to this fact that the *Sarcocystis* parasite can cause economic losses in livestock animals and could be a threat to the human community health, future investigation about parasite phylogeny and prevention procedures seems to be useful.

Acknowledgements

The authors gratefully acknowledge the University of Zabol for financial support as well as the Mohammad Abad industrial slaughterhouse for their excellent cooperation.

* Ethics

Ethics Committee Approval: This manuscript was conducted on slaughtered cattle and does not contain clinical or experimental studies and patient data.

Informed Consent: This manuscript was conducted on slaughtered cattle and does not contain clinical or experimental studies and patient data.

Peer-review: Internally peer-reviewed.

* Authorship Contributions

Concept: E.F., A.D., R.N., Design: E.F., A.D., R.N., Data Collection or Processing: E.F., A.D., R.N., Analysis or Interpretation: E.F., A.D., R.N., Literature Search: E.F., A.D., R.N., Writing: E.F., A.D., R.N.

Conflict of Interest: The authors declare that they have no conflict of interest.

Financial Disclosure: University of Zabol (Grant number: UOZ_GR_9517_87)

REFERENCES

- Hosseini SR, Shakerian A, Tahamtan N. Survey of *Sarcocystis* infection in slaughtered sheep in Isfahan, Qom and Shahre-Kord, Iran. *J Anim Vet Adv* 2012;11:2683-6.
- Latif B, Vellayan S, Heo CC, Al-Bayati SM, Al-Amiry AM. High prevalence of muscular sarcocystosis in cattle and water buffaloes from Selangor, Malaysia. *Trop Biomed* 2013;30:699-705.
- Fayer R, Esposito DH, Dubey JP. Human infections with *Sarcocystis* species. *Clin Microbiol Rev* 2015;28:295-311.
- More G, Basso W, Bacigalupe D, Venturini MC, Venturini L. Diagnosis of *Sarcocystis cruzi*, *Neospora caninum*, and *Toxoplasma gondii* infections in cattle. *J Parasitol Res* 2008;102:671-5.
- Mirzaei M, Rezaei, H. A survey on *Sarcocystis* spp. infection in cattle of Tabriz city, Iran. *J Parasit Dis* 2016;40:648-51.
- Shekarforoush SS, Razavi SM, Abbasvali M. First detection of *Sarcocystis hirsuta* from cattle in Iran. *IJVR* 2013;14:155-7.
- Dubey JP, Speer CA, Fayer R. *Sarcocystosis of Animals and Man*. 2nd ed. Boca Raton, Florida, USA: CRC Press; 1989.
- Hamidinejat H, Raz Jalali MH, Nabavi L. Survey on *Sarcocystis* infection in slaughtered cattle in south-west of Iran, emphasized on evaluation of muscle squash in comparison with digestion method. *J Anim Vet Adv* 2010;9:1724-6.
- Shekarforoush SS, Razavi SM, Ahmadi H, Sarihi K. Study on prevalence of *Sarcocystis* in slaughtered cattle in Shiraz. *JVR* 2004;59:33-7.
- Bonyadian M, Meshki B. Study on infestation of cow carcasses to *Sarcocystis* spp in slaughtered cows in Shahrekord by impression method. *Pajouhesh-va-Sazandegi* 2001;19:14-8.
- Nourollahi Fard SR, Asghari M, Nouri F. Survey of *Sarcocystis* infection in slaughtered cattle in Kerman, Iran. *Trop Anim Health Prod* 2009;41:1633-6.
- Nourani H, Matin S, Nouri A, Azizi H. Prevalence of thin-walled *Sarcocystis cruzi* and thick-walled *Sarcocystis hirsuta* or *Sarcocystis hominis* from cattle in Iran. *Trop Anim Health Prod* 2010;42:1225-7.
- Salehi M, Adinezade A, Mosazade A, Besharati R, Bahari P. The prevalence of *Sarcocystis* infection in sheep and cattle in Bojnurd, North Khorasan Province, Iran. *J Zoonoses* 2014;1:60-3.
- Parandin F, Feizi F, Maghsood AH, Matini M, Roshan A, Fallah MA. Survey on *Sarcocystis* infection rate in slaughtered cattle and sheep by macroscopic inspection and pepsin digestion methods in Hamadan abattoir, Iran, 2014. *Sci J Hamdan Univ Med Sci* 2015;22:210-6.
- Rahdar M, Karadooni T. Molecular identification of *Sarcocystis* spp. in sheep and cattle by PCR-RFLP from southwest of Iran. *Jundishapur J Microbiol* 2017;10:e12798.
- Daryani A, Alaei R, Dehghan MH, Arab R, Sharif M, Ziaei H. Survey of *Sarcocystis* infection in slaughtered sheep and buffaloes in Ardabil, Iran. *J Anim Vet Adv* 2006;5:60-2.
- Shekarforoush SS, Razavi SM, Dehghan SA, Sarihi K. Prevalence of *Sarcocystis* species in slaughtered goats in Shiraz, Iran. *Vet Rec* 2005;156:418-20.
- Valinezhad A, Oryan A, Ahmadi N. *Sarcocystis* and its complications in camels (*Camelus dromedarius*) of eastern provinces of Iran. *Korean J Parasitol* 2008;46:229-34.
- Farhang-Pajuh F, Yakhchali M, Mardani K. Molecular determination of abundance of infection with *Sarcocystis* species in slaughtered sheep of Urmia, Iran. *Vet Res Forum* 2014;5:181-6.
- Ahmed AM, Elshraway NT, Youssef AI. Survey on *Sarcocystis* in bovine carcasses slaughtered at the municipal abattoir of El-Kharga, Egypt. *Vet World* 2016;9:1461-5.
- Zangana IK, Hussein SN. Prevalence of *Sarcocystis* species (*Sarcocystis ovicanis* and *Sarcocystis capricanis*) in tongue muscle of sheep and goats in Duhok province, Kurdistan region, north Iraq. *Sci J Koya Univ* 2017;5:36-40.
- Wouda W, Snoep JJ, Dubey JP. Eosinophilic myositis due to *Sarcocystis hominis* in a beef cow. *J Comp Pathol* 2006;135:249-53.
- Silva NRS, Rodrigues RJD, Araujo FAP, Beck C, Olicheski AT. Detection of bovine *Sarcocystis cruzi* cysts in cardiac muscles: a new technique of concentration for diagnostic. *Acta Sci Vet* 2002;30:127-9.
- Vangeel L, Houf K, Chiers K, Verducruysse J, Dherde K, Ducatelle R. Molecular based identification of *Sarcocystis hominis* in Belgian minced beef. *J Food Prot* 2007;70:1523-6.

25. Latif BM, Al-Delemi JK, Mohammed BS, Al-Bayati SM, Al-Amiry AM. Prevalence of *Sarcocystis* spp. in meat producing animals in Iraq. *Vet Parasitol* 1999;84:85-90.
26. Kamber U, Arslan MO, Gulbaz G, Tasci GT, Akca A. Identification of *Sarcocystis* spp. by polymerase chain reaction and microscopic examination in various beef products (minced meat, meatballs, fermented sausage). *Turk J Vet Anim Sci* 2018;42:1-6.
27. Claveria FG, Petersen B, Macabagdal MR, Farolan RJ, Farrol MA, Gonzalvo F, et al. A survey of bovine, bubaline and swine sarcocystosis in the Philippines. *Southeast Asian J Trop Med Public Health* 1997;28:173-8.
28. Woldemeskel M, Gebreab F. Prevalence of sarcocysts in livestock of northwest Ethiopia. *Zentralbl Veterinarmed B* 1996;43:55-8.
29. Nourollahi Fard SR, Kheirandish R, Sattari S. Prevalence and histopathological finding of thin-walled and thick-walled *Sarcocysts* in slaughtered cattle of Karaj abattoir, Iran. *J Parasit Dis* 2015;39:272-5.
30. Ghisleni G, Robba S, Germani O, Scanziani E. Identification and prevalence of *Sarcocystis* spp. cysts in bovine canned meat. *Food Control* 2006;17:691-4.