



A Child with Ataxia Telangiectasia with Persistent Hematuria due to Bladder Wall Telangiectasia

Ataksi Telenjektazili Çocukta Mesane Duvarı Telenjektazilerine İkincil Persistan Hematüri

İlke Onur Kazaz , Fatih Çolak , Ahmet Serdar Teoman , Ersagun Karagüzel 

Department of Urology, Karadeniz Technical University School of Medicine, Trabzon, Turkey

Cite this article as: Kazaz İO, Çolak F, Teoman AS, Karagüzel E. A Child with Ataxia Telangiectasia with Persistent Hematuria due to Bladder Wall Telangiectasia. *JAREM* 2018; 8(2): 119-20. DOI: 10.5152/jarem.2018.1861

ABSTRACT

Ataxia telangiectasia (AT) is an autosomal recessive immunodeficiency syndrome. The presence of telangiectasias may vary in location; however, bladder wall telangiectasias are rarely seen and may cause fatal hematuria. In the present case, a child with AT also diagnosed as acute lymphoblastic leukemia presented with persistent hematuria. In cystourethroscopy session, there have been extensive hemorrhagic bladder wall telangiectasias. Persistent hemorrhage was controlled with telangiectasia fulguration and continuous intravesical tranexamic acid infusion. As a result, we advocate early cystoscopy for patients with AT who develop hematuria and intravesical continuous tranexamic acid infusion after telangiectasia fulguration for the management of hemodynamically significant hemorrhage.

Keywords: Ataxia telangiectasia, persistent hematuria, bladder, fulguration

ÖZ

Ataksi telenjektazi (AT) otozomal resesif geçişli bir immün yetmezlik sendromudur. Vücudun çeşitli yerlerinde görülebilen telenjektaziler arasında mesane duvarı telenjektazileri nadiren görülmektedir ve hayatı tehdit eden hematüri ataklarına sebep olabilir. Olgumuz, AT'nin yanında akut lenfoblastik lösemi tanısı almış olup inatçı hematüri kliniği ile değerlendirildi. Yapılan tanısal sistouretrioskopisinde mesanede yaygın hemorajik telenjektazi alanları görüldü. Telenjektazilerin neden olduğu kanama, fulgurasyon ve traneksamik asitin intravezikal yoldan sürekli infüzyonu ile kontrol altına alındı. Sonuç olarak AT'li hematürik hastalarda farklı tedavi seçenekleri olsa da, erken sistouretrioskopi ve ardından telenjektazilerin fulgurasyonu ile intravezikal traneksamik asit uygulanması, kanama kontrolünü sağlamada etkilidir.

Anahtar kelimeler: Ataksi telenjektazi, inatçı hematüri, mesane, fulgurasyon

ORCID IDs of the authors: İ.O.K. 0000-0002-2106-0016; F.Ç. 0000-0002-1161-9875; A.S.T. 0000-0003-4592-9748; E.K. 0000-0003-4270-0147.

INTRODUCTION

Ataxia telangiectasia (AT) is an autosomal recessive immunodeficiency syndrome. The presence of telangiectasias may vary in location. Here we present the case of an 11-year-old female patient diagnosed as AT with acute lymphoblastic leukemia (ALL) who developed clinically significant persistent hematuria due to bladder wall telangiectasias. It is rarely seen.

CASE PRESENTATION

An 11-year-old girl was diagnosed with ataxia telangiectasia when she was a toddler (18 months old). At 8 years of age, she was diagnosed as high-risk ALL and received St. Jude ALL chemotherapy protocol. She was admitted to our hospital 7 months ago with the complaint of persistent hematuria, which needed blood transfusions. She was consulted to us for cystourethroscopy, and a written consent form was taken from her family in Karadeniz Technical University School of Medicine, Department of Urology. Cystourethroscopy revealed active hemorrhagic diffuse telangiectasias on whole bladder wall (Figure 1). These hemorrhagic telangiectasias on the bladder wall were fulgurated. After fulguration, tranexamic acid was administered as continuous intravesical irrigation until the end of the first postoperative week. Subsequently, there was no hematuria.

DISCUSSION

Ataxia telangiectasia is an autosomal recessive immunodeficiency syndrome with cerebellar ataxia, oculocutaneous telangiectasia, and sensitivity to radiation (1). The genetic defect in patients with AT is in the ATM genome (11q) resulting defect in DNA repair and susceptibility to malignancies (2). Because it is a DNA-defective gene disorder, patients with AT may develop malignancies. Most common malignancy in patients with AT is ALL. Our patient was also diagnosed with "high-risk ALL" 2 years ago and received systemic chemotherapy.

Telangiectasias are mostly on oculocutaneous area. They are most significant and pathognomonic lesions in AT. Sometimes these may be located anywhere on body. However, bladder wall telangiectasias are rarely seen and may cause persistent fatal hematuria.

There are various opinions regarding the mechanisms of persistent hematuria due to these telangiectasias (3-7). One study mentioned that hematuria episodes were secondary to the cyclophosphamide-based chemotherapy treatment in patients with AT with ALL (5). Another study reported that these patients could undergo hematuria with increased chemotherapy toxicity because of DNA-repair defects despite the administration of the

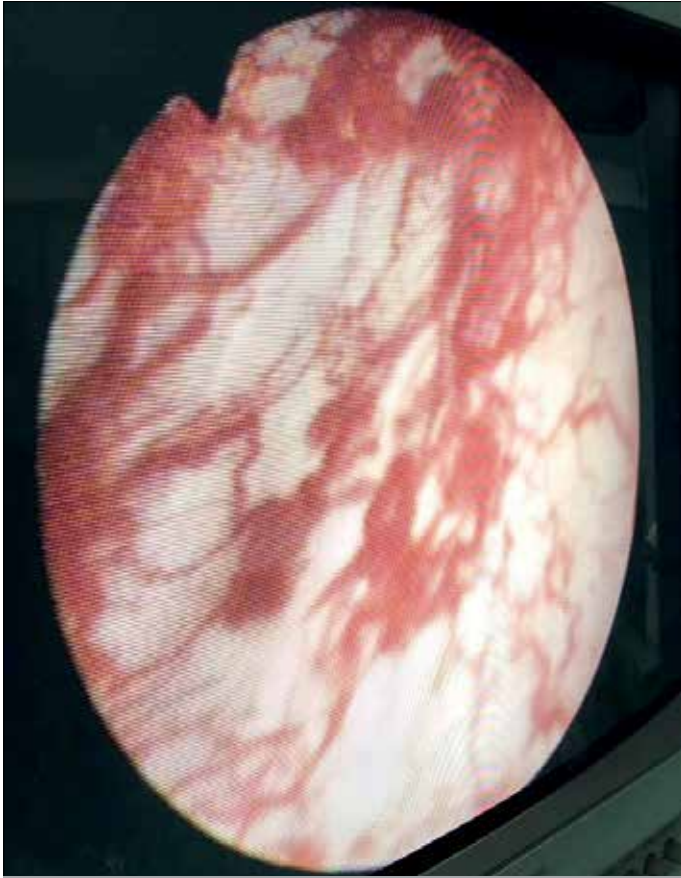


Figure 1. Active hemorrhagic diffuse telangiectasias on the patient's bladder wall

lower cyclophosphamide doses and the administration of the protective agent Mesna (Uromitexan; Eczacıbaşı-Baxter Medical, İstanbul, Turkey) (6). In another study, patients with AT were reported to be immunocompromised, resulting in the development of hemorrhagic cystitis by infection with human polyomaviruses (BK and JC viruses), which may lead to life-threatening persistent hematuria attacks (8). Laboratory examinations of our patient did not reveal any opportunistic viral infection. It is known that she received cyclophosphamide (chemotherapy accompanied by Mesna); nevertheless, there is no evidence that caused persistent hematuria when taken the chemotherapy regimen.

Clinically, it may be difficult to manage hematuria in patients with AT, necessitating interventional treatment options, such as silver nitrate instillation to bladder, vaporization of lesions with laser or diathermy, selective vesical artery embolism, and even cystectomy, as reported in the literature (4, 5). Our patient underwent telangiectasia fulguration those seen in her cystourethroscopy as diffuse hemorrhagic telangiectasias on whole bladder wall. After the fulguration, intravesical continuous tranexamic acid infusion was administered using Foley catheter for a week. Finally, there was no macroscopic hematuria observed. We believe that this successful treatment may be a treatment option for persistent hematuria due to bladder wall telangiectasias.

CONCLUSION

In patients with AT it is rarely possible to see bladder wall telangiectasias. When these cause persistent hematuria, it may be

hard to control bleeding. We advocate early cystourethroscopy for patients with AT who develop hematuria and intravesical continuous tranexamic acid infusion after telangiectasia fulguration for the management of hemodynamically significant hemorrhage.

Informed Consent: Written informed consent was obtained from patients' parents who participated in this case.

Peer-review: Externally peer-reviewed.

Author Contributions: Concept – İ.O.K., F.Ç., A.S.T., E.K.; Design – İ.O.K., F.Ç., A.S.T., E.K.; Supervision – İ.O.K., F.Ç., A.S.T., E.K.; Resources – İ.O.K., A.S.T.; Materials – İ.O.K., E.K.; Data Collection and/or Processing – İ.O.K., F.Ç., A.S.T., E.K.; Analysis and/or Interpretation – İ.O.K., F.Ç., A.S.T.; Literature Search – F.Ç., A.S.T.; Writing Manuscript – İ.O.K., F.Ç., A.S.T.; Critical Review – İ.O.K., A.S.T.; Other – E.K.

Conflict of Interest: Authors have no conflicts of interest to declare.

Financial Disclosure: The authors declared that this study received no financial support.

Hasta Onamı: Yazılı hasta onamı bu çalışmaya katılan hastanın ailesinden alınmıştır.

Hakem Değerlendirmesi: Dış bağımsız.

Yazar Katkıları: Fikir – İ.O.K., F.Ç., A.S.T., E.K.; Tasarım – İ.O.K., F.Ç., A.S.T., E.K.; Denetleme – İ.O.K., F.Ç., A.S.T., E.K.; Kaynaklar – İ.O.K., A.S.T.; Malzemeler – İ.O.K., E.K.; Veri Toplanması ve/veya İşlemesi – İ.O.K., F.Ç., A.S.T., E.K.; Analiz ve/veya Yorum – İ.O.K., F.Ç., A.S.T.; Literatür Taraması – F.Ç., A.S.T.; Yazıyı Yazan – İ.O.K., F.Ç., A.S.T.; Eleştirel İnceleme – İ.O.K., A.S.T.; Diğer – E.K.

Çıkar Çatışması: Yazarlar çıkar çatışması bildirmemişlerdir.

Finansal Destek: Yazarlar bu çalışma için finansal destek almadıklarını beyan etmişlerdir.

REFERENCES

- Gatti RA, Tward A, Concannon P. Cancer Risk in ATM Heterozygotes: A Model of Phenotypic and Mechanistic Differences between Missense and Truncating Mutations. *Mol Genet Metab* 1999; 68: 419-23. [\[CrossRef\]](#)
- Chun HH, Gatti RA. Ataxia-telangiectasia, an evolving phenotype. *DNA Repair* 2004; 3: 1187-96. [\[CrossRef\]](#)
- Huang KY, Shyur SD, Wang CY, Shen EY, Liang DC. Ataxia telangiectasia: report of two cases. *J Microbiol Immunol Infect* 2001; 34: 71-5.
- Suzuki K, Tsugawa K, Oki E, Morio T, Ito E, Tanaka H. Vesical varices and telangiectasias in a patient with ataxia telangiectasia. *Pediatr Nephrol* 2008; 23: 1005-8. [\[CrossRef\]](#)
- Cohen JM, Cuckow P, Davies EG. Bladder wall telangiectasis causing life-threatening haematuria in ataxia-telangiectasia: a new observation. *Acta Paediatr* 2008; 97: 667-9. [\[CrossRef\]](#)
- Sandoval C, Swift M. Treatment of lymphoid malignancies in patients with ataxia-telangiectasia. *Med Pediatr Oncol* 1998; 31: 491-7. [\[CrossRef\]](#)
- Aygün FD, Nepesov S, Çokuğraş H, Camcıoğlu Y. Bladder Wall Telangiectasia in a Patient with Ataxia-Telangiectasia and How to Manage? *Case Rep Pediatr* 2015; 2015: 615368.
- Christmann M, Heitkamp S, Lambrecht E, Doerries K, Schubert R, Zielen S. Haemorrhagic cystitis and polyomavirus JC infection in ataxia telangiectasia. *J Pediatr Urol* 2009; 5: 324-6. [\[CrossRef\]](#)