



# Cytomegalovirus-Associated Protein-Losing Gastropathy (Menetrier's Disease) in Childhood

Nafiye Urgancı<sup>1</sup>, Seda Geylani Güleç<sup>2</sup>, Önder Kılıçaslan<sup>2</sup>, Tülay Başak<sup>3</sup>

<sup>1</sup>Clinic of Pediatric Gastroenterology, Şişli Hamidiye Etfal Training and Research Hospital, İstanbul, Turkey

<sup>2</sup>Clinic of Pediatrics, Gaziosmanpaşa Taksim Training and Research Hospital, İstanbul, Turkey

<sup>3</sup>Clinic of Pathology, Şişli Hamidiye Etfal Training and Research Hospital, İstanbul, Turkey

## ABSTRACT

Pediatric Menetrier disease is a rare clinical event with unknown etiology, which has a different course from that in adults. It is characterized by gastric hypertrophy and hypoalbuminemia secondary to protein loss throughout the gastric mucosa. Menetrier disease is usually self-limiting in children. In particular, in patients with immune deficiency, one of the most important cause for Menetrier disease is cytomegalovirus (CMV) infection. This infection can also be observed in immunocompetent children. A girl aged two and a half years with a one-week history of generalized edema, weakness, and decreased urine output was admitted at the Pediatric Department of Şişli Hamidiye Etfal Training and Research Hospital. Periorbital and pretibial edema, abdominal distension, and ascites were detected and laboratory studies revealed hypoalbuminemia and elevated fecal alpha-1 antitrypsin excretion. According to the serological investigations, anti-CMV IgM antibodies were detected positive and CMV DNA values were found to be 1170 copies/mL. The patient was treated with intravenous albumin infusion, PPI therapy, and a high-protein and low-salt diet. On the 10<sup>th</sup> day of treatment, her condition gradually improved without any antiviral drug. We prepared this presentation because we determined CMV as an etiological agent of protein-losing gastropathy in a child with a healthy immune system. (*JAREM 2016; 6: 56-8*)

**Keywords:** Hypertrophic gastritis, cytomegalovirus infections, protein-losing enteropathies

## INTRODUCTION

Menetrier's disease is a rare gastropathy characterized by the presence of hypertrophic gastric folds, lack of acid production, excess mucus secretion, anemia, and low serum albumin (1). The onset of the disease shows clinical and prognostic differences in pediatric and adult patients. While the disease is usually self-limiting in children and treatment with supportive care involving a high-protein and low-salt diet may be sufficient, it shows a chronic progressive course in adults (2, 3).

Physiopathologically, hypoalbuminemia and edema are seen secondary to protein loss throughout abnormal gastric mucosa. Clinical symptoms that include nausea, vomiting, abdominal pain, peripheral edema, ascites, and pleural effusion can be observed. One of the most important causes of Menetrier's disease in childhood is cytomegalovirus (CMV) infection (3-5). Gastro-duodenal endoscopy is important for diagnosis. CMV infection-linked protein-losing enteropathy was examined in our immunocompetent case.

## CASE PRESENTATION

A two-and-a-half-year-old female patient was admitted to the hospital with complaints of generalized edema, weakness, and decreased urine output. From the patient's history, we learned that a week before being admitted to our hospital, considering tonsillitis, the patient had been given oral amoxicillin-clavulanic acid treatment at a private clinic because of complaints of fatigue, fever, and loss of appetite; generalized edema and decreased urine output were then observed. Nothing significant was found in the patient's history and family background, and the

patient was admitted to the infant clinic. During physical examination, periorbital and pretibial edema, abdominal distension, and ascites were detected. In the basal zones of both lungs, respiratory sounds were difficult to hear (Figure 1). According to the laboratory studies, total protein was 2.2 g/dL, albumin was 0.8 g/dL, Na was 126 mEq/L, Hb was 9.5 g/dL, leucocytes were 9300/mm<sup>3</sup>, and thrombocytes were 296000/mm<sup>3</sup>. Nothing significant was detected in whole urine analysis. The patient's 24-h urine protein was negative, and her triglyceride and cholesterol levels were normal. The patient's serum immunoglobulin-G (134 mg/dL) and C3 (53 mg/dL) levels were low, while her immunoglobulin A, M, and C4 levels were within normal limits. Diffuse ascites were detected in her abdominal ultrasonography, and a chest x-ray revealed pleural effusion in her bilateral basals. The alpha-1 antitrypsin level (320 mg/dL) in the patient's stool was high, and while anti-*Helicobacter pylori*, IgG antibody, and *Giardia* antigen in the stool were negative in serological investigations, CMV IgM was positive and CMV DNA was 1170 copy/mL. In the upper gastrointestinal system (GIS) endoscopy of the patient, edema and hyperemia in the folds of the corpus and an appearance compatible with hyperemic mega-folds and hemorrhagic gastritis were observed (Figure 2). Pathologically, chronic pan-mucosal gastritis symptoms were detected. When hematoxylin-eosin staining was performed in the tissue, CMV-positive intraepithelial inclusion bodies were observed (Figures 3, 4). With these results, the patient was diagnosed with Menetrier's disease associated with CMV infection. The patient was treated with intravenous albumin infusion and a proton pump inhibitor (PPI), omeprazole. She was started on a high-protein and low-salt diet. On the 10th day of her treatment, her condition gradually improved and her blood



protein values were within normal limits without any antiviral therapy (ganciclovir). The patient is being monitored for a year by the pediatric gastroenterology department. No problems have been experienced in her follow-up period. Written consent was acquired from the patient's family.

## DISCUSSION

Hypoproteinemic hypertrophic gastropathy (Menetrier's disease) is a rare, self-limiting clinical event in childhood, and its clinical course can differ from that of adults. In this temporary and benign gastric disease, protein loss from the gastrointestinal tract and

hypoalbuminemia are observed due to significant hypertrophy in the mucus-secreting cells. Although its etiology is unknown, it is believed that the gastric mucosa is thickened due to a variety of factors, including excessive production of transforming growth factor alpha (TGF- $\alpha$ ), which sends an elevated alert to the epidermal growth factor receptors (EGFR) (3, 4). The disease is usually observed in children under 10 years of age and is generally characterized by vomiting, abdominal pain, and peripheral edema; it is more common in males. In our patient, periorbital and pretibial edema, abdominal ascites, and pleural effusion were present. Hypoalbuminemia and protein loss were detected in the stool. Regarding the etiology of Menetrier's disease, it can be caused by chemical irritants, toxins, diet, neuro-emotional, endocrine, immunological, and anatomical abnormalities, allergies, immune disorders, and infectious agents such as CMV and *H. pylori*. Although the most common infectious agent associated with Menetrier's disease is CMV, some Menetrier's cases have also been

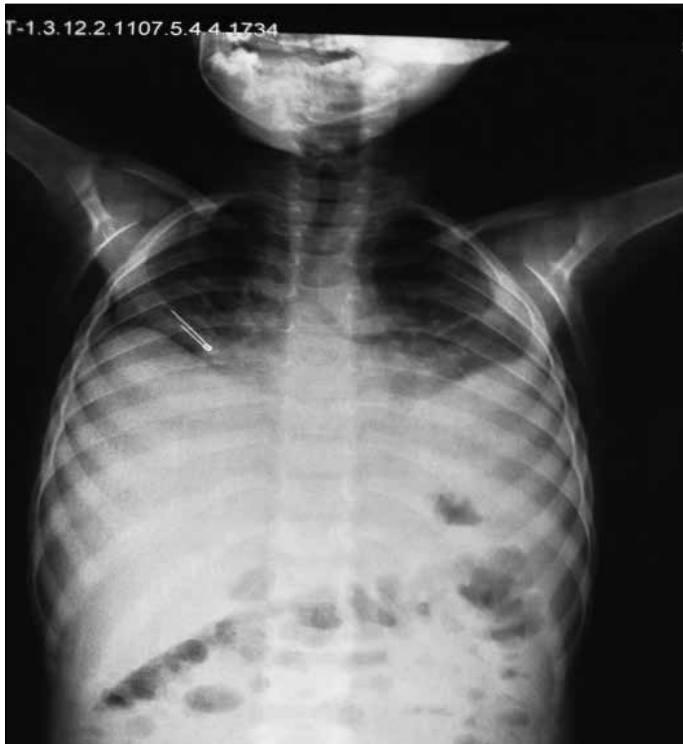

Figure 1. Chest radiograph of the patient upon admission

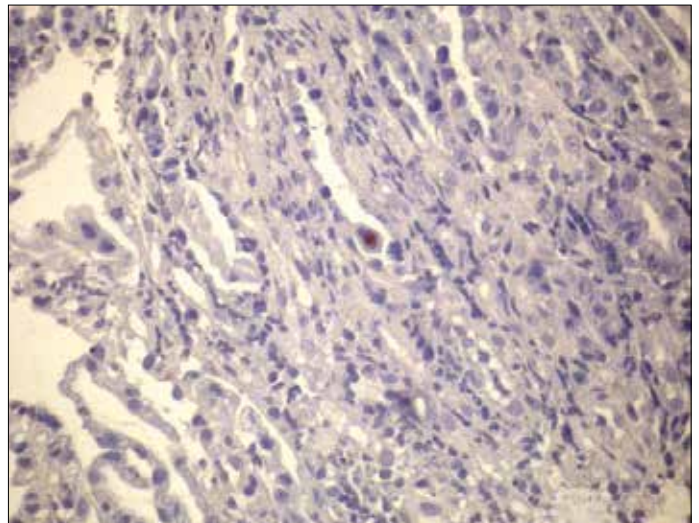


Figure 3. Pan-mucosal gastritis and intraepithelial inclusion bodies (HEX 40)

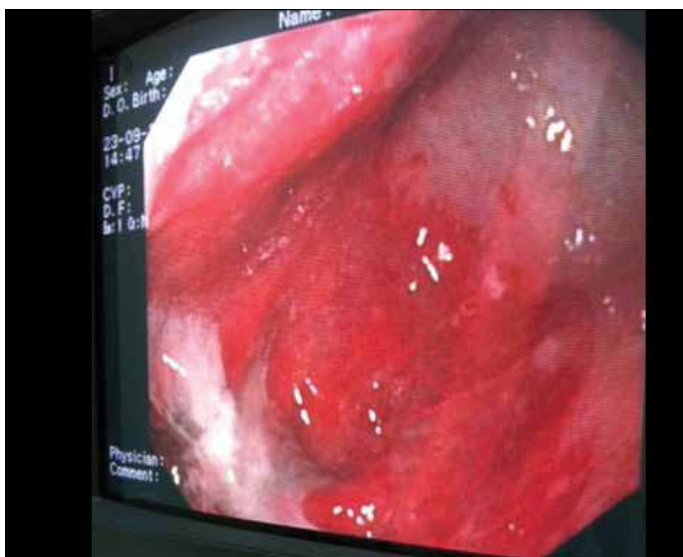


Figure 2. Endoscopic image of pan-mucosal gastritis

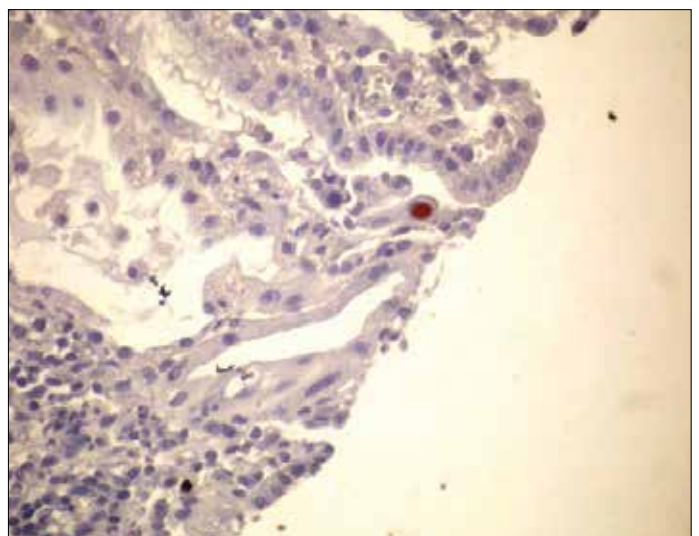


Figure 4. Pan-mucosal gastritis and intraepithelial inclusion bodies (HEX 100)

reported as being associated with *H. pylori*, herpes virus, *Giardia*, and *Mycoplasma* (3, 6-8). Although the mechanism is not clearly understood, it has been reported in a few studies that TGF- $\alpha$  is immunoreactively increased by CMV (5). CMV infection usually gives signs in the gastric fundus and corpus and may lead to wall thickening, ulceration, hemorrhage, and perforation (9). Characteristic histologic symptoms include hypertrophy of the gastric mucosa associated with foveolar hyperplasia. In addition, symptoms such as hypertrophic gastric glands, interstitial inflammatory reaction, glandular atrophy, and cysts on mucous cells may also be observed. When we examined our patient, who was serologically diagnosed with positive CMV IgM, we detected edematous corpus, hyperemic mega-folds, and hemorrhagic gastritis by upper GIS endoscopy. Histopathologically, chronic pan-mucosal gastritis and, in tissue, CMV positive intraepithelial inclusion bodies were observed. It has been stated that the reason for this observation is that CMV is demonstrative in the early stages but cannot be seen in later stages (9). Gastrointestinal CMV infection is mostly seen in patients with immune deficiency. In these cases, it may affect a part of the gastrointestinal system or may cause a generalized infection. In immunodeficient patients, CMV infection is mostly seen in the colon, stomach, and esophagus, while in patients with normal immune systems, the stomach is most frequently affected (9-11).

For diagnosis, CMV serology is vital during routine screening. However, antibodies and virus excretion may not be detected in Menetrier's disease. Therefore, observing CMV inclusion bodies by gastric biopsy is more important. However, these cannot always be found. Thus, compared to serology, detection of CMV DNA in biopsy material through PCR is a more sensitive method. However, since this method is expensive and cannot be performed everywhere, its application is limited. The recommended method for diagnosis is to perform serological tests routinely and to examine gastric biopsy material immunohistochemically via PCR (5).

## CONCLUSION

When proteinuria is not detected in the urine analysis of patients presenting with generalized edema, alpha-1 antitrypsin in the stool, which is a noninvasive test, should be examined and CMV infection, a cause of protein-losing enteropathy or gastropathy, should be considered.

**Informed Consent:** Written informed consent was obtained from patients' parents who participated in this case.

**Peer-review:** Externally peer-reviewed.

**Author Contributions:** Concept - N.U., S.G.G.; Design - N.U.; Supervision - N.U., S.G.G.; Analysis and/or Interpretation - S.G.G., Ö.K., T.B.; Literature Search - N.U., S.G.G.; Writing Manuscript - N.U., S.G.G., Ö.K., T.B.; Critical Review - S.G.G.

**Conflict of Interest:** No conflict of interest was declared by the authors.

**Financial Disclosure:** The authors declared that this study has received no financial support.

## REFERENCES

1. Strisciuglio C, Corleto VD, Brunetti-Pierri N, Piccolo P, Sangermano R, Rindi G, et al. Autosomal dominant Menetrier-like disease. *J Pediatr Gastroenterol Nutr* 2012; 55: 717-20. (CrossRef)
2. Canan O, Ozçay F, Bilezikçi B. Menetrier's disease and severe gastric ulcers associated with cytomegalovirus infection in an immunocompetent child: a case report. *Turk J Pediatr* 2008; 50: 291-5.
3. Son KH, Kwak JJ, Park JO. A case of cytomegalovirus-negative Menetrier's disease with eosinophilia in a child. *Korean J Pediatr* 2012; 55: 293-6. (CrossRef)
4. Di Nardo G, Oliva S, Aloï M, Ferrari F, Frediani S, Marcheggiano A, et al. A pediatric non-protein losing Menetrier's disease successfully treated with octreotide long acting release. *World J Gastroenterol* 2012; 18: 2727-9. (CrossRef)
5. Megged O, Schlesinger Y. Cytomegalovirus-associated protein-losing gastropathy in childhood. *Eur J Pediatr* 2008; 167: 1217-20. (CrossRef)
6. Hochman JA, Witte DP, Cohan MB. Diagnosis of cytomegalovirus infection in pediatric Menetrier disease by in situ hybridization. *J Clin Microbiol* 1996; 34: 2588-9.
7. Hamlin M, Shepherd K, Kennedy M. Resolution of Menetrier disease after *Helicobacter Pylori* eradication therapy. *N Z Med J* 2001; 114: 382-3.
8. Ladas SD, Tassios PS, Malamou HC, Protopapa DP, Raptis SA. Omeprazole induces a long-term clinical remission of protein losing gastropathy of Menetrier's disease. *Eur J Gastroenterol Hepatol* 1997; 9: 811-3. (CrossRef)
9. Yokose N, Tanabe Y, An E, Osamura Y, Sugiura T, Hosone M, et al. Acute gastric mucosal lesions associated with cytomegalovirus infection in a non-immunocompromised host. *Intern Med* 1995; 34: 883-5. (CrossRef)
10. Trout AT, Dillman JR, Neef HC, Rabah R, Gadepalli S, Geiger JD. Case 189: Pediatric Menetrier disease. *Radiology* 2013; 266: 357-61. (CrossRef)
11. Patra S, Samal SC, Chacko A, Mathan VI, Mathan MM. Cytomegalovirus infection of the human gastrointestinal tract. *J Gastroenterol Hepatol* 1999; 14: 973-6. (CrossRef)