



Pleomorphic Adenoma of the Nasal Cavity

Nazal Septumdan Kaynaklanan Bir Pleomorfik Adenoma Olgusu

Tolga Kandoğan¹, Abdullah Dalğıç¹, Gürol Gültekin¹, Seçkin Ulusoy², Elif Selek³

¹Clinic of Otolaryngology, İzmir Bozyaka Training and Research Hospital, İzmir, Turkey

²Clinic of Pathology, İzmir Bozyaka Training and Research Hospital, İzmir, Turkey

³Clinic of Otolaryngology, Gaziosmanpaşa Taksim Training and Research Hospital, İstanbul, Turkey

ABSTRACT

Pleomorphic adenoma is mixed and usually benign tumor originating salivary glands. The most common salivary gland tumor is pleomorphic adenoma. The most common localization of pleomorphic adenoma is parotid gland. Although it is found in major salivary gland, pleomorphic adenoma may be found paranasal sinuses and nasal cavity rarely. A 74-year-old female presented with a 3-month history of right-sided nasal obstruction was presented. Although it is infrequently, the possibility of pleomorphic adenoma should be kept in mind while assessing well-defined lobular intranasal lesions. (*JAREM 2015; 5: 25-7*)

Keywords: Adenoma, pleomorphic adenoma, nasal cavity

ÖZET

Pleomorfik adenoma tükürük bezinden kaynaklanan, mikst ve genellikle benign bir tümördür. Tükürük bezi tümörlerinin en sık görülen tipidir ve en çok parotis bezinde ortaya çıkar. Pleomorfik adenoma büyük tükürük bezlerinde görülmesine rağmen vücutun diğer yerlerinde de görülen olgular bildirilmiştir. Nazal kavite ve paranasal sinüsler de az da olsa olgu bildirimleri mevcuttur. Biz nazal kavitede nazal septumdan kaynaklanan 74 yaşında pleomorfik adenomalı bir hastayı olgu olarak sunduk. Nazal kaviteelerde tek taraflı düzenli sınırlara sahip kitlelerde çok nadir olmasına rağmen pleomorfik adenoma da ayırıcı tanılar içinde düşünülmelidir. (*JAREM 2015; 5: 25-7*)

Anahtar Sözcükler: Adenoma, pleomorfik adenoma, nazal kavite

INTRODUCTION

Pleomorphic adenoma (PA) is a mixed, usually benign tumor of the main salivary glands, mostly observed in the parotid gland (1). Although few cases have been reported in other sites, PA of the nasal cavity is still rarely observed (2). There is no consensus about the origin of the PA tumors in the nasal cavity. Only a few reports have documented the presence of this tumor along the nasal septum exist (2). For most patients, the chief complaint is a unilateral nasal obstruction and/or occasional epistaxis (3). Here we present an intranasal PA located on the septum nasi.

CASE PRESENTATION

A 74-year-old female presented with a 3-month history of right-sided nasal obstruction. She had no previous history of nasal polypsis. Questioning about the complaints revealed that she had epistaxis a few times previously. Anterior rhinoscopy and endoscopy revealed a mucosa-covered polypoidal mass obstructing the right nasal cavity, possibly originating from the nasal septum. The mass was friable and bled easily when touched with an instrument. CT showed a unilateral right-sided soft tissue mass, expanding from the septum to the lateral wall. Paranasal sinuses were normal with no signs of infection or polyposis (Figure 1). Instead of performing a biopsy, we planned a complete removal of the mass with endoscopic surgery. The tumor was completely removed.

The tumor was pedunculated on the cartilaginous nasal septum. The overall postoperative histology was PA with a marked myo-

epithelial component (Figure 2, 3). The postoperative course was uneventful, and the patient was discharged. Written informed consent was obtained from the patient who participated in this study.

DISCUSSION

Pleomorphic adenoma is an encountered pathology in the major salivary glands tumors. It is less frequent in minor salivary glands of the hard and soft palates (4). Other rare sites are the upper aerodigestive tract, including the nasal cavity, pharynx, larynx, trachea, and lacrimal glands (4). The majority of intranasal PAs arise from the nasal septum. PAs originating from the lateral wall and inferior turbinate account for 9.8%–20% of the reported cases, although most of the minor mucous and serous glands are located in the lateral nasal wall and turbinates (1-3). PA of the nasal cavity is more frequently observed in women and between the third and sixth decades of life (4). Most symptoms are nasal obstruction, epistaxis, and intermittent nasal discharge. The tumor size varies from 5 mm to 7 cm (4). PAs are dome-shaped, exophytic, polypoid, oval, firm, gray, smooth, and with capsule. No destruction of the surrounding tissue is observed (5).

On CT images, these tumors show a well-defined, homogenous, soft tissue mass with smooth remodeling of the surrounding bones. Calcification is rare (3). It is think benign and malign tumors in the differential diagnosis of the nasal septum mass such as sinonasal polyposis, inverted papilloma, juvenile angiofibroma

This study was presented at the 34th Turkish National Congress of Otorhinolaryngology and Head and Neck Surgery, 10-14 October 2012, Antalya, Turkey. Bu çalışma 34. Türk Ulusal Kulak Burun Boğaz ve Baş Boyun Cerrahisi Kongresi'nde sunulmuştur, 10-14 Ekim 2012, Antalya, Türkiye.



Address for Correspondence / Yazışma Adresi: Dr. Abdullah Dalğıç, Clinic of Otolaryngology, İzmir Bozyaka Training and Research Hospital, İzmir, Turkey
Phone: +90 505 475 70 95 E-mail: dalgicabdullah@gmail.com

Received Date / Geliş Tarihi: 11.05.2014 **Accepted Date / Kabul Tarihi:** 08.12.2014
© Copyright 2015 by Gaziosmanpaşa Taksim Training and Research Hospital. Available on-line at www.jarem.org
© Telif Hakkı 2015 Gaziosmanpaşa Taksim Eğitim ve Araştırma Hastanesi. Makale metnine www.jarem.org web sayfasından ulaşılabilir.
DOI: 10.5152/jarem.2015.523

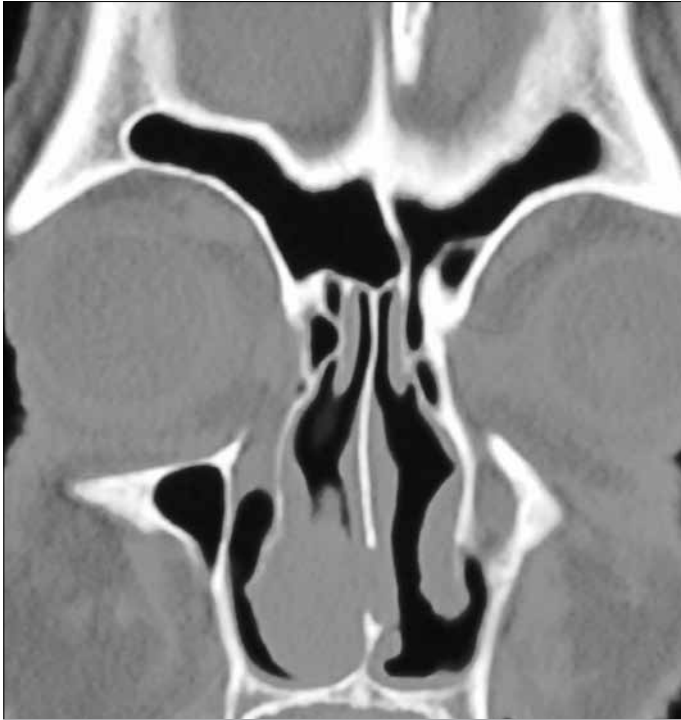

Figure 1. Paranasal sinuses are normal, with no signs of infection or polyposis in the paranasal CT
CT: computed tomography

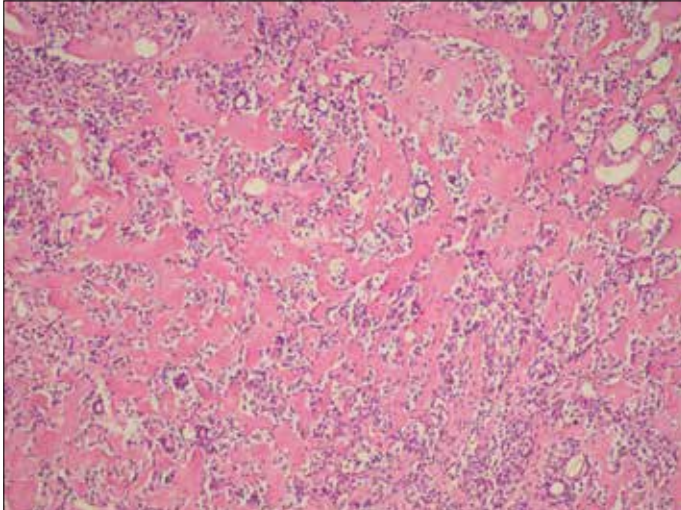


Figure 2. Epithelial component embedded with hyalinized stromal area under a light microscope

squamous cell carcinoma, chondrosarcoma, adenocarcinoma, sinonasal melanoma, and benign minor salivary gland tumor (4).

Malignant transformation of PA of the nasal cavity has been reported in 2.4%–10% of cases (6). Although it is reported that PAs arising from the nasal septum are usually multilobulated and calcified on CT, in our case, the mass was solid and homogenous without any signs of lobulations and calcifications.

Intranasal mixed tumors have a relatively low rate of recurrence (10%), in comparison with the high rate of recurrence (50%) in parotid gland mixed tumors and 25% for intra-oral mixed tumors.

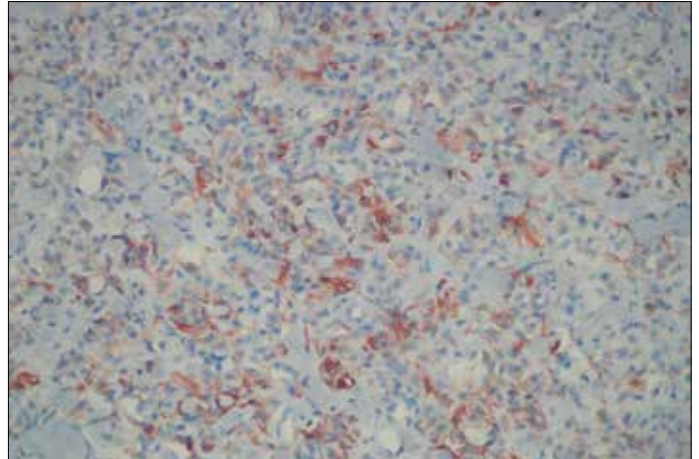


Figure 3. Actine positivity in myoepithelial cells (Actinex 200)

This is because of the very cellular pattern with few areas of stromal predominance in mixed salivary tumors of the nasal fossa (7). Surgical excision with clear margins is the treatment of choice for PA, irrespective of the site of origin. Approaches depend on the size and location and include lateral rhinotomy, intranasal excision, or midfacial degloving (3).

If these neoplasms are allowed to progress untreated, their expansion may cause local destruction of the paranasal sinuses (5). Nevertheless, postoperative follow-up is necessary for all patients with intranasal PA because as many as 10% of patients may experience a recurrence despite wide local excision with clear margins (5).

CONCLUSION

Pleomorphic adenomas of the nasal cavity are rare neoplasms that are difficult to diagnose. In addition, it should be kept in mind that although recurrence and metastasis are uncommon, patients need to be followed postoperatively.

Informed Consent: Written informed consent was obtained from patient who participated in this study.

Peer-review: Externally peer-reviewed.

Author contributions: Concept - T.K.; Design - A.D., T.K., G.G.; Supervision - T.K.; Resource - T.K., A.D.; Materials - T.K., G.G., E.S.; Data Collection and/or Processing - T.K., G.G.; Analysis and/or Interpretation - T.K., A.D., E.S.; Literature Search - A.D., S.U.; Writing - T.K., A.D., S.U.; Critical Reviews - T.K., A.D., G.G.; Other - S.U., E.S.

Conflict of Interest: No conflict of interest was declared by the authors.

Financial Disclosure: The authors declared that this study has received no financial support.

Hasta Onamı: Yazılı hasta onamı bu çalışmaya katılan hastadan alınmıştır.

Hakem değerlendirmesi: Dış bağımsız.

Yazar Katkıları: Fikir - T.K.; Tasarım - A.D., T.K., G.G.; Denetleme - T.K.; Kaynaklar - T.K., A.D.; Malzemeler - T.K., G.G., E.S.; Veri toplanması ve/veya işlemesi - T.K., G.G.; Analiz ve/veya yorum - T.K., A.D., E.S.; Literatür taraması - A.D., S.U.; Yazıyı yazan - T.K., A.D., S.U.; Eleştirel inceleme - T.K., A.D., G.G.; Diğer - S.U., E.S.

Çıkar Çatışması: Yazarlar çıkar çatışması bildirmemişlerdir.

Finansal Destek: Yazarlar bu çalışma için finansal destek almadıklarını beyan etmişlerdir.

REFERENCES

1. Yazibene Y, Ait-Mesbah N, Kalafate S, Yahı-Ait Mesbah N, Abdennebi A, Bouzid H, et al. Degenerative pleomorphic adenoma of the nasal cavity. *Eur Ann Otorhinolaryngol Head Neck Dis* 2011; 128: 37-40. [\[CrossRef\]](#)
2. Malinvaud D, Couloigner V, Badoual C, Halimi P, et al. Pleomorphic adenoma of the nasal septum and its relationship with Epstein-Barr virus. *Auris Nasus Larynx* 2006; 33: 417-21. [\[CrossRef\]](#)
3. Fushiki H, Morijiri M, Maruyama M, Motoshima H, Watanabe Y. MRI of intranasal pleomorphic adenoma. *Acta Otolaryngol* 2006; 126: 889-91. [\[CrossRef\]](#)
4. Oztürk E, Sağlam O, Sönmez G, Cüce F, Haholu A. CT and MRI of an unusual intranasal mass: pleomorphic adenoma. *Diagn Interv Radiol* 2008; 14: 186-8.
5. Acevedo JL, Nolan J, Markwell JK, Thompson D. Pleomorphic adenoma of the nasal cavity: a case report. *Ear Nose Throat J* 2010; 89: 224-6.
6. Kumagai M, Endo S, Koizumi F, Kida A, Yamamoto M. A case of pleomorphic adenoma of the nasal septum. *Auris Nasus Larynx* 2004; 31: 439-42. [\[CrossRef\]](#)
7. Compango J, Wong RT. Intranasal mixed tumours (pleomorphic adenoma): A clinical pathological study of 40 cases. *Am J Clin Pathol* 1977; 68: 213-8.