

A Case of Nodular Cystic Acne Treated with Systemic Dapsone

Sistemik Dapsone ile Tedavi Edilen Bir Nodüler Kistik Akne Olgusu

Munise Daye , Selami Aykut Temiz 

Necmettin Erbakan University Meram Faculty of Medicine, Department of Dermatology, Konya, Turkey

Cite this article as: Daye M, Temiz SA. A Case of Nodular Cystic Acne Treated with Systemic Dapsone. JAREM 2020;10(1): 103-5

ABSTRACT

Dapsone is an aniline derivative from synthetic sulfones. The mechanism of action of dapsone is obscure in inflammatory diseases; however, it is suggested to inhibit neutrophil chemotaxis and lysosomal enzymes. Acne vulgaris (AV) is a chronic inflammatory disorder of the pilo-sebaceous unit.

Herein we report a pediatric patient who was started systemic isotretinoin due to severe nodular cystic AV but could not continue due to elevated liver enzymes and well response to systemic dapsone treatment. We consider that per-oral dapsone treatment may be a well-tolerated and effective treatment option in patients with moderate/severe, frequently recurring AV which is irresponsive to conventional therapies and may a good alternative to isotretinoin particularly in pediatric cases.

Keywords: Dapsone, isotretinoin, nodulocystic acne

ÖZ

Dapsone, sentetik sülfonlardan bir anilin türevidir. Dapsone'nun etki mekanizması enflamatuvar hastalıklarda belirsizdir, ancak nötrofil kemotaksisini ve lizozomal enzimleri inhibe ettiği düşünülmektedir. Akne vulgaris (AV), pilo-sebase ünitenin kronik enflamatuvar bir hastalığıdır. Burada, şiddetli nodüler kistik AV nedeniyle sistemik izotretinoin kullanmaya başlayan, ancak karaciğer enzim yüksekliği nedeniyle devam edemeyen ve sistemik dapsone tedavisine iyi yanıt veren bir pediyatrik hastayı sunuyoruz. Oral dapsone tedavisinin, orta dereceli/şiddetli, sıklıkla tekrarlayan AV'li hastalarda, geleneksel terapilere cevap vermeyen ve özellikle pediyatrik olgularda izotretinoin'e iyi bir alternatif olabilecek iyi tolere edilen ve etkili bir tedavi seçeneği olabileceğini düşünüyoruz.

Anahtar kelimeler: Dapsone, izotretinoin, nodülökistik akne

INTRODUCTION

Dapsone (4,4'-diamino diphenyl sulfone) is an aniline derivative from synthetic sulfones, which has both anti-bacterial and anti-inflammatory effects. It was first used for the treatment of leprosy in 1940 and for the treatment of dermatitis herpetiformis and non-infectious inflammatory dermatoses thereafter (1).

Acne vulgaris (AV) is a chronic inflammatory disorder of the pilo-sebaceous unit, which is characterized by open and closed comedones, inflammatory papules, pustulae, nodules and cysts, which may lead to scar formation and altered pigmentation (2). Abnormal follicular keratinization, increased sebum production, *Propionibacterium acnes* colonization and inflammation are accused for the pathogenesis of AV (2).

Herein we report a pediatric patient who was started systemic isotretinoin due to severe nodular cystic AV but could not continue due to elevated liver enzymes and well response to systemic dapsone treatment.

CASE PRESENTATION

A 14-year-old male patient was admitted to Dermatology Clinic due to widespread nodular cystic acne. Dermatologic examination revealed widespread nodular cystic acne lesions on the face, shoulders, and anterior side of the trunk (Figure 1). It was learned that he did not respond to systemic and local antibiotic therapies given due to nodular cystic AV.

He was planned to commence isotretinoin 20 mg daily and increase gradually; however, the dose was decreased to 10 mg

ORCID IDs of the authors: M.D. 0000-0002-6614-1821; S.A.T. 0000-0003-4878-0045.



Corresponding Author/Sorumlu Yazar: Selami Aykut Temiz
E-posta: aykutmd42@gmail.com

Received Date/Geliş Tarihi: 09.09.2018 Accepted Date/Kabul Tarihi: 05.05.2019

©Copyright 2020 by University of Health Sciences Turkey Gaziosmanpaşa Training and Research Hospital. Available on-line at www.jarem.org

©Telif Hakkı 2020 Sağlık Bilimleri Üniversitesi Gaziosmanpaşa Eğitim ve Araştırma Hastanesi. Makale metnine www.jarem.org web sayfasından ulaşılabilir.

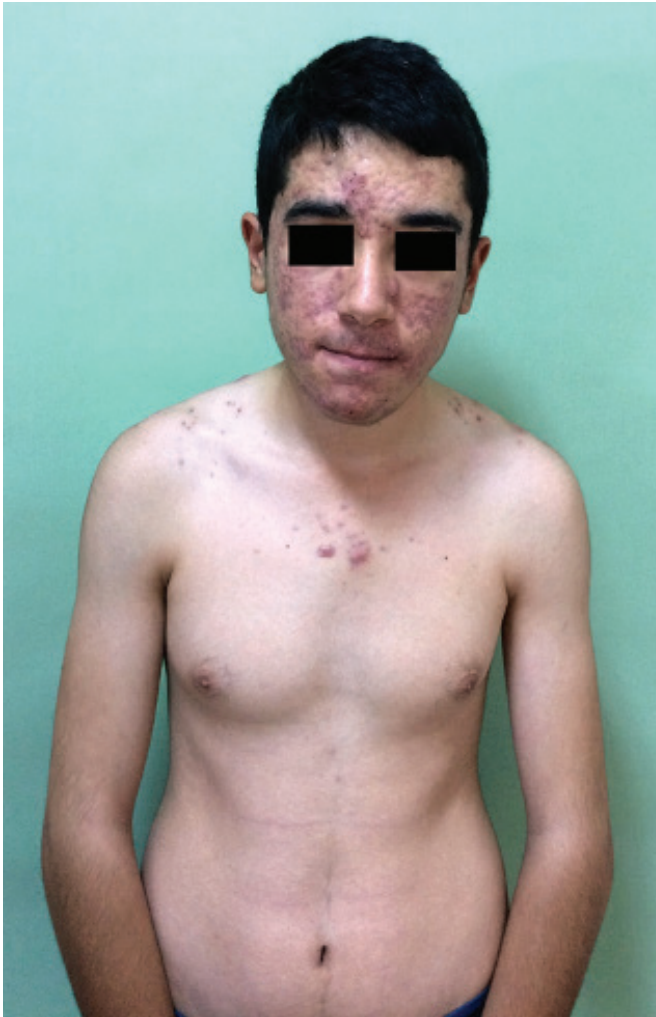

Figure 1. Widespread nodular cystic acne lesions on the face, shoulders, anterior side of the trunk

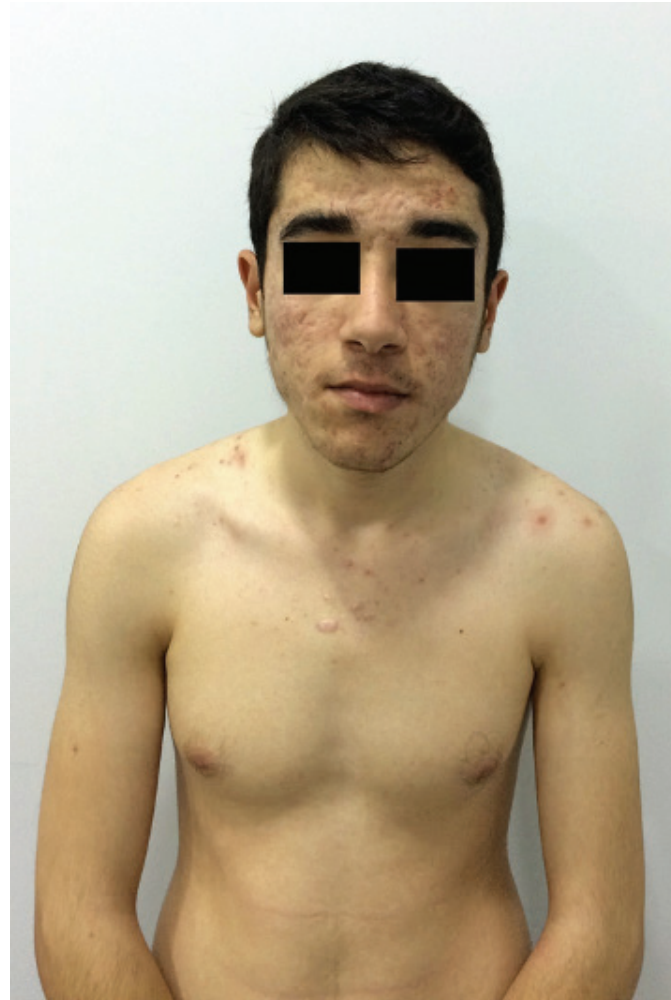


Figure 2. Active nodular cystic lesions dramatically regressed at the 6th month of treatment and atrophic scars developed

daily due to elevated liver enzymes at the first month of therapy. Isotretinoin was discontinued at the control two weeks later due to the detection of aspartate aminotransferase 192 U/L, alanine aminotransferase 406 U/L and gastro-enterology consultation was made. Viral panel results and auto-antibody test results (anti-nuclear antibodies, anti-mitochondrial antibodies, anti-smooth muscle antibodies) were negative. Elevated liver enzymes were suggested to be associated with isotretinoin and turned to normal after the cessation of the drug.

Dapsone treatment via per-oral route was planned as the patient could not tolerate isotretinoin and was negatively affected from nodular cystic AV. Glucose-6-phosphate dehydrogenase enzyme level was normal. Lesions were detected to regress after using dapsone in the dose of 50 mg daily so the dose was increased to 100 mg daily. Lesions were dramatically regressed after using dapsone 100 mg daily for 4 months and 50 mg daily for 2 months. Whole blood count and routine biochemistry tests were found to be normal during the treatment. Active nodular cystic lesions dramatically regressed at the 6th month of the treatment and atrophic scars developed (Figure 2). Informed consent was

obtained from the patient and his mother for the publication of this case report and images.

DISCUSSION

AV is a chronic inflammatory disorder of the pilo-sebaceous unit which affects approximately 80% of adolescents and young adults (3). While topical treatment is sufficient in mild forms of AV, systemic treatment is required in moderate and severe forms. Isotretinoin used via per-oral route is the most effective therapeutic agent used for the treatment of moderate/severe acne for longer than 30 years and it influences all factors in the pathogenesis of acne and provides long term remission (4). Isotretinoin used via per-oral route which has tolerable muco-cutaneous and systemic side effects keeps its place in the treatment of acne due to its effectiveness and safety (5).

No consensus is available about an effective treatment option when isotretinoin cannot be used due to toxicity. In literature, Didona et al. (6) have reported the use of dapsone in a 14-year-old patient whose acne progressed under isotretinoin treatment, and Wakabayashi et al. (7) reported a dramatic response with

dapsone treatment in 5 Japanese patients. We planned to use dapsone in our patient who could not use systemic isotretinone due to elevated liver enzymes.

The mechanism of action of dapsone is obscure in inflammatory diseases; however, it is suggested to inhibit neutrophil chemotaxis and lysosomal enzymes (8). Dapsone is among the treatment options in diseases like bullous pemphigoid, eosinophilic folliculitis, Sweet syndrome, erythema elevatum diutinum, leukocytoclastic vasculitis, pyoderma gangrenosum, bullous form of lupus erythematosus, relapsing poly-chondritis and rheumatic fever besides dermatitis herpetiformis, sub-corneal pustular dermatosis, erythema elevatum dutinum in which it is used as the first choice of treatment (8). Dapsone was suggested to be able to be effective in the treatment of acne due to having anti-bacterial and anti-inflammatory effect (9).

Studies have been reported about the effectiveness of topical dapsone treatment in AV (9). The use of per-oral dapsone was reported in acne fulminans (10). However, limited data are available about systemic dapsone use in AV. Didona et al. (6) have reported a case report about the effectiveness of dapsone in nodular cystic acne. Wakabayashi et al. (7) have also reported good outcomes about the use of per-oral dapsone in persistent acne. We could obtain satisfactory response with per-oral dapsone treatment.

CONCLUSION

We consider that per-oral dapsone treatment may be a well-tolerated and effective treatment option in patients with moderate/severe, frequently recurring AV which is irresponsive to conventional therapies and dapson can be used for AV in patients who improve severe side effects.

We believe that further prospective clinical studies that will be conducted with more patients and will investigate the effectiveness of dapsone in AV are required.

Informed Consent: Informed consent was obtained from the patient and his mother for the publication of this case report and images.

Peer-review: Externally peer-reviewed.

Author Contributions: Surgical and Medical Practices - M.D., S.A.T.; Concept - M.D., S.A.T.; Design - M.D., S.A.T.; Data Collection and/or Processing - M.D., S.A.T.; Analysis and/or Interpretation - M.D., S.A.T.; Literature Search - M.D., S.A.T.; Writing Manuscript - M.D., S.A.T.

Conflict of Interest: The authors have no conflict of interest to declare.

Financial Disclosure: The authors declared that this study has received no financial support.

Hasta Onamı: Bu olgu sunumunun ve görüntülerin yayınlanması için hastadan ve annesinden bilgilendirilmiş olur alındı.

Hakem Değerlendirmesi: Editörler kurulu dışında olan kişiler tarafından değerlendirilmiştir.

Yazar Katkıları: Fikir - M.D., S.A.T.; Tasarım - M.D., S.A.T.; Veri toplanması ve/veya işlemesi - M.D., S.A.T.; Analiz ve /veya yorum - M.D., S.A.T.; Literatür Taraması - M.D., S.A.T.; Yazıyı Yazan - M.D., S.A.T.

Çıkar Çatışması: Yazarların beyan edecek çıkar çatışması yoktur.

Finansal Destek: Yazarlar bu çalışma için finansal destek almadıklarını beyan etmişlerdir.

REFERENCES

1. Ashurst JV, Wasson MN, Hauger W, Fritz WT. Pathophysiologic mechanisms, diagnosis, and management of dapsone-induced methemoglobinemia. *J Am Osteopath Assoc* 2010; 110: 16-20.
2. Kraft J, Freiman A. Management of acne. *CMAJ* 2011; 183: 430-5.
3. Leyden JJ. New understandings of the pathogenesis of acne. *J Am Acad Dermatol* 1995; 32: 15-25.
4. Brelsford M, Beute TC. Preventing and managing the side effects of isotretinoin. *Semin Cutan Med Surg* 2008; 27: 197-206.
5. Karadağ AS, Çalka Ö, Akdeniz N. Evaluation of side effects of isotretinoin in 150 patients with acne vulgaris. *Turkderm* 2011; 45: 37-42.
6. Didona D, Paolino G, Donati P, Muscardin LM. Resolution of nodulocystic acne with oral dapsone. *Dermatol Ther* 2017; 30.
7. Wakabayashi M, Fujii N, Fujimoto N, Tanaka T. Usefulness of dapsone for the treatment of Asian severe acne. *J Dermatol* 2013; 40: 502-4.
8. Braun DE, Krüger H, Kahlenberg V, Griesser UJ. Molecular Level Understanding of the Reversible Phase Transformation between Forms III and II of Dapsone. *Cryst Growth Des* 2017; 17: 5054-60.
9. Taylor SC, Cook-Bolden FE, McMichael A, Downie JB, Rodriguez DA, Alexis AF, et al. Efficacy, Safety, and Tolerability of topical dapsone gel, 7.5% for treatment of acne vulgaris by Fitzpatrick Skin Phototype. *J Drugs Dermatol* 2018; 17, 160-7.
10. Tan BB, Lear JT, Smith AG. Acne fulminans and erythema nodosum during isotretinoin therapy responding to dapsone. *Clin Exp Dermatol* 1997; 22, 26-7.