


Managing Male Mammary Maladies

Ian S. Fentiman 

Department of Research Oncology, Guy's Hospital, London, England

ABSTRACT

This review examines the symptoms, need for referral and management of the benign breast conditions which afflict males, together with the steps that are necessary to exclude or confirm male breast cancer. The most common complaint is gynaecomastia, either true or pseudo, and the majority of these cases need reassurance without over-investigation. Drugs that induce breast enlargement are described in order that, when possible, a medication switch can be made. Men receiving endocrine therapy for prostate cancer may develop painful gynaecomastia and this can be relieved with tamoxifen. All men with breast cancer need mammography as part of their work-up but this should not be used as a screening technique for symptomatic males. Because of lack of lobular development, both cysts and fibroadenomas are very rare in men; but those with nipple discharge need referral and investigation as some will have underlying malignancy.

Keywords: Male breast cancer, gynaecomastia, prostate cancer, mammography, ultrasound

Cite this article as: Fentiman IS. Managing Male Mammary Maladies. Eur J Breast Health 2018; 14: 5-9.

Introduction

It is important to appreciate that men presenting with breast problems are in unfamiliar territory. Unlike their female counterparts, they may have had little experience of medicine having been spared the problems of menstruation, contraception and childbirth. Whereas the majority of women with a breast problem will consult their general practitioner (GP) within a month, there may be long delays for men since the majority do not consider themselves as being at risk for serious breast problems.

For many, the embarrassment of having to attend a largely female-orientated breast clinic needs to be assuaged by a sympathetic and open consultation so that the reassurance given does not fall on deaf ears for the majority. The gender differences are important and significant and a "one size fits all" approach will at best be counterproductive and at worst give rise to serious misunderstandings with potential for acrimonious litigation.

Kipling et al. (1) administered a questionnaire to males attending a breast clinic over an 18-month-long period which was completed by 78. The age range was from 18 to 78 years and the average duration from the start of symptoms to clinic attendance was 6.65 months. Twenty two (28%) of those responding admitted to being embarrassed about consulting their GP for a breast problem and 16 (20%) were embarrassed in the Breast Clinic. When offered the chance of a male-only clinic but with a longer waiting time for an appointment, the men preferred a mixed gender clinic almost unanimously.

In terms of breast structure, before puberty, there is no gender difference so there is fibrofatty tissue containing ducts with a single lining of epithelial cells surrounded by myo-epithelium. The pubertal testosterone surge leads to involution of the ducts with the adult male breast comprising fat, stroma and a vestigial nipple-areolar complex attached to a blind-ending ductal system, without lobules and with no supporting ligaments of Astley Cooper. This paucity of anatomical structure has important consequences for the presentation of male breast diseases.

As an example of the spectrum of male breast disease, Singh et al. (2) reported cytological finding in a series of 119 men attending a breast clinic. Their results are summarised in Table 1.

Address for Correspondence :

Ian S. Fentiman , e-mail: ian.fentiman@kcl.ac.uk

Received: 24.10.2017
Accepted: 30.11.2017

Table 1. Spectrum of male breast disease subjected to cytology (Singh 2012) (2)

Total	Benign	MBC	Gynae-comastia	Inflammation or abscess	Duct papilloma	Lipoma	Benign change
119 (100%)	105 (88%)	14 (12%)	86 (72%)	3 (2.5%)	1 (1%)	1 (1%)	14 (12%)

Table 2. Drugs and gynaecomastia (Deepinder 2012) (3)

Definite cause	Probable association
Spirolactone	Risperidone
Cimetidine	Verapamil
Ketoconazole	Nifedipine
Human growth hormone (hGH)	Omeprazole
Estrogens	Alkylating agents
Human chorionic gonadotrophin (HCG)	Anti-HIV Efavirenz
Antiandrogens	Anabolic steroids
Gonadotrophin releasing analogues (GnRH)	Alcohol
5 alpha reductase inhibitors	Opioids

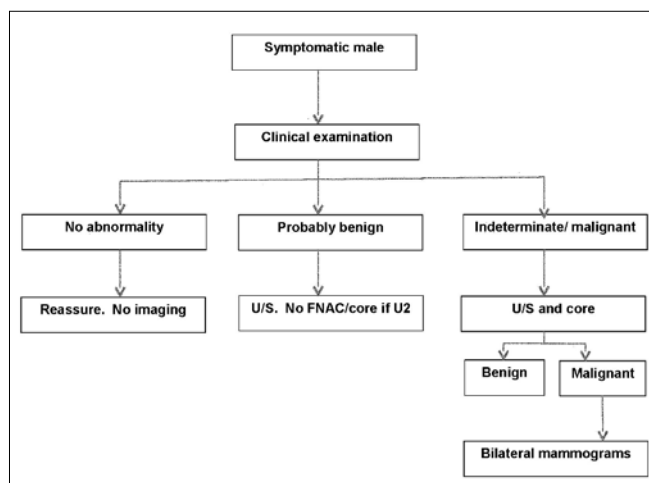


Figure 1. Breast Clinic management of symptomatic males

Assessment in Primary Care

In trying to maintain a balance between over-referral of men with breast problems and missing a rare disease, i.e., male breast cancer, the primary care physician is in a difficult position. Presenting symptoms in men may vary from breast enlargement (gynaecomastia), mastalgia, lump and discharge to nipple distortion. The major cause of gynae-comastia is obesity, which gives rise to pseudogynae-comastia resulting from excess deposition of subcutaneous fat but without any enlargement of the underlying mammary glandular tissue.

Several frequently used medications may produce gynae-comastia and those drugs that have been definitely and probably implicated in increasing risk are detailed in Table 1, Table 2 (2, 3). When possible, a switch of medication may be of benefit, but this may not be an option if the patient is receiving an essential and irreplaceable therapy.

Prostate cancer-associated gynae-comastia

For men with prostate cancer receiving palliative therapies including non-steroidal antiandrogens (bicalutamide, flutamide and nilutamide),

gynae-comastia with or without mastalgia is a common problem, affecting up to 79% of patients (4). There is however evidence of effective therapy based on the results of three randomised trials (5-7). Perdon et al. (5) used a 3-way randomisation with 51 patients receiving bicalutamide 150 mg daily, 50 taking bicalutamide 150 mg plus tamoxifen 10 mg for 24 weeks and 50 patients given bicalutamide 150 mg per day preceded by breast irradiation (12-Gy in one fraction) the day before starting bicalutamide. Of those taking bicalutamide alone, gynae-comastia and/or mastalgia developed in 35 (69%) and they were subsequently randomised to tamoxifen (17 patients) or breast irradiation (18 patients). Gynae-comastia developed in 4/50 (8%) of those given tamoxifen and 17/50 (34%) men were treated with breast irradiation. Skin rash or erythema occurred in 2 men in each of the bicalutamide and bicalutamide/tamoxifen groups compared with 22 in the irradiated group.

Among the 35 patients originally assigned to bicalutamide, who developed gynae-comastia/mastalgia, tamoxifen significantly reduced the incidence of gynae-comastia.

In order to determine the optimum tamoxifen dose for reducing gynae-comastia and/or mastalgia, Fradet et al. (6) conducted a double-blind, parallel-group, multicentre trial comprising 282 men with prostate cancer who were randomised to bicalutamide 150 mg daily for 12 months plus tamoxifen at a dose of 1 mg, 2.5 mg, 5 mg, 10 mg, 20 mg or placebo. This was followed by 12 months of bicalutamide alone and results are shown in Table 3. This indicates the dose response with significant reduction in symptoms at dosages >2.5mg compared with placebo. Hot flushes occurred in 8% of the placebo group compared with 20% of those taking tamoxifen 20 mg daily.

In an Italian trial, Bedognetti et al. (7) compared two different tamoxifen schedules in 80 patients with prostate cancer who were suitable for bicalutamide monotherapy. Patients were randomised to either daily (41 patients) or weekly (39 patients) tamoxifen, the latter being given tamoxifen originally for 8 weeks. Treatment was discontinued because of side effects in 3 patients in the weekly group and 1 in the daily group. Of the men in the daily group, breast symptoms developed in 13 (32%) compared with 29 (74%) in the weekly group. Because of this lack of efficacy of the weekly tamoxifen schedule (the daily schedule is effective), the trial was halted prematurely. There was no increase in venous thromboembolism in any of the tamoxifen trials. Taken together, these studies suggest that tamoxifen at a dosage of 20 mg is an effective and reasonably well-tolerated therapy for antiandrogen-induced gynae-comastia and mastalgia and this treatment could be started in primary care. Nevertheless, the long-term side effects and impact on prognosis are not known warranting the set-up of well-designed large randomised trials (RCTS).

In men with benign prostatic hypertrophy (BPH), 5-alpha reductase inhibitors (5ARIs) are of value, but may increase the risk of breast enlargement. Hagberg et al. (8) conducted a cohort study of men aged >40 years with BPH and determined exposure to 5ARIs (dutasteride or finasteride) or alpha blockers, ABs (Terazosin, Doxazosin, Alfuzosin, Tamsulosin and Silodosin). Compared with no exposure, there was a threefold increase in risk of gynae-comastia risk for men taking 5ARIs

Table 3. Breast symptoms with bicalutamide in relation to tamoxifen dose (Fradet 2007) (6)

Time	Placebo	1mg	2.5mg	5mg	10mg	20mg
6 months	98%	90%	80%	54%	22%	10%
12 months	99%	95%	84%	56%	38%	19%

alone or together with ABs. There was however no increase in the risk for male breast cancer associated with 5ARIs or ABs in this study.

Body builders

Body builders may take a “stack” of non-prescription anabolic steroids, predisposing to gynaecomastia and this practice is very widespread (9). Evans surveyed 100 athletes at 4 gyms in Wales with an anonymous self-administered questionnaire (10). All were using anabolic steroids and 15% had taken them for 6-12 years at dosages of from 250 to 3200 mg per week. Side effects included acne, striae, and gynaecomastia together with withdrawal symptoms. Calzada et al. (11) administered anabolic steroids including nandrolone decanoate, Ropionate, phenilpropionate, isocaproate and testosterone decanoate to 12 bodybuilders over 6 months and compared steroid hormone levels in their blood with that of 10 healthy controls (11). In the bodybuilders, there was a >50% reduction in testosterone and LH and FSH levels were reduced by 23% and 13%, respectively compared with controls. A further risk is thrombophlebitis (Mondor’s syndrome) which may simulate malignancy by causing skin retraction (12). De Vries et al. (13) reported a 29-year-old male with a painless breast lump who had been diagnosed with gynaecomastia 4 years ago following anabolic steroid abuse. This proved at excision biopsy to be an intraduct papilloma.

Mastalgia may often arise from the rib cage and this can be verified by identifying the trigger point. Treatment is reassurance with occasional recourse to NSAIDs. Gynaecomastia with associated pain can be distressful for men with prostate cancer. If the pain is prolonged and severe, referral should be considered since some may benefit from tamoxifen therapy. For individuals with a discrete lump, nipple discharge, distortion or unilateral gynaecomastia, malignancy is a possibility; therefore, urgent referral to a breast clinic is advisable.

Breast Clinic assessment of symptomatic males

Although the principles of clinical evaluation of men with breast symptoms are similar to those used in females, there are still some important differences. In terms of history-taking, a family history of female breast cancer (FBC) and occasionally male breast cancer (MBC) should be inquired after eliciting the presenting sign(s) and duration. For the reproductive history, those who are in a heterosexual partnership but without children should be asked whether this was out of choice. Prior testicular damage or undiagnosed Klinefelter’s syndrome may be responsible for male infertility with an associated increase in the risk for MBC. Many of these patients will be retired, but their prior occupation should be inquired since some such as blast furnace workers may have testicular malfunction due to a prolonged high ambient temperature. As described previously, the drug history may indicate possible cause(s) for gynaecomastia.

Clinical examination

After inspection and palpation of the breasts, axillae and neck with the patient in the supine position, he is then asked to turn halfway on his side so that the palpation can be repeated both facing towards and away from the examiner. If there is nipple discharge, this should be tested for the presence of occult blood. Following the breast examination, the abdomen is palpated to determine whether hepatomegaly is present

together with any evidence of hepatic dysfunction. Finally, the testes should be examined for signs of atrophy or tumour. The clinician should then be in a position to make a working diagnosis and determine the need for further evaluation. Selection of imaging should be based on the benefits and disadvantages of mammography and ultrasound.

Mammography

Whereas mammography plays an intrinsic role in the investigation of women aged >40 who have breast symptoms, this should not be the default position for males. Although mammography may be reasonably comfortable for men with grade III/IV gynaecomastia, for others it can be very painful and of little value. As part of the work-up of men with male breast cancer, mammography is mandatory in order to determine the extent of disease and to exclude contralateral cancer. As a screening investigation, it is of dubious value.

Hanavadi et al. (14) carried out an audit of all 220 male patients referred to the breast clinic at the University Department of Surgery, Cardiff between January, 2001 and December, 2003. Mammography was carried out in 134 (61%), usually before the patient was seen by a clinician. There was a total of 4 cancers diagnosed and in every case the diagnosis was suspected on clinical examination and subsequently confirmed histologically. It was concluded that mammography was unnecessary for most males and did not have a role in routine imaging.

Hines et al. from (15) the Mayo Clinic reviewed the mammograms of 198 men who had 212 mammograms of which 9 (4%) showed suspicious signs. Eight men underwent biopsy, which yielded a breast cancer diagnosis in 2 (1%). Of the 212 mammograms, 203 (96%) showed benign findings, including gynaecomastia on 132 (62%). One patient with a benign-appearing mammogram later underwent breast biopsy, and malignant disease was diagnosed. All the men with breast cancer had a dominant mass on clinical examination and other findings suggestive of breast cancer. Of the 132 mammograms showing gynaecomastia, 110 (83%) were from men who had taken predisposing medications or who had predisposing medical conditions. The conclusion was that mammography added little information to the initial patient evaluation, being of benefit only for image-guided biopsy of a suspicious mass.

Lapid et al. (16) reported the outcomes of imaging with mammography or ultrasound of the male breast in 557 patients seen over a 10-year period. The most common reason for referral was breast enlargement present in 74% of patients: 25% complained of pain and 10% had a lump. The majority of images were reported as BI-RADS 1 or 2, with only 38 being BI-RADS 3 or higher. Cancer was diagnosed in five patients (0.89%) and all of these had suspicious symptoms and signs. The probability of finding cancer with clinically benign examination was negligible. They concluded that imaging was unnecessary unless there were suspicious clinical abnormalities present and routine imaging of gynaecomastia should be discouraged. This is important both in terms of patient comfort and conservation of resources.

Ultrasound

Chen et al. (17) determined the incremental benefit of ultrasound in males with gynaecomastia who had normal mammograms. In a retrospective study, those whose ultrasound diagnosis differed from the initial mammographic evaluation were analysed in relation to extra benign findings together with signs that warranted biopsy. Out of 353 mammograms in males aged 18–95, gynaecomastia was the sole finding in 259 (73%). Ultrasound was performed in 220 cases (85%) resulting in 6 (2.7%) having further benign findings, and 4 (2%) with suspicious findings which were biopsied but no cancers were found. All cases of the cancers manifested with visible masses on mammography. This indicates the limited value of ultrasound which may lead to more unnecessary biopsies. An outline of management of male cases, based on the available evidence, is shown in Figure 1.

Spectrum of male breast diseases

Gynaecomastia

The most frequent male complaint is gynaecomastia, either true or pseudo, and the primary need is for reassurance. When accompanied by pain, the cause is often linked to medication and relief may be obtained by modification of drug or dosage. When this is not possible, tamoxifen can be of value in both relieving pain and diminishing the size of the swelling. Because of embarrassment, some men with grade III gynaecomastia may ask for surgery. In a series of 1261 men seen over a 10-year period at the Frenchay Hospital Bristol, 938 (74%) had gynaecomastia and surgery (subcutaneous mastectomy) was performed on 224 (18). Post-operative complications were infrequent: the most common one being haematoma (12%), followed by seroma (3%), infection (1%), wound dehiscence (1%) and nipple necrosis (1%). Further surgery was necessary in only 3%.

Because standard surgery with excision through periareolar or T-shaped can produce extensive scarring, Bailey et al. (19) developed a different approach using liposuction followed by a pull-through technique to remove glandular tissue. In a series of 75 patients with gynaecomastia, the proportions of grade I-IV were 31%, 36%, 23% and 10%, respectively. There were no complications in this series. Ultrasound assisted liposuction was performed through a 2-4 mm stab wound in the lateral inframammary fold. Following this, a Kocher clamp was inserted through the same incision site and glandular tissue was grasped and pulled externally before being excised. Only one patient required re-operation and there were no complications of the procedure which achieved acceptable cosmetic results.

In a study from Rigshospitalet, Copenhagen, 786 men with gynaecomastia underwent clinical examination, testicular ultrasound of the testicles and endogenous serum hormones assays (20). Of those aged ≥ 18 years, underlying causes were identified in 43% whereas an abnormality was detected in only 8% of younger men. This suggests that a careful clinical examination and endocrine profile is important for identifying older individuals with potentially treatable causes for gynaecomastia.

Other male breast lumps

The most common benign breast lumps in females are cysts and fibroadenoma. However, as both are derived from lobules, which do not normally develop in males, they are rare conditions in men. Robertson et al. (21) described a 27-year old male with fibrocystic change in association with papillary hyperplasia. Parsian et al. (22) reported a benign breast cyst in a 58-year old male who was undergoing staging tests for mantle cell lymphoma.

In a study from the US Armed Forces Institute of Pathology, there were only 4 fibroadenomas in male breasts, all of which had co-existent gynaecomastia with lobular development (23). Fibroadenomatoid hyperplasia has been described in association with long-term spironolactone medication and fibroadenoma can develop as a result of leuprolide treatment for prostatic cancer (24, 25). Ashutosh et al. (26) reported a 72-year-old man who presented with a giant fibroadenoma (25 cm) having received 4 years of anti-androgen therapy for prostate carcinoma after orchidectomy.

Fat necrosis

Fat necrosis may manifest as a breast lump, sometimes with skin tethering, hence malignancy may be suspected. Predisposing factors include trauma, prior breast surgery, radiotherapy and occasionally in those on warfarin anticoagulation. The first case of a male with fat necrosis of the breast was described by Silverstone in 1949; although this was confirmed histologically, there was no past history of trauma, nor any other apparent causes (27). Akyol et al. (28) reported a 57-year-old male with a left breast lump one year following chest trauma. On examination, there were hard, fixed lumps in the upper outer quadrant with no axillary lymphadenopathy. Ultrasound showed a combination of scattered small cysts together with a complex cyst with two irregularly isoechoic solid masses which projected into the cyst. Additionally, there were scattered, well-circumscribed subcutaneous lesions with a posterior enhancement.

Fat necrosis elicits a fibrotic reaction and the appearance is mammographically affected by the extent of fat liquefaction (oil cysts) and occasionally associated microcalcification. There may be a classical oil cyst, a radiolucent lesion with a thin surrounding membrane. Intense fibrotic reactions display irregular, or poorly defined margins, sometimes replacing the cyst to form a spiculated mass mimicking malignancy.

Nipple discharge

Johnson & Kini reviewed 225 patients with nipple discharge of whom 9 were male (29). There was a significantly increased risk for cancer in males: 2/9 (22%) versus 3/216 (1.5%) in females. Detraux et al. (30) reported 7 males with unilateral nipple discharge but with no palpable abnormality. They used galactography to determine the underlying cause, which was cancer in 2 cases, both of whom had bloody discharge. Another 2 had benign papillomas (one bloody, one serous), 2 had duct ectasia (both non-bloody) and 1 had a breast abscess (serous), and two were ductal ectasia (non-bloody).

Morrogh and King reported 24 males with breast problems seen at Sloan-Kettering Memorial between 1995 and 2005 (31). Of these, 14 (58%) complained of nipple discharge whereas the other 10 (42%) had palpable lumps with no discharge. Of those with nipple discharge, 7 (50%) had a lump present on palpation. Cancer was the underlying cause of the discharge in 8/14 (57%) and this was DCIS in 2 and invasive disease in 6 patients. This does indicate the need for hospital referral to evaluate all men with nipple discharge.

Hyperprolactinaemia is a side effect of long-term phenothiazine administration and may lead to the development of papillomas in males. Sara et al. (32) described a 71-year-old white male who had received thioridazine followed by fluphenazine for several years and developed coffee-coloured left nipple discharge. The discharge stopped 6 months before he was seen and the breast enlarged with a 10 cm subareolar mass. At surgery, this proved to be a cyst containing an intraductal papilloma. In males, intraduct papillomas are more likely to present as breast lumps rather than with a nipple discharge (33).

Reid-Nicholson et al. (34) reported a series of 11 males with papillary breast lesions, all of whom had breast lumps. The age range was from 23-78 years of age with masses measuring 0.5-3 cm. Cytology showed smears of varying cellularity but there were consistently papillary clusters of epithelial cells with and without fibrovascular cores. Only 2 males had a bloody nipple discharge and both had benign papillomas.

Peer-review: Externally peer-reviewed.

Conflict of Interest: No conflict of interest was declared by the author.

Financial Disclosure: The author declared that this study has received no financial support.

References

- Kipling M, Ralph JEM, Callanan K. Psychological impact of male breast disorders: literature review and survey results. *Breast Care (Basel)* 2014; 9: 29-33. (PMID: 24803884) [CrossRef]
- Singh R, Anshu, Sharma SM, Gangane N. Spectrum of male breast lesions diagnosed by fine needle aspiration cytology: a 5-year experience at a tertiary care rural hospital in Central India. *Diagn Cytopathol* 2012; 40: 113-117. (PMID: 22246926) [CrossRef]
- Deepinder F, Braunstein GD. Drug-induced gynecomastia: an evidence-based review. *Expert Opin Drug Saf* 2012; 11: 779-795. (PMID: 22862307) [CrossRef]
- McLeod DG, Iversen P. Gynecomastia in patients with prostate cancer: a review of treatment options. *Urology* 2000; 56: 713-720. (PMID: 11068286) [CrossRef]
- Perdonà S, Autorino R, De Placido S D'Armiento M, Gallo A, Damiano R, Pingitore D, Gallo L, De Sio M, Bianco AR, Di Lorenzo G. Efficacy of tamoxifen and radiotherapy for prevention and treatment of gynecomastia and breast pain caused by bicalutamide in prostate cancer: a randomised controlled trial. *Lancet Oncol* 2005; 6: 295-300. (PMID: 15863377) [CrossRef]
- Fradet Y, Egerdie B, Andersen M, Tammela TLJ, Nachabe M, Armstrong J, Morris T, Navani S. Tamoxifen as prophylaxis for prevention of gynecomastia and breast pain associated with bicalutamide 150 mg monotherapy in patients with prostate cancer: a randomised, placebo-controlled, dose-response study. *Eur Urol* 2007; 52: 106-114. (PMID: 17270340) [CrossRef]
- Bedognetti D, Rubagotti A, Conti G, Francesca F, De Cobelli O, Canciani L, Gallucci M, Aragona F, Di Tonno P, Cortellini P, Martorana G, Lapini A, Boccardo F. An open, randomised, multicentre, phase 3 trial comparing the efficacy of two tamoxifen schedules in preventing gynecomastia induced by bicalutamide monotherapy in prostate cancer patients. *Eur Urol* 2010; 57: 238-245. (PMID: 19481335) [CrossRef]
- Hagberg KW, Divan HA, Fang SC, Nickel JC, Jick SS. Risk of gynecomastia and breast cancer associated with the use of 5-alpha reductase inhibitors for benign prostatic hyperplasia. *Clin Epidemiol* 2017; 9: 83-91. (PMID: 28228662) [CrossRef]
- Reyes RJ, Zicchi S, H Hamed H, Chaudary MA & Fentiman IS. Surgical correction of gynecomastia in bodybuilders. *Br J Clin Pract* 1995; 49: 177-179. (PMID: 7547155)
- Evans NA. Gym and tonic: a profile of 100 male steroid users. *Br J Sports Med* 1997; 31: 54-58. (PMID: 9132214) [CrossRef]
- Calzada L, Torres-Calleja J, Martinez JM, Pedrón N. Measurement of androgen and estrogen receptors in breast tissue from subjects with anabolic steroid-dependent gynecomastia. *Life Sci* 2001; 69: 1465-1469. (PMID: 11554608) [CrossRef]
- Trobinger C, Wiedermann CJ. Bodybuilding-induced Mondor's disease of the chest wall. *Phys Ther Sport* 2017; 23: 133-135. (PMID: 27769805) [CrossRef]
- de Vries FEE, Walter AW, Vrouenraets BC. Intraductal papilloma of the male breast. *J Surg Case Rep* 2016 2: 1-2. (PMID: 26860828) [CrossRef]
- Hanavadi S, Monypenny IJ, Mansel RE. Is mammography overused in male patients? *Breast* 2006; 15: 123-126. (PMID: 16473746) [CrossRef]
- Hines SL, Tan WW, Yasrebi M, DePeri ER, Perez EA. The role of mammography in male patients with breast symptoms. *Mayo Clin Proc* 2007; 82: 297-300. (PMID: 17352365) [CrossRef]
- Lapid O, Siebenga P, Zonderland HM. Overuse of imaging the male breast-findings in 557 patients. *Breast J* 2015; 21: 219-223. (PMID: 25772378) [CrossRef]
- Chen P-H, Slanetz PJ. Incremental clinical value of ultrasound in men with mammographically confirmed gynecomastia. *Eur J Radiol* 2014; 83: 123-129. (PMID: 24161780) [CrossRef]
- Al-Allak A, Govindarajulu S, Shere M, Ibrahim N, Sahu AK, Cawthorn SJ. Gynaecomastia: A decade of experience. *Surgeon* 2011; 9: 255-258. (PMID: 21843819) [CrossRef]
- Bailey SH, Guenther D, Constantine F, Rohrich RJ. Gynecomastia management: an evolution and refinement in technique at UT Medical Center. *Plast Reconstr Surg Glob Open* 2016; 4: e734. (PMID: 27482482) [CrossRef]
- Mieritz MG, Christiansen P, Jensen MB, Joensen UN, Nordkap L, Olesen IA, Bang AK, Juul A, Jørgensen N. Gynaecomastia in 786 adult men: clinical and biochemical findings. *Eur J Endocrinol* 2017; 176: 555-566. (PMID: 28179453) [CrossRef]
- Robertson KE, Kazmi SA, Jordan LB. Female-type fibrocystic disease with papillary hyperplasia in a male breast. *J Clin Pathol* 2010; 63: 88-89. (PMID: 20026704) [CrossRef]
- Parsian S, Rahbar H, Rendi MH, Lehman CD. Benign Breast Cyst without Associated Gynecomastia in a Male Patient: A Case Report. *J Radiol Case Rep* 2011; 5: 35-40. (PMID: 22470772) [CrossRef]
- Ansah-Boateng Y, Tavassoli FA. Fibroadenoma and cystosarcoma phyllodes of the male breast. *Mod Pathol* 1992; 5: 114-116. (PMID: 1315437)
- Nielsen BB. Fibroadenomatoid hyperplasia of the male breast. *Am J Surg Pathol* (1990) 14:774-7. *Am J Surg Pathol* 1990; 14: 774-777. (PMID: 2378397) [CrossRef]
- Shin SJ, Rosen PP. Bilateral presentation of fibroadenoma with digital fibroma-like inclusions in the male breast. *Arch Pathol Lab Med* 2007; 131: 1126-1129. (PMID: 17617003)
- Ashutosh N, Virendra K, Attri PC, Arati S. Giant male fibroadenoma: a rare benign lesion. *Indian J Surg* 2013; 75: 353-355. (PMID: 24426614) [CrossRef]
- Silverstone M. Fat necrosis of the breast with report of a case in a male. *Br J Surg* 1949; 37: 49-52. (PMID: 18135656) [CrossRef]
- Akyol M, Kayali A, Yildirim N. Traumatic fat necrosis of male breast. *Clin Imaging* 2013; 37: 954-956. (PMID: 23849832) [CrossRef]
- Johnson TL, Kini SR. Cytologic and clinicopathologic features of abnormal nipple secretions: 225 cases. *Diagn Cytopathol* 1991; 7: 17-22. (PMID: 1851079) [CrossRef]
- Detraux P, Benmussa M, Tristant H, Garel L. Breast disease in the male: galactographic evaluation. *Radiology* 1985; 154: 605-606. (PMID: 2982173) [CrossRef]
- Morrogh M, King TA. The significance of nipple discharge of the male breast. *Breast J* 2009; 15: 632-638. (PMID: 19735390) [CrossRef]
- Sara AS, Gottfried MR. Benign papilloma of the male breast following chronic phenothiazine therapy. *Am J Clin Pathol* 1987; 87: 649-650. (PMID: 3578141) [CrossRef]
- Durkin ET, Warner TF, Nichol PF. Enlarging unilateral breast mass in an adolescent male: an unusual presentation of intraductal papilloma. *J Pediatr Surg* 2011; 46: e33-5. (PMID: 21616226) [CrossRef]
- Reid-Nicholson MD, Tong G, Cangiarella JF, Moreira AL. Cytomorphologic features of papillary lesions of the male breast. A Study of 11 Cases. *Cancer* 2006; 108: 222-230. (PMID: 16721805) [CrossRef]