



# Radiation Fibrosis Syndrome Imitating Breast Cancer Recurrence; A Case Report

Dauren Sarsenov<sup>1</sup>, Fatma Aktepe<sup>2</sup>, Vahit Özmen<sup>3</sup>

<sup>1</sup>Department of General Surgery, İstanbul Florence Nightingale Hospital, İstanbul, Turkey

<sup>2</sup>Department of Pathology, İstanbul Florence Nightingale Hospital, İstanbul, Turkey

<sup>3</sup>Department of General Surgery, İstanbul University İstanbul School of Medicine, İstanbul, Turkey

## ABSTRACT

Nowadays, surgery, radiotherapy and chemotherapy are the most frequently used modalities in the treatment of breast cancer. It is very well-known that some severe complications may result from after these treatments. Early and late complications of radiotherapy are well known. The complications of radiation therapy may be seen in (early) or after three months (late-delayed) of periods. These complications may be related with direct or indirect effect of radiation. The radiation fibrosis syndrome is a progressive fibrotic tissue sclerosis together with various clinical symptoms in the irradiation field. It is usually a late finding of radiation therapy and may be seen weeks or even years after the treatment. Many systems such as musculo-skeletal, soft tissue, neural tissue and cardiopulmonary system may be affected. In this report, we present a case of a breast cancer treated with breast conserving surgery and radiation therapy twelve years ago. The patient had ipsilateral lymphedema, right axillary mass, and pain during arm and shoulder mobilization. Her physical examination and radiologic findings revealed a big mass invading right thoracic wall, thoracic cavity and the axilla. Histopathological evaluation performed after tru-cut and open biopsy from the mass showed fibrosis resulting from radiation therapy.

**Keywords:** Breast cancer, radiation fibrosis syndrome, radiotherapy complications

## Introduction

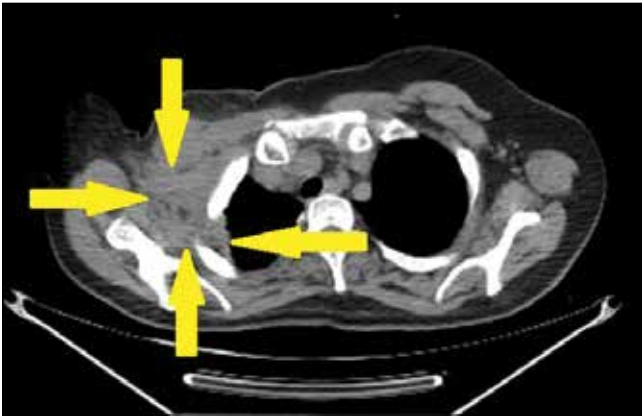
Nowadays, surgery, radiotherapy and chemotherapy are the most frequently used modalities in the treatment of breast cancer. It is very well-known that some severe complications may result from after these treatments. Early and late complications of radiotherapy are well-known. The complications of radiation therapy may be seen in early or late-delayed (after three months) periods. These complications may be related with direct or indirect effects of radiation.

The radiation fibrosis syndrome is a progressive fibrotic tissue sclerosis together with various clinical symptoms in the irradiation field. It is usually a late finding of radiation therapy and may be seen weeks or even years after the treatment. Many systems such as musculoskeletal, soft tissue, neural tissue and cardiopulmonary system may be affected.

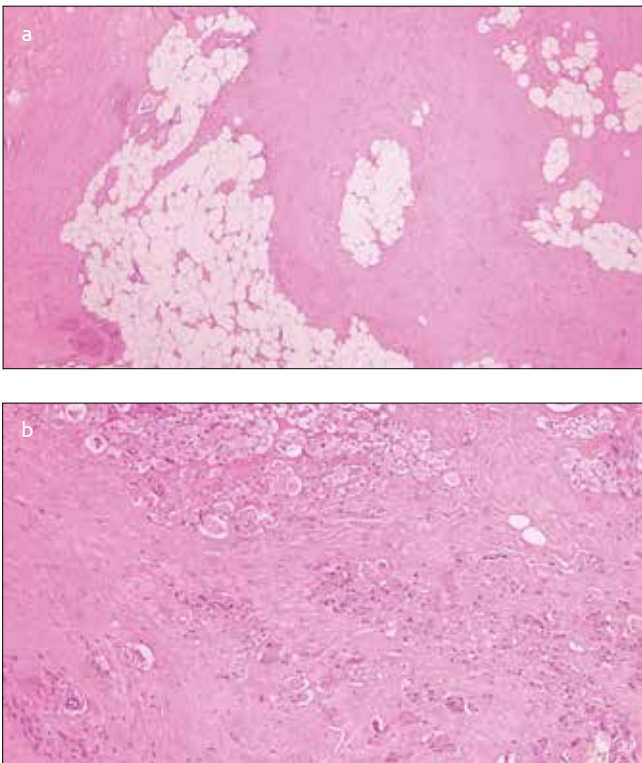
In this report, we present a case of a breast cancer treated with breast-conserving surgery and radiation therapy twelve years ago. The patient had ipsilateral lymphedema, right axillary mass, and pain during arm and shoulder mobilization. A written consent for publication of her data was obtained from the patient. Her physical examination and radiological findings revealed a big mass invading right thoracic wall, thoracic cavity and the axilla. Histopathological evaluation performed after tru-cut and open biopsy from the mass showed fibrosis resulting from radiation therapy.

## Case Report

A sixty-two-year-old female patient who was treated with lumpectomy, axillary lymph node dissection, systemic chemotherapy, radiation therapy and tamoxifen for pT2N1M0 right breast cancer twelve years ago was admitted to our clinics with axillary mass, ipsilateral lymphedema, and pain during arm and shoulder movements. Physical examination revealed rigid mass filling axillary cavity and upper thoracic wall with venous stasis and lymphedema in the right upper extremity. Ultrasonography and chest magnetic resonance imaging were performed demonstrating a big mass invading axillary vascular and neural structures, thoracic wall and pleural cavity (Figure 1). The PET-CT showed an axillary lesion with high FDG activity (SUVmax 7.5) arising suspicion of recurrent breast tumor. Tru-cut biopsy followed

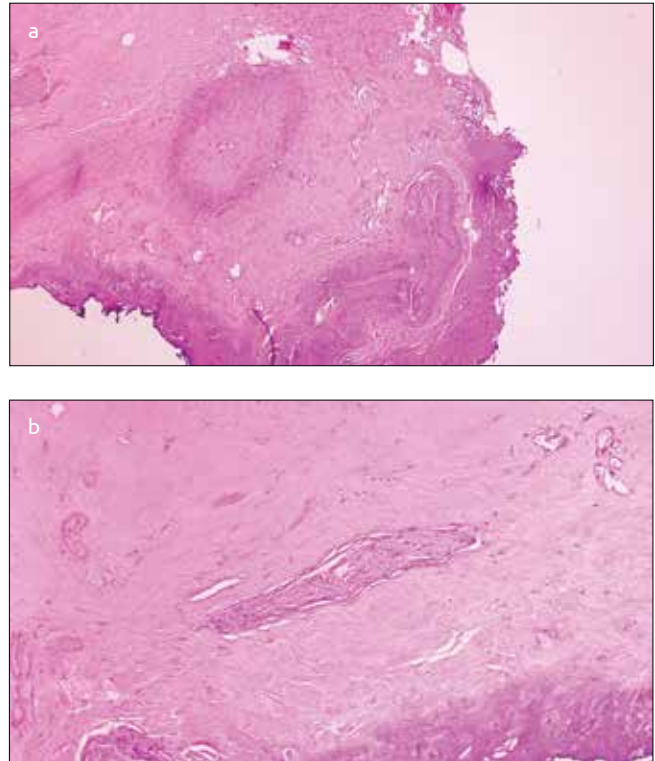


**Figure 1.** CT scan image visualizing axillary mass invading thoracic wall extending to the parietal pleura (tumor borders outlined by yellow arrows)



**Figure 2. a, b.** Adipose tissue (a) and striated muscle tissue (b) infiltrated by fibrohyalinized tissue

by open biopsy was performed to obtain enough material for diagnosis. Histopathological study revealed widely hyalinized fibrotic tissue with spotty hyalinizing necrosis infiltrating adipose tissue and striated muscle tissue (Figures 2a, 2b). Most of the material appeared acellular. Only one microscopic field included fibroblast-like spindle cells, few lymphoid cells and degenerated striated myocytes between them. Fibrotic processes surrounding nerve fascicles and blood vessels were also seen (Figures 3a and 3b). These microscopic findings were found to be similar to extraabdominal fibromatosis, elastofibroma dorsi or radiotherapy-induced changes. Immunohistochemical staining of fibroblast-like cells was negative for beta-catenin or estrogen receptors. Further Weigert elastic staining demonstrated rare broken fibrils. After pathological consultations and re-evaluations, microscopic diagnosis was decided as late term radiation-induced fibrotic-hyalinic changes. The radiation fibrosis syndrome imitating breast cancer recurrence was



**Figure 3. a, b.** Fibrosis in the vessel wall and surrounding tissue (a) with fibrohyalinized tissue compressing nerve fascicles (b)

the final diagnosis. Anti-inflammatory drug and tamoxifen were given to the patient, and she was invited for regular follow-up.

### Discussion and Conclusion

Radiotherapy has been used in most of the cancers as a loco-regional treatment for decades, and its biologic effects are well-known. It causes damage to cells via various routes like free radicals, coagulation system activation by cytokines and growth factors, inflammation induced damage, epithelial alteration with regeneration, scarring and healing processes. This damage can be histopathologically observed in three consecutive terms where the first one is known as the pre-fibrotic phase and is characterized by histiocyte-driven inflammation. The second term (organized fibrosis phase) demonstrates active fibrotic fields containing dense acellular fibrotic patches which are rich in myofibroblasts. The last phase (fibroatrophic phase) is characterized by progressive fibrosis presenting with loss of parenchymal cells (1, 2). The symptoms observed as a result of this process are known as the radiation fibrosis syndrome. Numerous neuromuscular and skeletal complications due to involvement of nerves, muscles, tendons, ligaments, skin, bones and lymphatic system may be seen as a result of progressive fibrosis. Muscular fatigue and neuropathies can be early signs of the process.

The mass in this patient was late phase fibrosis infiltrating the surrounding adipose, muscular and bone tissues and forming keloid-like tissues. It also invaded the neuro-vascular structures, thoracic wall and pleural cavity. The symptoms stated before resulted from the invasion of the tumoral mass into the surrounding tissues. Increased progression of this mass may result in more severe complications such as motion restriction in the shoulder joint.

There is no known exact treatment for patients with advanced fibro-atrophic phase radiation fibrosis syndrome. Physical therapy, anti-

inflammatory drugs, tamoxifen, and palliative surgery have been recommended in some studies (3, 4). Prophylaxis for radiation fibrosis syndrome consists of suitable and meticulous field marking and preservation of tumor-free tissues (5, 6). Some studies show possible benefits of pentoxifylline, vitamin E combination (7). Teguh et al. (8) proposed possible positive effect of hyperbaric oxygenation used for treatment of late cellular toxicity of radiation (8).

Radiation fibrosis syndrome is a rare, but potentially life-threatening complication of the radiation treatment. Recognition of early symptoms may help stabilize the disease; otherwise there will be no more treatment choices in patients with advanced stage as was the case with our patient.

---

**Informed Consent:** Informed consent was obtained from patients who participated in this study.

**Peer-review:** Externally peer-reviewed.

**Author Contributions:** Concept - F.A., V.Ö.; Design - F.A., D.S.; Supervision - V.Ö.; Data Collection and/or Processing - D.S., F.A.; Analysis and/or Interpretation - F.A., D.S.; Literature Review - F.A.; Writing - F.A., D.S.;

Critical Review - F.A., V.Ö.

**Conflict of Interest:** No conflict of interest was declared by the authors.

**Financial Disclosure:** The authors declared that this study has received no financial support.

## References

1. Pohlers D, Brenmoehl J, Löffler I. TGF- $\beta$  and fibrosis in different organs – molecular pathway imprints. *Biochim Biophys Acta* 2009; 1792:746-756. (PMID: 19539753)
2. Delanian S, Lefaix JL. Current management of late normal tissue injury: radiation-induced fibrosis and necrosis. *Semin Radiat Oncol* 2007; 17:99-107. (PMID: 17395040) [[CrossRef](#)]
3. Stubblefield MD. Cancer rehabilitation. *Semin Oncol* 2011; 38:386-393. (PMID: 21600368) [[CrossRef](#)]
4. Stubblefield MD, Burstein HJ, Burton AW, Custodio CM, Deng GE, Ho M, Junck L, Morris GS, Paice JA, Tummala S, Von Roenn JH. NCCN task force report: management of neuropathy in cancer. *J Natl Compr Canc Netw* 2009; 7:S1-26. (PMID: 19755042)
5. Hojan K, Milecki P. Opportunities for rehabilitation of patients with radiation fibrosis syndrome. *Reports of practical oncology and radiotherapy* 2014; 19:1-6. (PMID: 24936313)
6. Hammer C, Maduro JH, Bantema-Joppe EJ, van der Schaaf A, van der Laan HP, Langendijk JA, Crijns AP. Radiation-induced fibrosis in the boost area after three-dimensional conformal radiotherapy with a simultaneous integrated boost technique for early-stage breast cancer: A multivariable prediction model. *Radiother Oncol* 2016; pii:S0167-8140(16)34342-0. (PMID: 27793444)
7. Delanian S, Porcher R, Rudant J, Lefaix JL. Kinetics of response to long-term treatment combining pentoxifylline and tocopherol in patients with superficial radiation-induced fibrosis. *J Clin Oncol* 2005; 23:8570-8579. (PMID: 16260695) [[CrossRef](#)]
8. Teguh DN, Bol Raap R, Struikmans H, Verhoef C, Koppert LB, Koole A, Huang Y, van Hulst RA. Hyperbaric oxygen therapy for late radiation-induced tissue toxicity: prospectively patient-reported outcome measures in breast cancer patients. *Radiat Oncol* 2016; 11:130. (PMID: 27682427)[[CrossRef](#)]