

# Fibroadenom Zemininde Gelişen İnvaziv Duktal Karsinom

## Invasive Ductal Carcinoma Developing From Fibroadenoma

Oğuz Uğur Aydın<sup>1</sup>, Lütfi Soylu<sup>1</sup>, Aydan İlkme Ercan<sup>2</sup>, Banu Bilezikçi<sup>3</sup>, Savaş Koçak<sup>1</sup>

<sup>1</sup>Ankara Özel Güven Hastanesi, Genel Cerrahi Anabilim Dalı, Ankara, Türkiye

<sup>2</sup>Ankara Özel Güven Hastanesi, Radyoloji anabilim Dalı, Ankara, Türkiye

<sup>3</sup>Ankara Özel Güven Hastanesi, Patoloji Anabilim Dalı, Ankara, Türkiye

### ABSTRACT

Fibroadenomas are the most common benign breast lesions in adolescent and young women. It is most frequently observed in the 3rd decade. Although it is considered benign, evidence of malignant transformation is available. Cancer development may be from ground of fibroadenoma or near breast tissue. A case of a fibroadenoma coexisting with an invasive ductal carcinoma of the breast in a 31-year-old female is presented. The patient presented with the chief complaint of having a palpable mass in her right breast for the last 10 years. Mammography revealed a mass with microcalcifications. Core biopsy was performed, and the results indicated an invasive carcinoma. Breast-conserving surgery with sentinel lymph node biopsy was performed. The pathological features revealed a fibroadenoma coexisting with an invasive ductal carcinoma. This case suggests that clinicians and radiologists should always pay attention to the associated malignant imaging characteristics whenever a mass was followed up as fibroadenoma.

**Keywords:** Breast, fibroadenoma, invasive ductal carcinoma

### ÖZ

Fibroadenomlar;adölesan ve genç bayanlarda en sık görülen benign meme kitleleridir.En sık olarak 30'lu yaşlarda gözlenir.Benign olarak kabul edilmesine rağmen malign transformasyonla ilgili kanıtlar mevcuttur.Kanser gelişimi fibroadenom zemininden veya komşu meme dokusundan kaynaklanır.Olguda fibroadenom zemininde invaziv duktal karsinom gelişen 31 yaşındaki bayan hasta sunulmuştur. Hastanın esas şikayeti 10 yıldır sağ memesinde ele gelen kitleydi. Mammografide mikrokalsifikasyonlar içeren kitle tespit edildi. Kitleye kor biyopsi yapıldı ve sonuç invaziv karsinom olarak geldi. Sentinel lenf nodu biyopsisi ile birlikte meme koruyucu cerrahi uygulandı. Histopatolojik inceleme sonucunda fibroadenoma eşlik eden invaziv duktal karsinom olduğu anlaşıldı.Bu olgu fibroadenom tanısıyla izlenen meme kitlelerinde klinisyen ve radyoloğun görüntülemeye olası malign değişimlerle ilgili daima dikkatli olmaları gerektiğini önermektedir.

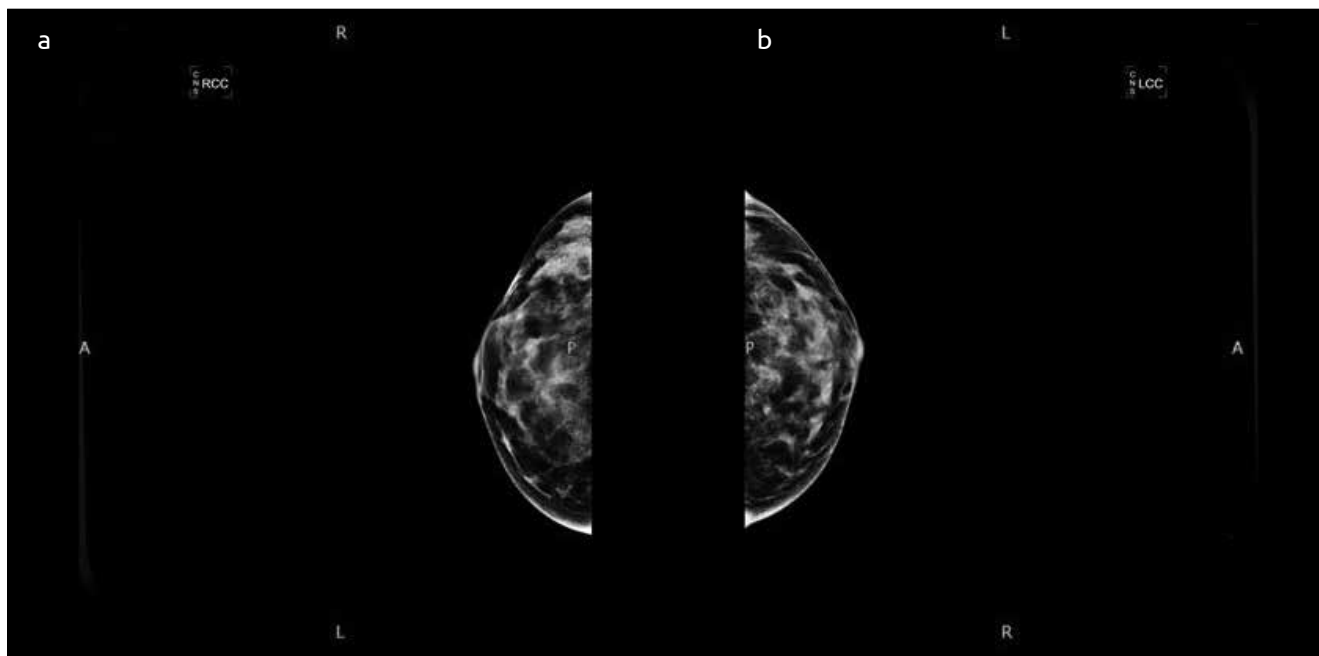
**Anahtar sözcükler:** Meme, fibroadenom, invaziv duktal karsinom

### Introduction

Fibroadenomas are benign breast lesions that consist of frequently observed biphasic, in other words stromal (connective) and epithelial, components. They are experienced at any age, and the incidence reaches a peak in the 3rd decade. They are the most frequently observed benign breast lesions in adolescent and young females (1). Although fibroadenomas are generally considered benign, there is evidence that they are associated with the increased risk of breast cancer in complex fibroadenomas, those with proliferative disease accompanying fibroadenomas, and when there is a relevant family history of the patients with fibroadenomas (2). In addition to developing within the fibroadenomas, invasive carcinoma can hold onto the fibroadenomas itself by originating from the neighboring breast tissue. The literature reports that the epithelial component can develop into a carcinoma in situ and invasive cancer (3-6). Manukyan et al. (7) have reported a case of ductal carcinoma in situ that has developed within fibroadenomas itself. Invasive carcinoma development is generally observed in females over 40 years of age (8). Although a malignant transformation in fibroadenomas is rare, the highest risk has been found in complex fibroadenomas (3). Dupont et al. have identified an increased risk (1.89 times) of cancer in complex fibroadenomas when compared to simple ones (9). It has been pointed out that the average age for carcinomas developing from fibroadenomas is during the 5th decade and for simple fibroadenoma is more than 20 years of age. Clinicians, radiologists, and pathologists have to be careful about the progression of fibroadenomas. In this case report, a ductal carcinoma in situ and invasive ductal carcinoma diagnosed as a result of biopsy in one certain patient who has been monitored with a pre-diagnosis of fibroadenoma for a long time has been presented.

### Case Presentation

A 31-year-old woman presented with a tissue in her right breast for 10 years and it rapidly grew in the last 6 months. From her case, it has been understood that she did not go through any examination and there was no known risk factor for breast cancer. During the physical examination of the patient with informed consent, a 4 cm hard tissue that caused a contraction in the skin together with arm movements



**Figure 1. a, b.** (a) A micro calcification mass with pleomorphic features (BI-RADS 5) that was widespread around 3 cm segment was observed at the outer section in right breast (CC) graph. (b) In (MLO) graph; a micro calcification mass with pleomorphic features that in the neighborhood of pectoral muscles at the upper section (BI-RADS 5). Asymmetric density increase at the level of the defined micro calcification mass

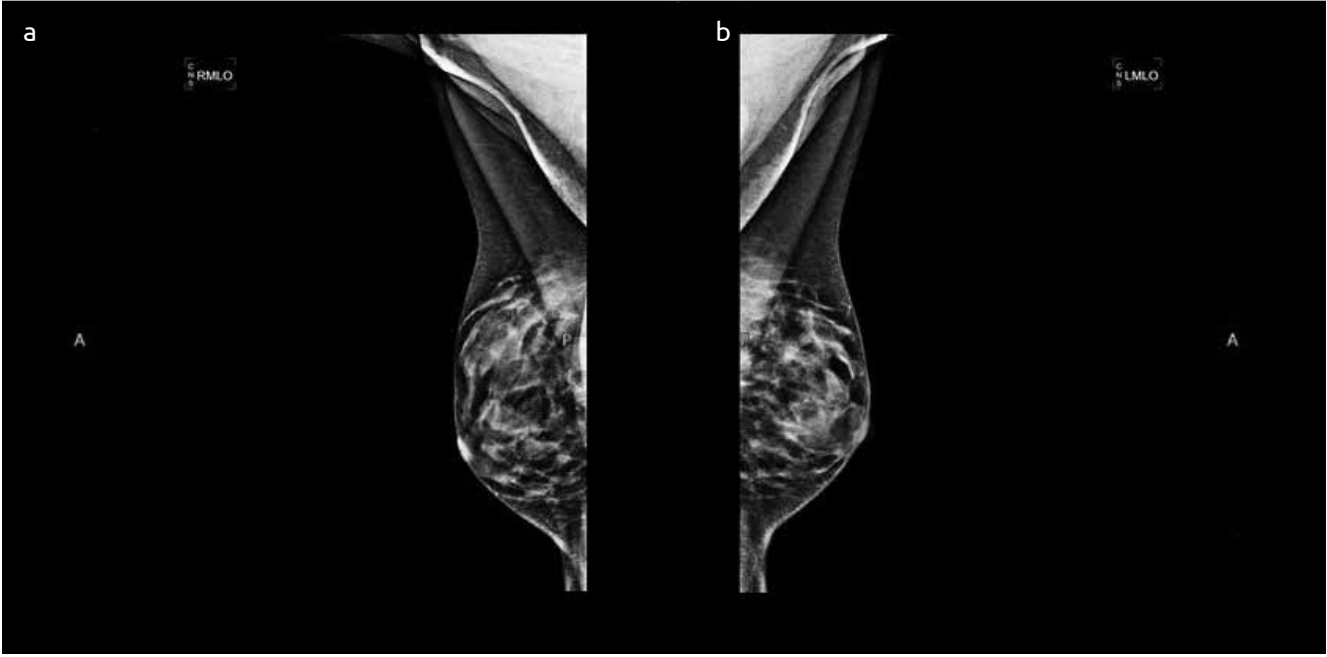
was identified in her upper outer quadrant of right breast. Clinically, a lymph node in the axilla was not identified. In her breast ultrasonography, a most probable malignant  $49 \times 18 \times 37$  mm lesion located at the 9–10 o'clock position and 2 cm away from the areola was identified. The lesion was heterogeneous, multilobular, and included a widespread pleomorphic calcification in it. Subsequently, it was decided that the patient must be evaluated through a mammography, although she was 31 years of age. In mammography, a microcalcification mass with pleomorphic features (BI-RADS 5) that was widespread around a 3 cm segment in the neighborhood of pectoral muscles at the upper section and an asymmetric density increase at the level of the defined microcalcification mass were identified at the upper outer section quadrant of in the right breast cranio-caudal (CC) graph (Figure 1a) and mediolateral-oblique (MLO) graph (Figure 1b). Because the result of core biopsy applied to the mass showed invasive carcinoma, the patient also went through breast conserving surgery protection operation and sentinel lymph node biopsy in the same session. As a result of the pathologic examination of specimen, it was diagnosed as invasive ductal carcinoma involving the invasive micropapillary areas as well. It has been thought that the tumor spread over the neighboring breast tissue developing from fibroadenoma epithelial components (Figure 2a, b). The patient was administered with four cycles of cures of the Siklofosamid–Doksorubisin (AC) protocol an adjuvant treatment, followed by radiotherapy. The treatment of the patient is still going on with Tamoksifen, LHRH analog, and Trastuzumab.

## Discussion and Conclusions

According to the definition of the World Health Organization, fibroadenomas are heterogeneous lesions with epithelial and stromal elements. They are the widespread benign lesions of the breast that evolves as simple breast masses in young women. The rate of incidence is reported to be between 7% and 13% from adolescents to individuals in their mid-20s (1). Epithelial hyperplasia is frequently observed in fi-

broadenomas, and Carter and Ark identified 0.81% atypical epithelial hyperplasia (10). Invasive or in situ cancer is very rare in fibroadenomas. The fibroadenoma-carcinoma association varies between 0.1% and 0.3% in the screened population and reaches a peak between the ages of 42 and 44 years (2, 5, 8, 11). Although it has been stated in the literature that the average age for invasive carcinoma developing from fibroadenoma is the 5<sup>th</sup> decade and those who are monitored for simple fibroadenomas is over 20 years, our case is 31 years of age and has simple fibroadenoma for around 10 years. Typically, malignant changes in fibroadenomas are found after excision incidentally (12). However, in our case, it was diagnosed as a result of mammography and core biopsy upon the growth of existing mass. Lobular or ductal invasive or noninvasive cancer can be observed together with fibroadenoma. Although around two-third of these cancers are lobular and one-third is ductal or mixed, the rates of lobular and ductal carcinoma in situ are equal (2, 6). In this study, it was identified that invasive ductal carcinoma developed from fibroadenoma epithelial components.

Cheatle and Cutler defined carcinoma developing from fibroadenoma in 1931 for the first time (13). Azzopardi et al. (14) defined carcinoma that starts in the neighboring breast tissue and then infiltrates fibroadenoma. Complex fibroadenomas and proliferative diseases neighboring fibroadenoma occur together with a slight increase in the risk of breast cancer (2, 15). The biological behavior of breast cancer associated with fibroadenoma is not different from the unrelated group (4, 5, 10). Preoperative clinical and radiological criteria are not sufficient to estimate malignant changes in fibroadenomas. Because of the heterogeneous nature of the lesions, thin needle aspiration biopsy is insufficient for a correct diagnosis. In our case, core biopsy was chosen for a preoperative diagnosis of the lesion, and the patient was advised to undergo a breast conserving surgery protecting operation after diagnosis of invasive carcinoma diagnosis. As a result of the histopathological examination, invasive ductal carcinoma that involves invasive carcinoma areas was confirmed. Therefore, it was interpreted that tumor developed from fibroadenoma epithelial components and spread over the breast tissue



**Figure 2. a, b.** (a) Invasive carcinoma is adjacent to fibro adenoma, HE, X20 (b) Ductal carcinoma in situ is restricted inside a fibroadenoma, HE, X208

(Figure 2). The diagnosis of carcinoma developing from fibroadenoma is only possible after a histopathological examination following the extraction of lesion. Although the fibroadenoma-carcinoma association is at a low rate, changes in the echogenicity and size of the mass must be assessed seriously, and excision and pathological examination must be suggested depending on the situation. Although malignant transformation in fibroadenomas is rare, patients having a family history are much more important than those without any risk factor. It is specifically necessary to be careful with patients over 35 years of age with fibroadenoma that is larger than 2 cm (16). The behavior of invasive carcinoma developing from fibroadenoma is not different from breast cancer. Therefore, treatment modalities do not differ as well (17). A clinical follow-up tracing is sufficient in many cases. However, in situations with suspicious changes in fibroadenoma that are similar to our case, it must be remembered that core biopsy should be performed. and excision when it is necessary can be obligatory when there is a doubt in clinical and radiological tracing.

**Hasta Onamı:** Yazılı hasta onamı bu çalışmaya katılan hastalar alınmıştır.

**Hakem değerlendirmesi:** Dış bağımsız.

**Yazar Katkıları:** Fikir - O.U.A., S.K.; Tasarım - O.U.A., L.S.; Denetleme - S.K., B.B.; Kaynaklar - A.i.E., L.S.; Malzemeler - L.S., A.İ.E.; Veri toplanması ve/veya işlemesi - O.U.A., S.K.; Analiz ve/veya yorum - O.U.A., B.B.; Literatür taraması - O.U.A., L.S.; Yazıyı yazan - O.U.A., A.İ.E.; Eleştirel İnceleme - O.U.A., S.K.

**Çıkar Çatışması:** Yazarlar çıkar çatışması bildirmemişlerdir.

**Finansal Destek:** Yazarlar bu çalışma için finansal destek almadıklarını beyan etmişlerdir.

**Informed Consent:** Written informed consent was obtained from patients who participated in this study.

**Author Contributions:** Concept - O.U.A., S.K.; Design - O.U.A., L.S.; Supervision - S.K., B.B.; Funding - A.i.E., L.S.; Materials - L.S., A.İ.E.; Data Collection and/or Processing - O.U.A., S.K.; Analysis and/or Interpretation - O.U.A., B.B.; Literature Review - O.U.A., L.S.; Writer - O.U.A., A.İ.E.; Critical Review - O.U.A., S.K.

**Peer-review:** Externally peer-reviewed.

**Conflict of Interest:** No conflict of interest was declared by the authors.

**Financial Disclosure:** The authors declared that this study has received no financial support.

## References

- Greenberg R, Skornick Y, Kaplan O. Management of breast fibroadenomas. *J Gen Intern Med* 1998; 13:640-645. (PMID: 9754521) [CrossRef]
- Dupont WD, Page DL, Parl FF, Vnencak-Jones CL, Plummer WD Jr, Rados MS, Schuyler PA. Long term risk of breast cancer in woman with fibroadenoma. *N Eng J Med* 1994; 331:10-15. (PMID: 8202095) [CrossRef]
- Buzanowski-Konakry K, Harrison EG Jr, Payne WS. Lobular carcinoma arising in fibroadenoma of the breast. *Cancer* 1975; 35:450-456. (PMID: 1111920) [CrossRef]
- Ozello L, Gump FE. The management of patients with carcinomas in fibroadenomatous tumours of breast. *Surg Gynecol Obstet* 1985; 160:99-104. (PMID: 2982218)
- Deschenes L, Jacob S, Fabia J, Christen A. Beware of breast fibroadenomas in middle age women. *Can J Surg* 1985; 28:372-374. (PMID: 2990650)
- Iyengar KR, Peh SC, Yip CH, Vijayanathan A. Infiltrating duct carcinoma within a fibroadenoma. *Indian J Cancer* 2009; 46:244-246. (PMID: 19574682) [CrossRef]
- Manukyan MN, Devci U, Kebudi A, Midi A, Yener N, Çelik L. Fibroadenom içine yerleşmiş duktal karsinoma insitu: Olgu sunumu. *J Breast Health* 2012; 8:204-209.
- Kuijper A, Preisler-Adams SS, Rahusen FD, Gille JJ, van der Wall E, van Diest PJ. Multiple fibroadenomas harboring carcinoma in situ in a woman with a family history of breast/ovarian cancer. *J Clin Pathol* 2002; 55:795-797. (PMID: 12354814) [CrossRef]
- Diaz NM, Palmer JO, Divitt RW. Carcinoma arising fibroadenomas of the breast: a clinicopathologic study of 105 patient. *AM J Clin Pathol* 1991; 95:614-622. (PMID: 1850948)
- Carter CL, Corle DK, Micozzi MS, Schatzkin A, Taylor PR. A prospective study of the development of breast cancer in 16,692 women with benign breast disease. *Am J Epidemiol* 1988; 128:467-477. (PMID: 3414655)

11. Pick PV, Iossifides IA. Occurrence of breast carcinoma within fibroadenoma. Arch Pathol Lab Med 1984; 108: 590-594. (PMID: 6329129)
12. Gashi-Luci LH, Limani RA, Kurshumliu FI. Invasive ductal carcinoma within fibroadenoma: a case report. Cases Journal 2009; 29; 2:174. (PMID: 19946485)
13. Cheatele GL, Cutler M. Tumours of the breast. Their pathology, symptoms, diagnosis and treatment. London: Edward Arnold and Co; 1931. p. 483-484.
14. Azzopardi JG, Ahmed A, Millis RR. Problems in Breast pathology. Major Probl Pathol 1979; 11:1-466. (PMID: 547120)
15. Kujiper A, Mommer EC, Von der Wall, Van Diest PJ. Histopathology of the fibroadenomas of the breast. Am J Clin Pathol 2001; 115:736-742. (PMID: 11345838) [\[CrossRef\]](#)
16. Abu-Rahme Z, Nseir W, Naroditzky I. Invasive ductal carcinoma within fibroadenoma and lung metastases. Int J General Med 2012; 5:19-21. (PMID: 22259257) [\[CrossRef\]](#)
17. Tiu CM, Chou YH, Chiou SY, Hsu CY, Chen SP, Chiang HR, Lai CR, Tseng LM, Wang HK, Chiou HJ. Development of a carcinoma in situ in a fibroadenoma: Color Doppler sonographic demonstration. J Ultrasound Med 2006; 25:1335-1338. (PMID: 16998108)