

# Memenin Matriks Üreten Karsinomu

## Matrix-Producing Carcinoma of the Breast

Canan Kelten<sup>1</sup>, Ceren Boyacı<sup>1</sup>, Cem Leblebici<sup>1</sup>, Didem Can Trabulus<sup>2</sup>, Umar Rıza Gursu<sup>3</sup>, Mehmet Ali Nazlı<sup>4</sup>, Erol Rüştü Bozkurt<sup>1</sup>

<sup>1</sup>İstanbul Eğitim ve Araştırma Hastanesi, Patoloji Kliniği, İstanbul, Türkiye

<sup>2</sup>İstanbul Eğitim ve Araştırma Hastanesi, Genel Cerrahi Kliniği, İstanbul, Türkiye

<sup>3</sup>İstanbul Eğitim ve Araştırma Hastanesi, Tıbbi Onkoloji Kliniği, İstanbul, Türkiye

<sup>4</sup>İstanbul Eğitim ve Araştırma Hastanesi, Radyoloji Kliniği, İstanbul, Türkiye

### ABSTRACT

Matrix-producing carcinoma (MPC) is an uncommon variant of metaplastic carcinoma. It was first described by Wargotz and Norris in 1989 as invasive breast carcinoma with direct transition to cartilaginous stroma without intervening spindle cell component. Since then, several studies, mostly in the form of case reports or case series, have been reported and the origin of tumor cell, importance of appropriate terminology for the tumor, histopathological differential diagnosis, benign breast lesions that the tumor could correlate with, and prognosis and consequently the treatment modalities have been discussed. A 43-year-old woman referred to our clinic with a lump in her left breast. Physical examination and radiological findings were consistent with malignancy. Core biopsy of the lesion was reported as “invasive breast carcinoma” and then breast-conserving surgery with sentinel lymph node dissection was performed. The case was diagnosed as MPC of the breast. The literature findings imply epithelial cell (ductal and/or myoepithelial) nature of this tumor. The prognosis is still controversial. Histopathological evaluation of sufficiently sampled surgical excision material is important to recognize and make a correct diagnosis.

**Keywords:** Breast, metaplastic, matrix-producing carcinoma

### ÖZ

Matriks üreten karsinom, metaplastik karsinomun nadir görülen alt tiplerinden biridir. İlk kez 1989 yılında Wargotz ve Norris tarafından tanımlandığında, arada işi hücreli komponent bulundurmadan kıkırdaksı stromaya direkt geçiş gösteren invaziv meme karsinomu şeklinde tarif edilmiştir. O günden bu yana, tümörün kaynaklandığı hücre tipi, doğru terminolojiyle ifade edilmesinin önemi, histopatolojik ayırıcı tanısı, ilişkili olduğu benign meme lezyonları, prognozu ve tedavi yöntemleri genelde vaka sunumu ve vaka serileri şeklindeki yayınlar ile tartışılmıştır. 43 yaşında kadın hasta kliniğe sol memede kitle şikayetiyle başvurdu. Fizik muayene ve radyolojik bulguları malignite ile uyumluydu. Tru-cut biyopsisi “invaziv meme karsinomu” olarak rapor edildi. Meme koruyucu cerrahi ve sentinel lenf nodu diseksiyonu sonucu vaka “memenin matriks üreten karsinomu” tanısı aldı. Literatürde matriks üreten karsinomun kaynaklandığı hücrenin epitelyal (duktal ve/veya myoepitelyal) karakterde olduğu ifade edilmektedir. Prognozu ise hala tartışma konusudur. Bu tümörün tanınması ve ayırıcı tanısının doğru olarak yapılması için yeterince örneklenmiş cerrahi eksizyon materyalinin histopatolojik olarak değerlendirilmesi gereklidir.

**Anahtar sözcükler:** Meme, metaplastik, matriks üreten karsinom

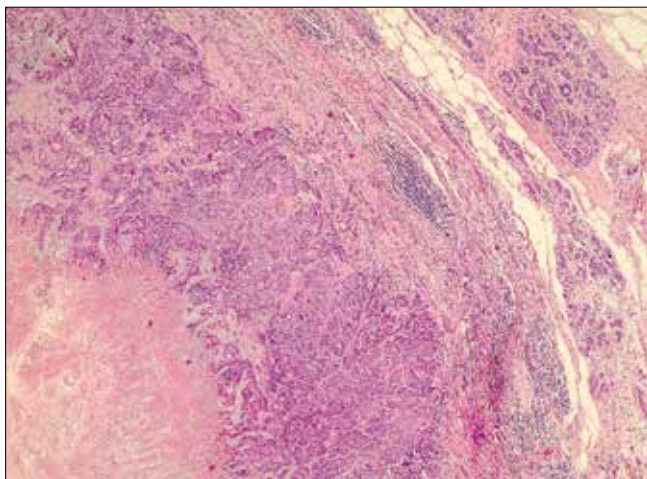
### Introduction

The World Health Organization classifies metaplastic breast carcinoma into low-grade adenosquamous carcinoma, fibromatosis-like metaplastic carcinoma, squamous cell carcinoma, spindle cell carcinoma, and carcinoma with mesenchymal differentiation (chondroid, osseous, and other types of mesenchymal differentiation) (1). Matrix-producing carcinoma (MPC) is an uncommon and specialized subtype of metaplastic carcinoma that constitutes less than %1 of all breast carcinomas (2). It was first described by Wargotz and Norris in 1989 as invasive carcinoma with abrupt transition to chondromyxoid matrix without an intervening spindle cell sarcomatoid component (3). We present a case of MPC and highlight the importance of recognizing this unusual tumor to enable accurate prognosis and specific therapy.

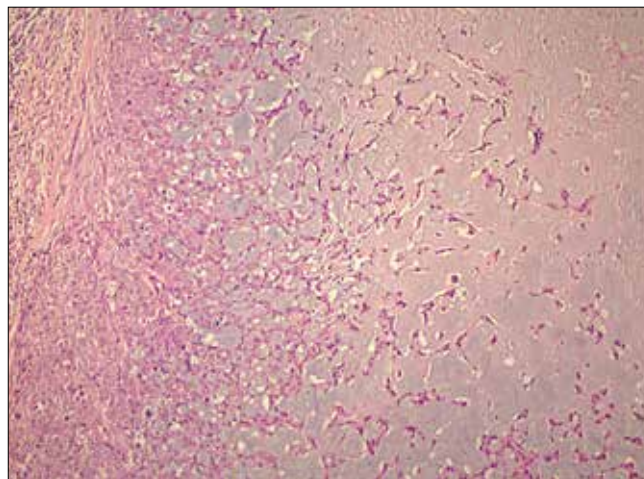
### Case Presentation

A 43-year-old woman referred to our clinic with a lump in her left breast. Both physical examination and radiological findings were consistent with malignancy. Core biopsy of the lesion indicated “invasive breast carcinoma,” and breast-conserving surgery and sentinel lymph node dissection were performed. Grossly, the tumor was solid, gray–white in color, and 3.3×2.5 cm in size, with a lobulated contour. Its

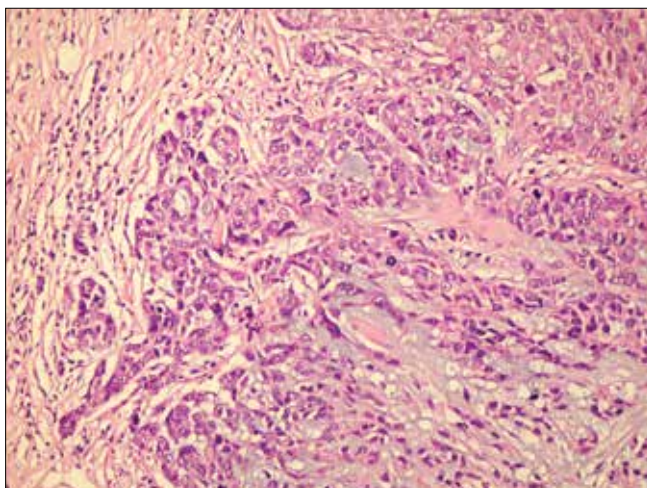
*This study was presented at the 26<sup>th</sup> European Congress of Pathology, 30 August- 3 September 2014, ExCeL, London, United Kingdom.  
Bu çalışma 26. Avrupa Patoloji Kongresi'nde sunulmuştur, 30 Ağustos-3 Eylül 2014, ExCeL, Londra, İngiltere.*



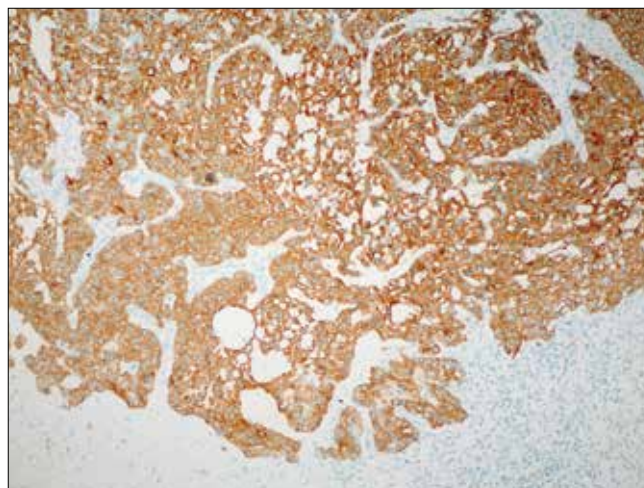
**Figure 1.** Tumor shows necrosis in the center and cellularity at the periphery (H&E,  $\times 40$ )



**Figure 2.** Tumor nests gradually diminish through chondromyxoid areas (H&E,  $\times 100$ )



**Figure 3.** Tumor cells show high nuclear grade features (H&E,  $\times 200$ )



**Figure 4.** Cyokeratin 14 immunopositivity in tumor cells (DAB-Mayer's hematoxylin counterstain,  $\times 100$ )

center was looser than the periphery. Microscopically, the periphery of the tumor consisted of solid sheets of high-grade carcinoma cells. Tumor nests gradually diminished through the central chondromyxoid matrix (Figure 1-3). No intervening spindle cell component was present. Sentinel lymph node procedure was performed and no tumor metastasis was determined. Immunostaining was negative for estrogen receptor, progesterone receptor, and Her2/neu (triple negative). Other immunohistochemical staining results were as follow; cyokeratin 14 (+) (Figure 4), p63 focally (+), cyokeratin 5/6 (-), and smooth muscle actin (-). The Ki-67 proliferation index was 60%. The case was diagnosed as MPC of the breast due to its morphological features. The patient underwent adjuvant fluorouracil (5-FU; Koçak Farma, İstanbul, Turkey), epirubicin (pirucin; Eczacıbaşı Baxter, İstanbul, Turkey) and cyclophosphamide (Endoxan; Saba, İstanbul, Turkey) (FEC) chemotherapy and radiotherapy. No recurrence was observed after 22 months follow-up.

### Discussion and Conclusion

Matrix-producing carcinoma (MPC) is a rare and specialized type of metaplastic carcinoma. To diagnose as MPC, histopathological examination of the surgical excision material is required. Grossly, most of these tumors have been described as nodular and well-circumscribed,

similar to other triple-negative breast carcinomas. Microscopically, moderate- to high-grade carcinomatous cells aggregate at the periphery of the tumor in the form of sheets, nests, tubules, and cords. These cells show a gradual transition from carcinomatous areas to chondromyxoid matrix without an intervening spindle cell sarcomatoid component toward the central acellular zone. As a result, microscopically, a more basophilic appearance is seen at the tumor periphery because of tumor cellularity and more lilac color is seen through the center of the tumor because of hypocellularity as well as the presence of chondromyxoid matrix.

Sasaki et al. (4) described that the morphological features of MPC of the breast are different than those observed in invasive ductal carcinoma of the breast with a large central acellular AREA. In MPC, the margin of the tumor is well-defined and the tumor cells show expansile invasion to the surrounding tissue. However, the margin of the tumor is somewhat irregular because of the presence of an infiltrative pattern into the surrounding fat tissue in invasive ductal carcinoma with a large central acellular area. While carcinoma cells in MPC gradually become sparse and less cohesive toward the central region, the border between the peripheral cellular and central acellular area is almost sharp in the other. In addition, the intercellular matrix produced by MPC is myxoid and basophilic on hematoxylin and eosin

(H&E) staining because of the accumulation of cartilaginous matrix. In contrast, the central acellular area of invasive carcinoma is eosinophilic/hyalinized depending on tissue infarction (4).

The histopathological diagnosis of MPC requires exclusion of the morphological features of phyllodes tumor or metastatic sarcoma because these lesions could be misdiagnosed as primary breast sarcoma such as osteosarcoma or chondrosarcoma. Sufficient sampling for evidence of conventional ductal carcinoma is required before defining a lesion as primary breast sarcoma.

There are some reports that demonstrate a connection between MPC and some benign lesions of the breast. Hayes et al. reported three MPC cases in the background of primary pleomorphic adenoma of the breast and showed a direct transition from benign areas in pleomorphic adenoma to obvious carcinoma areas with myxoid matrix. On the other hand, in the study by Shui R et al. (5), a relation between microglandular adenosis and MPC was described in 2 of 13 cases.

There is a wide spectrum of description regarding matrix-producing tumors of the breast in the literature, with both “carcinoma” and “sarcoma” terminology, which can lead to confusion during treatment. The existing literature support that the malignant cells in MPC originate from epithelial cells of the ductal or myoepithelial type (6, 7). Rakha et al. (6) indicated that the majority of matrix-producing breast tumors were associated with epithelial cell features and therefore they should be treated with breast carcinoma-specific therapy instead of sarcoma-specific therapy. Kusafuka et al. (7) demonstrated the epithelial cell origin of MPC by immunohistochemical and ultrastructural examinations in their case series. The authors showed diffuse and/or focal immunohistochemical positivity for a wide panel of cytokeratins (AE1–AE3, 34βE12, CAM5.2, CK19, CK7, and CK5/6) and epithelial membrane antigen (EMA) in both carcinomatous and metaplastic cells. In addition, partial immunopositivity for p63, a myoepithelial marker, was considered myoepithelial cell-like differentiation. They also demonstrated desmosome-like intercellular junctional structures, tonofilaments, and actin filaments in carcinoma cells ultrastructurally (7). Because the majority of MPC cases reported in the literature showed triple-negative features [estrogen receptor (-), progesterone receptor (-), and Her2/neu (-)] and a basal-like phenotype (cytokeratin 5/6, cytokeratin 14, and epidermal growth factor receptor positivity) (5, 6, 8, 9), systemic chemotherapy following surgery is the treatment of choice at present (6).

The clinical behavior of MPC is controversial. There are some reports that show no prognostic difference between MPC and invasive breast carcinoma at the same stage (3, 6). In the study of Wargotz and Norris, the clinical outcome of MPC was reported to be similar to that of a matched control group of patients with invasive ductal carcinoma (3). Similarly, Rakha et al. (6) showed prognosis comparable to that of grade- and hormone receptor-matched ductal carcinoma and slightly better than other that of subtypes of metaplastic breast carcinoma in their large multi-institutional series of malignant matrix-producing breast tumors. However, Downs-Kelly et al. (8) reported aggressive behavior in terms of increased locoregional and distant tumor recurrence rates compared with invasive ductal carcinoma.

In conclusion, MPC is an uncommon variant of metaplastic breast carcinoma and shows negative immunostaining for estrogen receptor, progesterone receptor, and Her2/neu (triple negative). The exact diagnosis requires histopathological examination of surgical excision material. Sufficient sampling is important for differential diagnosis.

Systemic chemotherapy following surgery is the treatment of choice at present.

**Informed Consent:** Written informed consent was obtained from patient who participated in this study.

**Peer-review:** Externally peer-reviewed.

**Author Contributions:** Concept - C.K., C.B.; Design - C.B., D.C.T., M.A.N.; Supervision - E.R.B., M.A.N.; Funding - E.R.B., D.C.T.; Data Collection and/or Processing - C.K., C.L., D.C.T., U.R.G.; Analysis and/or Interpretation - C.K., C.L., U.R.G.; Literature Review - C.B., U.R.G.; Writer - C.K., C.B., M.A.N.; Critical Review - E.R.B., C.L.

**Conflict of Interest:** No conflict of interest was declared by the authors.

**Financial Disclosure:** The authors declared that this study has received no financial support.

**Hasta Onamı:** Yazılı hasta onamı bu çalışmaya katılan hastadan alınmıştır.

**Hakem değerlendirmesi:** Dış bağımsız.

**Yazar Katkıları:** Fikir - C.K., C.B.; Tasarım - C.B., D.C.T., M.A.N.; Denetleme - E.R.B., M.A.N.; Kaynaklar - E.R.B., D.C.T.; Veri toplanması ve/veya işlemesi - C.K., C.L., D.C.T., U.R.G.; Analiz ve/veya yorum - C.K., C.L., U.R.G.; Literatür taraması - C.B., U.R.G.; Yazıyı yazan - C.K., C.B., M.A.N.; Eleştirel İnceleme - E.R.B., C.L.

**Çıkar Çatışması:** Yazarlar çıkar çatışması bildirmemişlerdir.

**Finansal Destek:** Yazarlar bu çalışma için finansal destek almadıklarını beyan etmişlerdir.

## References

- Lakhani SR, Ellis IO, Schnitt SJ, Tan PH, van de Vijver MJ. WHO Classification of Tumors of the Breast. International Agency for Research on Cancer, 2012.
- Yamaguchi R, Horii R, Maeda I, Suga S, Makita M, Iwase T, Oguchi M, Ito Y, Akiyama F. Clinicopathologic study of 53 metaplastic breast carcinomas: their elements and prognostic implications. *Hum Pathol* 2010; 41:679-685. (PMID: 20153509) [[CrossRef](#)]
- Wargotz ES and Norris HJ. Metaplastic carcinomas of the breast. III. Carcinosarcoma. *Cancer* 1989; 64:1490-1499. (PMID: 2776108) [[CrossRef](#)]
- Sasaki Y, Tsuda H, Ueda S, Asakawa H, Seki K, Murata T, Kuriki K, Tamai S, Matsubara O. Histological differences between invasive ductal carcinoma with a large central acellular zone and matrix-producing carcinoma of the breast. *Pathol Int* 2009; 59:390-394. (PMID: 19490469) [[CrossRef](#)]
- Shui R, Bi R, Cheng Y, Lu H, Wang J, Yang W. Matrix-producing carcinoma of the breast in the Chinese population: a clinicopathological study of 13 cases. *Pathol Int* 2011; 61:415-422. (PMID: 21707845) [[CrossRef](#)]
- Rakha EA, Tan PH, Shabaan A, Tse GM, Esteller FC, van Deurzen CH, Purnell D, Stotter A, Chan T, Yamaguchi R, Dodwell D, Jager A, Soler MT, Juneinah E, Plaza ML, Hodi Z, McCulloch T, Lee AH, Ellis IO. Do primary mammary osteosarcoma and chondrosarcoma exist? A review of a large multi-institutional series of malignant matrix-producing breast tumors. *Breast* 2013; 22:13-18. (PMID: 23084962) [[CrossRef](#)]
- Kusafuka K, Muramatsu K, Kasami M, Kuriki K, Hirobe K, Hayashi I, Watanabe H, Hiraki Y, Shukunami C, Mochizuki T, Kameya T. Cartilaginous features in matrix-producing carcinoma of the breast: four cases report with histochemical and immunohistochemical analysis of matrix molecules. *Mod Pathol* 2008; 21:1282-1292. (PMID: 18622387) [[CrossRef](#)]
- Downs-Kelly E, Nayeemuddin KM, Albarracín C, Wu Y, Hunt KK, Gilcrease MZ. Matrix-producing carcinoma of the breast: an aggressive subtype of metaplastic carcinoma. *Am J Surg Pathol* 2009; 33:534-541. (PMID: 19047898) [[CrossRef](#)]
- Gwin K, Wheeler DT, Bossuyt V, Tavassoli FA. Breast carcinoma with chondroid differentiation: a clinicopathologic study of 21 triple negative (ER-, PR-, Her2/neu-) cases. *Int J Surg Pathol* 2010; 18:27-35. (PMID: 19282292) [[CrossRef](#)]