



# Atypical Cavernous Hemangioma of the Breast Associated with Multiple Soft Tissue Phleboliths

## Memede Atipik Kavernöz Hemanjiom ve Eşlik Eden Multiple Yumuşak Doku Flebolitleri

Neslin Şahin<sup>1</sup>, Levent Çanakalelioğlu<sup>2</sup>, Aynur Solak<sup>1</sup>, Berhan Genç<sup>1</sup>, Oya Nermin Sivrikoz<sup>3</sup>, Serkan Gür<sup>1</sup>

<sup>1</sup>Department of Radiology, Faculty of Medicine, Şifa University, İzmir, Turkey

<sup>2</sup>Department of General Surgery, Faculty of Medicine, Şifa University, İzmir, Turkey

<sup>3</sup>Department of Pathology, Faculty of Medicine, Şifa University, İzmir, Turkey

### ABSTRACT

Vascular tumors of the breast are rare but potentially diagnostically challenging entities. The majority are angiosarcomas and hemangiomas. Most symptomatic intraparenchymal vascular tumors prove to be angiosarcomas. Hemangiomas are well-defined benign tumors without specific radiological findings. They are usually located superficially and identified incidentally. In this report, we describe a case of a menopausal woman with an atypical cavernous hemangioma of the left breast which was highly suggestive of malignancy (BIRADS category 5) studied with mammography, ultrasound, and computed tomography (CT). Breast hemangioma was associated with multiple soft tissue phleboliths including ipsilateral neck, axilla, shoulder, chest wall, and proximal upper extremity and a few phleboliths on the right side of the neck.

**Key words:** Breast, cavernous hemangioma, atypical, mammography

### ÖZET

Meme vasküler tümörleri nadir görülmele birlikte, tanıda zorluk yaratabilirler. Çoğunluğunu anjiosarkomlar ve hemanjiomlar oluşturur. İntrapanenkimal yerleşimli semptomatik vasküler tümörlerin genellikle anjiosarkomlara ait olduğu gösterilmiştir. Hemanjiomlar ise; spesifik radyolojik bulguları olmayan iyi sınırlı benign tümörlerdir. Genellikle yüzeysel yerleşimlidir ve tesadüfen saptanırlar. Bu yazıda sol memede yerleşimli yüksek olasılıkla malign (BIRADS kategori 5) olduğu düşünülen, atipik kavernöz hemanjiom saptanan, mamografi, ultrasonografi ve bilgisayarlı tomografi (BT) incelemeleri yapılan menopozda kadın hastayı sunuyoruz. Meme hemanjiomuna, lezyon ile aynı taraf boyun, aksilla, skapuler bölge, hemitoraks ve proksimal üst ekstremitede multipl sayıda ve boyun sağ tarafında birkaç adet yumuşak doku flebolitleri eşlik etmekteydi.

**Anahtar sözcükler:** Meme, kavernöz hemanjiom, atipik, mamografi

### Introduction

Vascular tumors are rarely seen in the breast (1-3). The most common vascular tumors are hemangiomas and angiosarcomas (2). A search of the surgical pathology records of approximately 10,000 breast biopsies evaluated by Glazebrook et al. (4) yielded 18 cases of benign vascular tumors (15 hemangiomas and three angiolipomas) and two malignant angiosarcomas. The majority of clinically symptomatic intraparenchymal vascular tumors are angiosarcomas (1). Hemangiomas of the breast are well-defined benign tumors which are usually located superficially (4). They are frequently identified incidentally during histopathological examination of surgical specimens (3). Here, we describe a case of a postmenopausal woman with an intraparenchymal atypical cavernous hemangioma of the breast which was highly suggestive of malignancy (Breast imaging reporting and data system - BIRADS category 5) and associated with multiple soft tissue phleboliths.

### Case Report

A 68-year-old woman presented with a palpable mass in her left breast. The mass was not painful, and not associated with skin changes. There was no family history of breast cancer. On physical examination, there was a 2 cm poorly defined firm mass in the upper medial quadrant which was moderately fixed to the surrounding tissue. Mammography revealed a 2x1.5 cm irregular mass with spiculated margins highly suggestive of malignancy (BIRADS category 5) (Figure 1a, b). On ultrasound, the lesion was heterogeneous and hypochoic with ill-defined margins (Figure 1c). A preoperative chest radiograph showed multiple phleboliths superimposed on the ipsilateral neck, axilla, scapular region, hemithorax, and proximal upper extremity, and a few phleboliths on the right side of the neck (Figure 2a). Subsequently, chest computed tomography (CT) was performed and demonstrated multiple phleboliths including the subcutaneous and deep tissues of the left cervical region, axilla, shoulder, thorax wall, and proximal upper extremity, and a few phleboliths in the subcutaneous tissues of the right side of the neck (Figure 2b). There was no evidence of metastatic disease. Ultrasonography (US) guided core needle biopsy was performed, but failed to provide a definitive diagnosis. The patient underwent surgical excision. The final pathologic diagnosis

*This case was presented as a poster at the 32<sup>nd</sup> National Radiology Congress, 28 October-02 November 2011, Antalya, Turkey.*

*Bu olgu, 32. Ulusal Radyoloji Kongresi'nde poster olarak sunulmuştur, 28 Ekim-02 Kasım 2011, Antalya, Türkiye.*

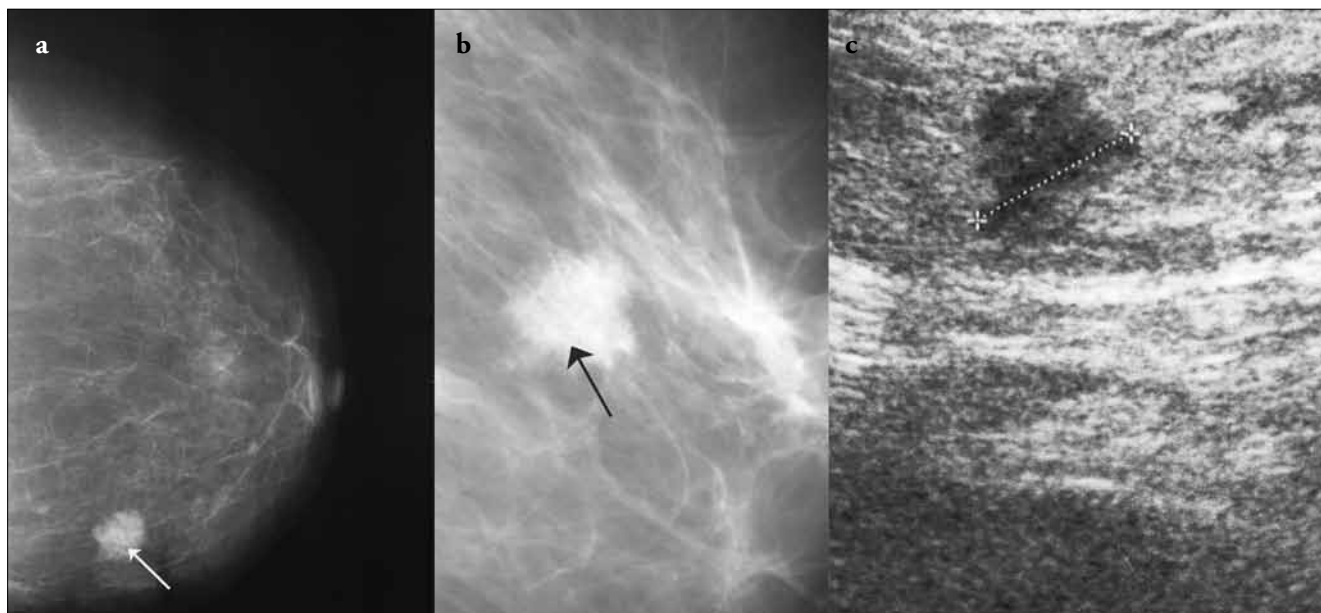
#### Address for Correspondence/Yazışma Adresi:

Neslin Şahin, Department of Radiology, Faculty of Medicine, Şifa University, İzmir, Turkey

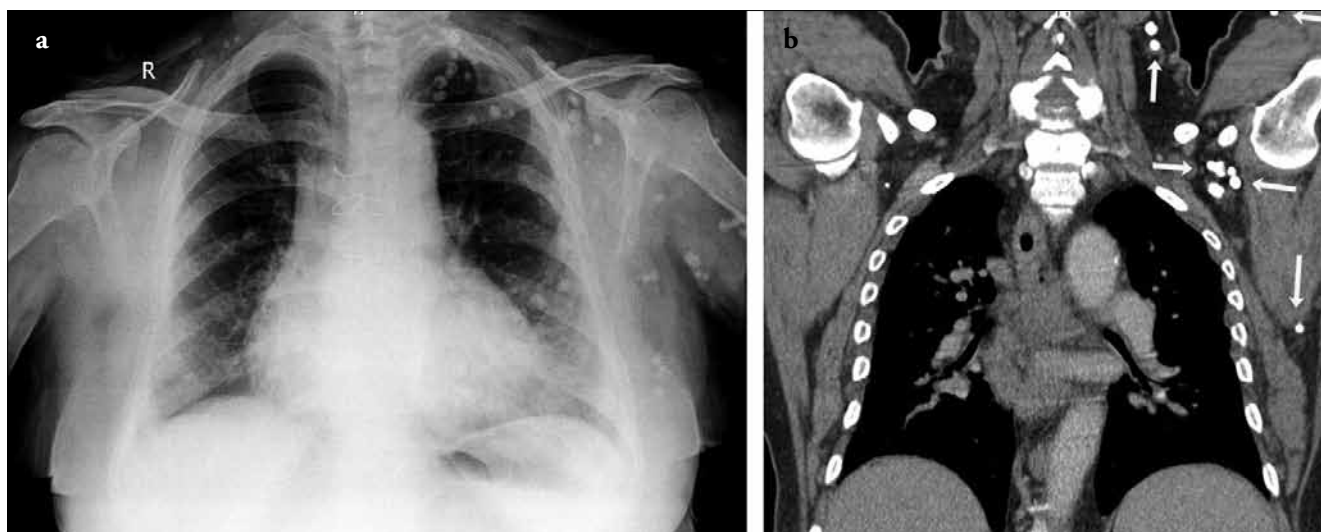
Phone / Tel.: +90 232 343 44 45 e-mail / e-posta: neslinshn@gmail.com

Received / Geliş Tarihi: 12.09.2012

Accepted / Kabul Tarihi: 27.10.2012



**Figure 1.** Craniocaudal (a) and magnified mediolateral oblique (b) mammogram shows 2x1.5 cm irregular mass with spiculated margins and a punctate microcalcification (arrows) highly suggestive of malignancy (BIRADS category 5). Breast sonogram (c) shows poorly defined heterogeneous hypoechoic lesion



**Figure 2.** Chest radiograph (a) demonstrates multiple coarse calcifications indicative of phleboliths superimposed on the ipsilateral neck, axilla, scapular region, hemithorax, and proximal upper extremity, and a few phleboliths on the right side of the neck. Chest CT (b) shows multiple soft tissue phleboliths (arrows)

was cavernous type hemangioma. Microscopic examination of hemangioma showed thin-walled dilated vessels congested with red blood cells and lined with endothelial cells (Figure 3).

### Discussion and Conclusions

The most common vascular tumors of the breast are hemangiomas and angiosarcomas (2). Hemangiomas are frequently identified incidentally during histopathological examination of surgical specimens. They have been found in 1.2% (7/555) of mastectomies performed for breast carcinoma (3) and 11% of 210 consecutive forensic autopsies (5).

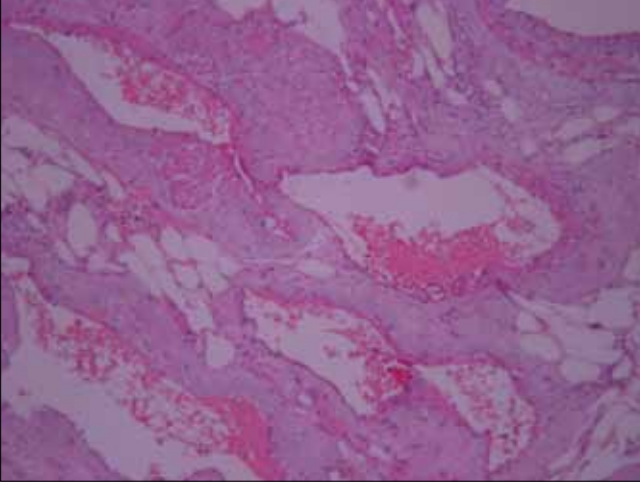
Most clinically and mammographically apparent intraparenchymal vascular tumors prove to be malignant angiosarcomas. Angiosarcomas are typically larger than 3 cm, whereas most hemangiomas are smaller

than 2 cm at diagnosis (6). In our case, the hemangioma was large enough to be clinically palpable.

The common two histological types are capillary and cavernous hemangiomas. Cavernous hemangioma is the most common type in the breast with large vascular channels. Grossly, most hemangiomas have well-circumscribed borders, but microscopically the vascular channels may extend into the surrounding breast parenchyma (2).

The clinical and radiological diagnosis of breast hemangioma is difficult. Although different imaging techniques play a complementary role in the differential diagnosis, the imaging features are often nonspecific. So, histopathological examination of the lesion is required (7).

Mammographically, hemangiomas appear as well-defined, oval or lobular masses with nonspecific findings, probably most of them are



**Figure 3.** Photomicrograph of a specimen shows dilated vessels congested with red blood cells and lined with endothelial cells (Hematoxylin-Eosin, x200)

categorized as BIRADS category 3 and cannot be distinguished from fibroadenomas or cysts. It is reported that hemangiomas may have fine punctate or phlebolith type coarse calcifications. However, Mesurolle et al. (8) have identified round calcifications suggestive of phleboliths in only one of the 16 hemangiomas. In our patient, the mass had one fine punctate microcalcification presumably indicative of phlebolith, but appeared to be not well-defined. Superficial location is characteristic of the hemangiomas. Therefore, a tangential view is necessary to see the superficial nature of the mass. Hemangiomas may be rarely intraparenchymal as in our case (4, 8).

Although hemangiomas may have different sonographic features, they usually present as well-circumscribed, solid, ovoid masses consistent with benign lesions similar to mammographic findings. Some of them may display microlobulated and indistinct margins especially in hyperechoic lesions. One third of them have hyperechoic echotexture. Because most of the hemangiomas have a heterogeneous isoechoic, mildly hypoechoic or hyperechoic echotexture relative to the surrounding adipose tissue, they can be less conspicuous on sonography than they are clinically or mammographically (4, 8).

In the series by Mesurolle et al. (8) 16 breast hemangiomas were similar to the classic appearance of a hemangioma noted in previous case reports. However, there have been few documented cases of breast hemangiomas with suspicious clinical and/or radiological features in the literature. Although hemangiomas are even more rare in men, masses measuring up to 60 mm in male breasts have been described (9, 10). One article reports a hemangioma with unilateral whole breast involvement without associated calcifications (11). There is a case report of a hemangioma with an increase in size that is supposed to be related to hormone-replacement therapy (12). A case report of a calcified breast mass leading to mammographic suspicion of ductal carcinoma in situ (DCIS) has been recorded (7). Also, a breast hemangioma clinically mimicking an inflammatory carcinoma has been described (13). The literature includes a case of a hemangioma with spiculated margins interpreted as highly suggestive of malignancy on mammography (BIRADS category 5) as in our case (14). It was reported that histologically, vessels encased by fibrous stroma extended from the margins of the lesion accounting for the radiological appearance. However, atypical breast hemangioma mimicking malignancy associated with multiple soft tissue phleboliths has not been published, to our knowledge.

If the diagnosis is confirmed as an hemangioma on biopsy, complete excision of the mass is recommended to exclude the possibility of an underlying malignant lesion and to avoid progression to angiosarcoma. However, image guided core needle biopsy appears reliable enough to rule out any malignant or premalignant component and to avoid a surgical excision in the absence of pathologic-radiologic discordance (8). It is possible that atypical hemangiomas may progress to angiosarcoma, but this relationship remains to be demonstrated (5, 8, 15). Although hemangiomas are found at relatively high rates in the autopsies (11%), the incidence of angiosarcomas are so low that malignant transformation must be uncommon.

In conclusion, hemangiomas of the breast are uncommon. Most of them display oval or lobular shape with well-defined or microlobulated margins. If a superficial breast mass having a typical mammographic and sonographic features of hemangioma is diagnosed as hemangioma without atypia by biopsy, it can be followed up with mammography without excision, but hemangiomas with atypical imaging findings mimicking malignancy, as in our case, should be noted. In addition, it should be considered that breast hemangiomas may be associated with other vascular lesions presenting as multiple phleboliths in the subcutaneous and deep tissues. Familiarity with these features may help diagnosis and management of these anomalies.

**Conflict of Interest:** No conflict of interest was declared by the authors.

**Peer-review:** Externally peer-reviewed.

**Informed Consent:** Written informed consent was obtained from patients who participated in this case.

**Author Contributions:** Concept - N.Ş., L.Ç.; Design - N.Ş., A.S.; Supervision - N.Ş., L.Ç., A.S., B.G., O.S., S.G.; Funding - N.Ş., L.Ç., A.S., O.S.; Materials - N.Ş., L.Ç., A.S., O.S.; Data Collection and/or Processing - N.Ş., L.Ç., A.S., O.S.; Analysis and/or Interpretation - N.Ş., L.Ç., A.S., B.G., O.S., S.G.; Literature Review - N.Ş., A.S.; Writer - N.Ş., L.Ç., A.S., B.G.; Critical Review - N.Ş., L.Ç., A.S., B.G., O.S., S.G.; Other - N.Ş., L.Ç., A.S., B.G., O.S., S.G.

**Financial Disclosure:** The authors declared that this study has received no financial support.

**Çıkar Çatışması:** Yazarlar çıkar çatışması bildirmemişlerdir.

**Hakem değerlendirmesi:** Dış bağımsız.

**Hasta Onamı:** Yazılı hasta onamı bu olguya katılan hastadan alınmıştır.

**Yazar Katkıları:** Fikir - N.Ş., L.Ç.; Tasarım - N.Ş., A.S.; Denetleme - N.Ş., L.Ç., A.S., B.G., O.S., S.G.; Kaynaklar - N.Ş., L.Ç., A.S., O.S.; Malzemeler - N.Ş., L.Ç., A.S., O.S.; Veri toplanması ve/veya işlemesi - N.Ş., L.Ç., A.S., O.S.; Analiz ve/veya yorum - N.Ş., L.Ç., A.S., B.G., O.S., S.G.; Literatür taraması - N.Ş., A.S.; Yazıyı yazan - N.Ş., L.Ç., A.S., B.G.; Eleştirel İnceleme - N.Ş., L.Ç., A.S., B.G., O.S., S.G.; Diğer - N.Ş., L.Ç., A.S., B.G., O.S., S.G.

**Finansal Destek:** Yazarlar bu çalışma için finansal destek almadıklarını beyan etmişlerdir.

## References

1. Brodie C, Provenzano E. Vascular proliferations of the breast. *Histopathology* 2008; 52:30-44. (PMID: 18171415) [CrossRef]

2. Rosen PP. Rosen's breast pathology. 2nd ed. New York: Lippincott Williams & Wilkins, 2001:789-797.
3. Rosen PP, Ridolfi RL. The perilobular hemangioma. A benign microscopic vascular lesion of the breast. *Am J Clin Pathol* 1977; 68:21-23. (PMID: 868802)
4. Glazebrook KN, Morton MJ, Reynolds C. Vascular tumors of the breast: mammographic, sonographic, and MRI appearances. *AJR Am J Roentgenol* 2005; 184:331-338. (PMID: 15615997) [\[CrossRef\]](#)
5. Lesueur GC, Brown RW, Bhathal PS. Incidence of perilobular hemangioma in the female breast. *Arch Pathol Lab Med* 1983; 107:308-310. (PMID: 6687795)
6. Jozefczyk MA, Rosen PP. Vascular tumors of the breast. II. Perilobular hemangiomas and hemangiomas. *Am J Surg Pathol* 1985; 9:491-503. (PMID: 4091183) [\[CrossRef\]](#)
7. Shi AA, Georgian-Smith D, Cornell LD, Rafferty EA, Staffa M, Hughes K, Kopans DB. Radiological reasoning: male breast mass with calcifications. *AJR Am J Roentgenol* 2005; 185:205-210. (PMID: 16304041) [\[CrossRef\]](#)
8. Mesurolle B, Sygal V, Lalonde L, Lisbona A, Dufresne MP, Gagnon JH, Kao E. Sonographic and mammographic appearances of breast hemangioma. *AJR Am J Roentgenol* 2008; 191:17-22. (PMID: 18562711) [\[CrossRef\]](#)
9. Kinoshita S, Kyoda S, Tsuboi K, Son K, Usuba T, Nakasato Y, Kashiwagi H, Komine K, Takeishi M, Sato S, Takeyama H, Uchida K, Yamazaki Y, Sakamoto G. Huge cavernous hemangioma arising in a male breast. *Breast Cancer* 2005; 12: 231-233. (PMID: 16110295) [\[CrossRef\]](#)
10. Kondi-Paftis A, Kairi-Vassilatou E, Grapsa D, Kalkounou I, Vassilikostas G, Psychogios I. A large benign vascular neoplasm of the male breast. A case report and review of the literature. *Eur J Gynaecol Oncol* 2005; 26: 454-456. (PMID: 16122203)
11. Kim SM, Kim HH, Shin HJ, Gong G, Ahn SH. Cavernous haemangioma of the breast. *Br J Radiol* 2006; 79:177-180. (PMID: 17065282) [\[CrossRef\]](#)
12. Mesurolle B, Wexler M, Halwani F, Aldis A, Veksler A, Kao E. Cavernous hemangioma of the breast: mammographic and sonographic findings and follow-up in a patient receiving hormone-replacement therapy. *J Clin Ultrasound* 2003; 31:430-436. (PMID: 14528442) [\[CrossRef\]](#)
13. Gopal SV, Nayak P, Dharanipragada K, Krishnamachari S. Breast hemangioma simulating an inflammatory carcinoma. *Breast J* 2005; 11:498-499. (PMID: 16297112) [\[CrossRef\]](#)
14. Mariscal A, Casas JD, Balliu E, Castellà E. Breast hemangioma mimicking carcinoma. *Breast* 2002; 11:357-358. (PMID: 14965696) [\[CrossRef\]](#)
15. Rupec M, Batzenschlager I. Pseudoangiosarcoma (Masson). A histological study. *Z Hautkr* 1981; 56:1360-1363. (PMID: 7197851)