

# Assessment of Bone Conduction Thresholds After Surgical Treatment in Patients with Labyrinthine Fistula

Müzeyyen Yıldırım Baylan<sup>1</sup> , Ümit Yılmaz<sup>1</sup> , Zeki Akkuş<sup>2</sup> , İsmail Topçu<sup>1</sup> 

<sup>1</sup>Department of Otorhinolaryngology, Dicle University School of Medicine, Diyarbakır, Turkey

<sup>2</sup>Department of Biostatistics, Dicle University School of Medicine, Diyarbakır, Turkey

Original Investigation 

## Abstract

**Objective:** This study aimed to analyze the bone conduction thresholds before and after surgery in chronic otitis media patients with cholesteatoma who had labyrinthine fistula and whose cholesteatoma matrix had been completely cleaned.

**Methods:** The study was performed between 2013 to 2017 with 23 chronic otitis media patients who had labyrinthine fistula with cholesteatoma and who were operated at the Department of Otorhinolaryngology of Dicle University School of Medicine. Patients were assessed by anamnesis and examination and when necessary, by temporal computerized tomography and diffusion magnetic resonance imaging. Bone conduction thresholds at frequencies of 500, 1000, 2000, and 4000 Hz were determined by audiometric examination and they were compared before and after surgery.

**Results:** Of the 23 patients, 12 were female and 11 were male; their age range was 10–55 (26.04±14.13)

years. In the post-operative period, it was possible to conduct audiological follow-up on 20 patients. In these follow-ups, 16 patients showed no change in bone conduction thresholds, two patients showed worsening, and two showed improvement. When pre- and post-operative bone conduction thresholds at each frequency were compared separately, no significant difference was found ( $p=0.937$ ). No statistically significant difference was found between the pre- and post-operative means at the four frequencies ( $p=0.712$ ).

**Conclusion:** In this study, we found that to reduce complications relating to cholesteatoma, it might be necessary to completely remove the matrix especially in the case of type 1 and 2 labyrinthine fistulas.

**Keywords:** Cholesteatoma, labyrinthine fistula, mastoidectomy, hearing loss



**ORCID IDs of the authors:**  
 M.Y.B. 0000-0002-7537-1733;  
 Ü.Y. 0000-0003-1227-153X;  
 Z.A. 0000-0002-6161-3666;  
 İ.T. 0000-0002-6192-1546.

**Cite this article as:** Yıldırım Baylan M, Yılmaz Ü, Akkuş Z, Topçu İ. Assessment of Bone Conduction Thresholds After Surgical Treatment in Patients with Labyrinthine Fistula. Turk Arch Otorhinolaryngol 2018; 56(2): 89-94.

## Introduction

Labyrinthine fistula is formed by the erosion of the bony labyrinth. Erosion of the cochlea, vestibule or semicircular canals is regarded as labyrinthine fistula and often occurs because of cholesteatoma (1, 2). The treatment of chronic otitis media with cholesteatoma is entirely surgical, but when labyrinthine fistula is present, removing the cholesteatoma matrix on the fistula carries the risk of sensorineural hearing loss (1, 2).

A number of studies have discussed the surgical approach on patients with labyrinthine fistula. However, there is still no consensus on the surgical method to be used. Some surgeons advocate that the matrix should not be removed and recommend the

open-cavity technique because of the risk of hearing loss in patients with labyrinthine fistula (1, 2). However, we have realized on the basis of our clinical experience that cholesteatoma recurs in patients in whom the matrix remains and problems relating to cholesteatoma such as ear discharge, dizziness, and hearing loss continue. Therefore, now the cholesteatoma matrix is cleaned as much as possible in our patients and the mastoid cavity obliteration technique is preferred.

This study aimed to analyze the bone conduction thresholds before and after surgery in chronic otitis media patients with cholesteatoma who had labyrinthine fistula and whose cholesteatoma matrix had been completely cleaned.

This study was presented at the 5<sup>th</sup> National Otolaryngology and Neurology Congress, May 4-7 2017, Antalya, Turkey.

**Corresponding Author:**  
 Müzeyyen Yıldırım Baylan; muzeyyenildirm@hotmail.com

**Received Date:** 19.01.2018  
**Accepted Date:** 21.03.2018

© Copyright 2018 by Official Journal of the Turkish Society of Otorhinolaryngology and Head and Neck Surgery Available online at [www.turkarchotolaryngol.net](http://www.turkarchotolaryngol.net)

DOI: 10.5152/tao.2018.3238

## Methods

The study was performed between 2013 to 2017 with 23 chronic otitis media patients who had labyrinthine fistula with cholesteatoma and who were operated at the Department of Otorhinolaryngology of Dicle University School of Medicine. This study was approved by the Ethics Committee of Dicle University School of Medicine, and written informed consent was obtained from all the patients.

Cholesteatoma stage assessment was conducted on the basis of European Academy of Otolology and Neurotology and Japanese Otological Society (EAONO/JOS) (3). The type of fistula was determined according to Dornhoffer and Milewski classification (4) (Table 1). In addition, the locations of the fistulas were recorded as lateral semicircular, posterior, superior semicircular canal, round window, or cochlea-vestibule. Patients were assessed by anamnesis and examination and when necessary, by computerized tomography and diffusion magnetic resonance imaging. Audiometric examination was performed on all patients. Operations were performed under general anesthesia by a single surgeon. During surgery, the cholesteatoma matrix on the fistula was completely cleaned in the final stage, and the fistula was covered with autograft materials such as temporal muscle fascia, bone pate, and cartilage.

Table 1. Dornhoffer and Milewski classification (4)

Type of fistula	
Type 1	Erosion of the bony labyrinth but intact endosteum
Type 2	Erosion of the endosteum but membranous labyrinth is intact (2a: intact perilymphatic space, 2b: erosion of the perilymphatic space)
Type 3	Erosion of the membranous labyrinthine space

Table 2. Type and number of labyrinthine fistulas\*

Type of fistula	Number of fistulas (n)	Locations of fistulas	Other concomitant complications
**Type 1	5	LSC(4/5) SSC(1/5)	None
**Type 2a	12	LSC(10/12) SSC(2/12) Cochlea basal turn- vestibule (1/12) Round window(1/12)	Cerebellar abscess (n=1) Sigmoid sinus thrombosis (n=1), Hydrocephalus (n=1)
Type 2b	4	LSC(4/4)	Facial paralysis (n=1)
**Type 3	3	LSC, Cochlea/vestibule (1/3), LSC, PSC, SSC, Cochlea/vestibule (1/3) LSC and PSC(1/3)	Facial paralysis (n=2)

LSC: Lateral semicircular canal; SSC: Superior semicircular canal; PSC: Posterior semicircular canal

\*Information from 23 patients was used

\*\*There was more than one type of the fistula in the same patient

Bone conduction thresholds at frequencies of 500, 1000, 2000, and 4000 Hz were determined by audiometric examination. Audiometric examinations were performed before and three months after the surgery in the same department using the same equipment (Clinical Audiometer AC33 Interacoustics A/S, Assens, Denmark). Before and after the surgery, frequency-specific bone conduction thresholds were recorded on audiograms. In the audiological measurements, bone conduction means were taken at frequencies of 500, 1000, 2000, and 4000 Hz. The data were compared statistically. Also, the post-operative bone conduction mean (the mean of the threshold at four frequencies) showing a reduction of more than 10 dB compared with the pre-operative value was classified as better, an increase of more than 10 dB as worse, and a change of less than 10 dB as unchanged.

## Statistical analysis

The Shapiro-Wilk test was used to analyze the distribution of the results. The non-parametric Wilcoxon test was used to compare the results because the distribution of the pre- and post-operative bone conduction was not normal. Mean±standard deviation was used to analyze the age and sex distribution. All statistical analyses were performed using the SPSS software (IBM Corp. Released 2011. IBM SPSS Statistics for Windows, Version 20.0. Armonk, NY: IBM Corp.)

## Results

The study included 23 patients with labyrinthine fistula because they had chronic otitis media with cholesteatoma. Overall, 12 patients were female and 11 were male, and their age range was 10–55 (26.06±14.03) years.

According to EAONO/JOS (1), all of the patients had acquired cholesteatoma, 19 at stage 3 and three at stage 4. In three of the patients with stage 3 cholesteatoma, there was also the presence of House-Brackmann stage 4 and 5 facial paral-

ysis. In the three patients with stage 4 cholesteatoma, there was cerebellar abscess, sigmoid sinus thrombosis, and hydrocephalus. Labyrinthine fistulas were found in a single area in 17 patients and in more than one area in five patients. Fistulas were present in the lateral semicircular canals of 19 patients, in the superior semicircular canals of four patients, in the posterior semicircular canals of two patients, in the cochlea-vestibule in three patients, and in the round window of one patient. When the types of the fistulas were assessed according to the Dornhoffer and Milewski classification (4), type 3 was found in three patients, type 2b in four patients, type 1 in five patients, and type 2a in the remaining 12 patients (Table 2). In the post-operative period, it was possible to conduct audiological follow-up on 20 patients. In these follow-up examinations, 16 patients showed no change in bone conduction thresholds, two patients showed worsening, and two showed improvement. There were multiple type 3 labyrinthine fistulas located in the cochlea and vestibule in two patients who had post-operative severe hearing loss. Additionally, these patients had facial nerve paralysis. The two patients who showed im-

provement had only lateral semicircular canal fistulas classified as type 1 and type 2a (Table 3).

When pre- and post-operative bone conduction thresholds at each frequency were compared separately, no significant difference was found ( $p=0.937$ ) (Table 4). In addition, no statistically significant difference was found between pre- and post-operative means at the four frequencies ( $p=0.712$ ).

Dizziness was found post-operatively in three patients. In one of these three patients with dizziness, there was no improvement despite medical treatment; therefore, re-exploration was performed. The fistula area was again obliterated with bone pate and fascia, and a complete improvement of the symptoms was seen. The dizziness of the other two patients disappeared within 5–7 days of medical treatment.

Canal wall-down tympanomastoidectomy was performed on 20 of the 22 patients and cul-de-sac surgery with partial petrosectomy was performed in one patient. Abscess drainage was performed on the patient with cerebellar abscess by simultaneous

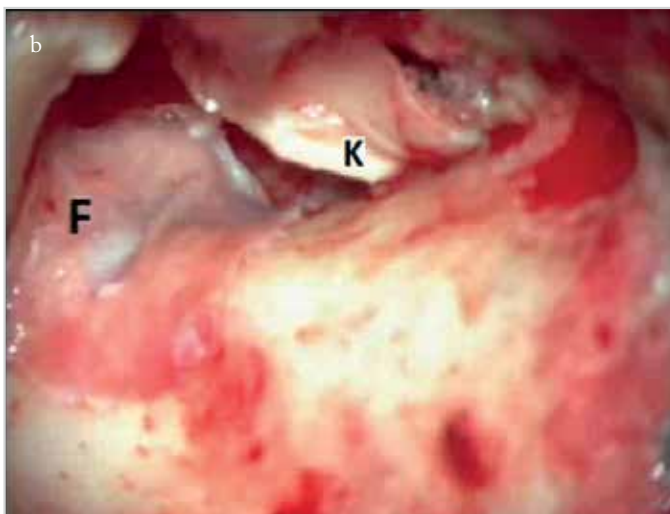
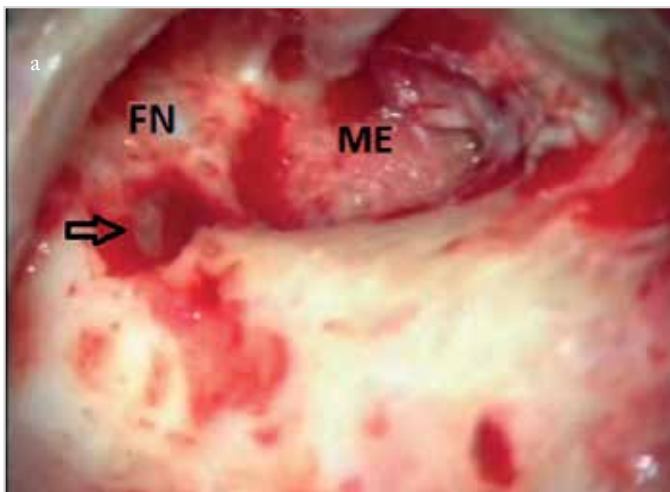


Figure 1. a, b. Right ear, canal wall-down mastoidectomy. Type 2a fistula in lateral semicircular canal (a), fistula covered with fascia (b) arrow: fistula area, F: fascia, FN: facial nerve tympanic segment, ME: middle ear, K: Cartilage

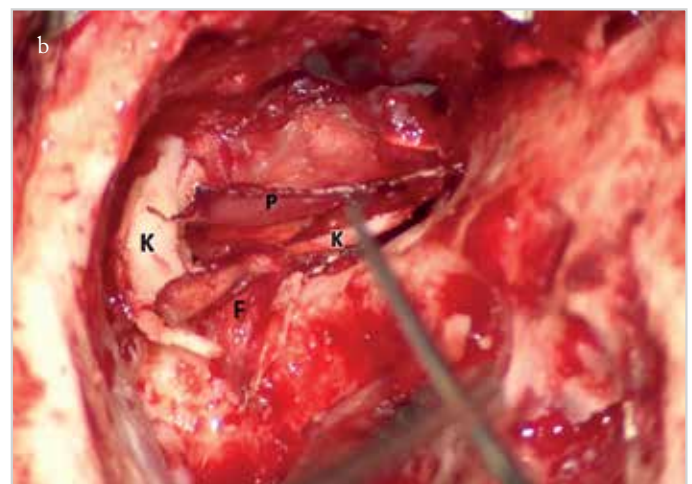
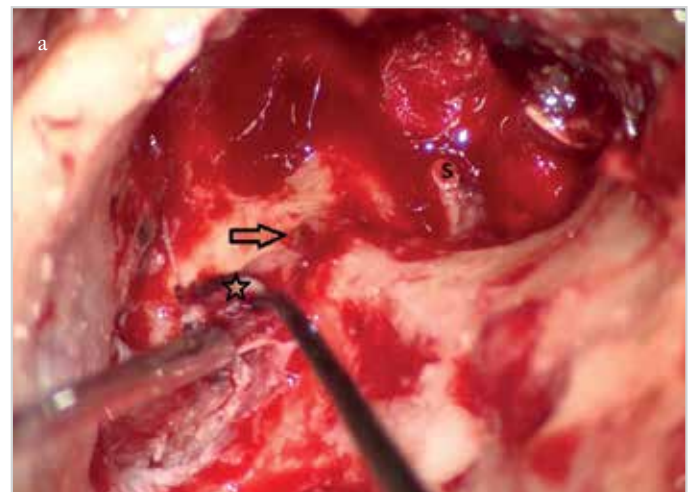


Figure 2. a, b. Right ear, canal wall-down mastoidectomy. Type 2b fistula in lateral semicircular canal (a), fistula covered with autogenous graft materials (b) Arrow: fistula area; star: cholesteatoma matrix; F: fascia; K: Cartilage; P: perichondrium; S: stapes

**Table 3.** Post-operative status of the bone conduction according to the fistula type\*

	Type 1	Type 2a	Type 2b	Type 3
Unchanged (n=16**)	4	11	3	
Better (n=2)	1		1	
Worse (n=2)				2

\*Data from the 20 patients on whom audiometric analysis could be performed post-operatively were used.

\*\*There were type 1 and 2 fistulas in two patients

**Table 4.** Post-operative level of bone conduction

	500 Hz	1000 Hz	2000 Hz	4000 Hz	Median of BC threshold
Pre-operative BC (dB) threshold	10	10	15	15	13
Post-operative BC (dB) threshold	15	10	15	20	14.5
p	0.437	0.757	0.813	0.877	0.712

BC: bone conduction

brain surgery. Decompression was performed without making an incision on the nerve sheath in the three patients with facial paralysis.

Patient follow-up periods were between 4 and 40 months. It was possible to follow up 20 of the 23 patients in the post-operative period. Disease eradication was achieved in all of these 20 patients. In 19 patients, the tympanic membrane was found to be intact and the mastoid cavity small and dry. The patient on whom petrosectomy was performed was monitored for the first post-operative year by diffusion MRI, and it was observed that no relapse took place. Complications got better without sequelae. In the three patients with facial paralysis, improvement was achieved with House–Brackmann stage 1.

## Discussion

Cholesteatoma is a cause of chronic otitis media, the treatment of which is performed entirely surgically. In chronic otitis with cholesteatoma, labyrinthine fistula is a possible complication, and 90% of labyrinthine fistulas form as a result of cholesteatoma (5, 6). If the fistula is left untreated, vertigo, sensorineural hearing loss, purulent labyrinthitis or meningitis may occur. However, hearing loss may occur as a result of surgical removal. For this reason, the methods used in surgical removal must be discussed. Some surgeons recommend the complete removal of the cholesteatoma matrix from the area of the fistula (7, 8), whereas others recommend that the matrix be left (1, 2). The risk of hearing loss of 11%-23% during the removal of the matrix had also been reported (7, 9). However, Stephenson and Saliba (10) have reported that if the matrix is not removed, there is a greater risk of complication because the disease will spread and labyrinthitis will develop. Thus, it has been reported that the incomplete removal of the cholesteatoma matrix in patients with chronic otitis media with cholesteatoma carries a greater risk of hearing loss. Our clinical practice is to completely remove the cholesteatoma matrix in labyrinthine fistulas (Figure 1, 2).

In this study, total hearing loss occurred post-operatively in the two patients who had type 3 and cochlear fistulas. In the literature, it has been determined that the worst prognoses are for cochlear fistulas and the best are for fistulas of the lateral semicircular canal (10). Similarly, in our cases, hearing loss occurred in patients with fistulas of the cochlea, both of whom had type 3 fistulas and facial nerve paralysis. Apart from this, even though the matrix was completely removed in patients with type 1 and type 2a fistulas in the semicircular canals, we found that there was no deterioration of bone conduction thresholds. Our study showed that both the location and type of the fistula may be prognostic factors for the post-operative level of bone conduction hearing.

We observed that in a large proportion of the patients in whom the matrix was removed, a deterioration of bone conduction hearing was not seen, especially in type 1 and 2 fistulas, and that the deterioration of hearing loss was stopped by the removal of the destructive effect of the disease and those complications were prevented. We observed an increase in the bone conduction thresholds in two patients who had type 1 and 2a fistulas in the lateral semicircular canal. Moreover, in short-term follow-ups (4 months-4 years), cholesteatoma and related complications were completely prevented. With this approach, a middle ear and mastoid that were dry and closed to the outside were obtained.

It is very important to be able to protect the membranous labyrinth during the removal of the cholesteatoma matrix. During surgery, the removal of the cholesteatoma matrix in the area of the fistula should be left until the rest of the operation is completed and it should be quickly covered. In this way, hearing loss related to the fistula and the possibility of labyrinthitis and meningitis will be avoided. In a study with 17 patients, Jang et al. (11) assessed the hearing loss according to the size of the fistula and reported that even with large fistulas, there was no deterioration in the bone conduction and that there was an im-

provement in four of their patients. In the present study, we did not classify fistulas by size.

Meyer et al. (12) emphasized that hearing neither changed nor improved in 76% of patients in whom the matrix was completely removed. However, in 15% of cases, they reported worsening, and in 9.7%, there was a total hearing loss. In our study, total hearing loss occurred in two patients with multiple fistulas in the cochlea and vestibule. We achieved improvement in two patients, and in 16 patients, there was no deterioration in bone conduction. In patients with cochlear fistula and type 3 fistula, severe hearing loss occurred. However, there were few type 3 patients; for this reason, we were unable to compare for fistula types within the groups. Still, we speculate that hearing loss may occur particularly with type 3 and cochlear fistulas. For this reason, the possibility of complications in removing the matrix in patients with cochlear and type 3 fistulas must be borne in mind, and the decision on removing the cholesteatoma matrix must be taken in consultation with the patient before surgery because of the concern regarding possible risks. The surgeon should also take into consideration the situation of the contralateral ear and own experience while choosing the surgical methods. Surgical strategy has been influenced by advancements in pre-operative evaluation, post-operative imaging options, and the potential for cochlear implant salvage surgery in the case of profound hearing loss (13). In this study, the hearing threshold of the contralateral ear of two patients with type 3 fistula in which hearing loss resulted was within normal limits, and both patients had previously been operated on and had relapsed. For that reason, the risks were discussed with patients before the surgery. They were operated on only after being informed that the cholesteatoma had to be completely cleaned to prevent a recurrence and that the risk of hearing loss was high. The cholesteatoma matrix was completely cleaned, and during the follow-up, no recurrence was seen in accordance with the expectations of the patients, but hearing loss occurred.

## Conclusion

To reduce complications relating to cholesteatoma, it is necessary to completely remove the matrix in the case of labyrinthine fistulas and in particular type 1 and type 2 fistulas. However, great care must also be taken with type 3 and cochlear bone fistulas, and it must be borne in mind that there may be a greater likelihood of hearing loss compared with other areas. Although the risk of fistula-related sensorineural hearing loss especially with type 1 and 2 fistulas is very low with careful surgery, bone conduction hearing loss may occur with type 3 and cochlea fistulas when the cholesteatoma matrix is cleaned. In such cases, the method of surgery must be decided by taking into consideration the condition of the contralateral ear and surgeon's experience and consulted with the patient for possible risks.

**Ethics Committee Approval:** Ethics committee approval was received for this study from the Ethics Committee of Dicle University School of Medicine (12.06.2015-290).

**Informed Consent:** Written informed consent was obtained from patients who participated in this study.

**Peer-review:** Externally peer-reviewed.

**Author Contributions:** Concept - M.Y.B., Ü.Y., Z.A., İ.T.; Design - M.Y.B., Ü.Y., Z.A., İ.T.; Supervision - M.Y.B., Ü.Y., Z.A., İ.T.; Resource - M.Y.B., İ.T.; Materials - M.Y.B., Ü.Y., İ.T.; Data Collection and/or Processing - Ü.Y., İ.T.; Analysis and/or Interpretation - M.Y.B., Z.A.; Literature Search - M.Y.B., Ü.Y., İ.T.; Writing - M.Y.B.; Critical Reviews - Ü.Y., Z.A., İ.T.

**Acknowledgements:** The authors thank to Dicle University Scientific Research Department (DUBAP) for their assistance in the data collection.

**Conflict of Interest:** The authors have no conflicts of interest to declare.

**Financial Disclosure:** The authors declared that this study has received no financial support.

## References

1. Sanna M, Zini C, Gamoletti R, Taibah AK, Russo A, Scandellari R. Closed versus open technique in the management of labyrinthitis fistulae. *Am J Otol* 1988; 9: 470-5. [\[CrossRef\]](#)
2. Law KP, Smyth GDL, Kerr AG. Fistula of the labyrinth treated by staged combined approach tympanoplasty. *J Laryngol Otol* 1975; 89: 471-8. [\[CrossRef\]](#)
3. Yung M, Tono T, Olszewska E, Yamamoto Y, Sudhoff H, Sakagami S, et al. EAONO/JOS joint consensus statements on the definitions, classification and staging of middle ear cholesteatoma. *J Int Adv Otol* 2017; 13: 1-8. [\[CrossRef\]](#)
4. Dornhoffer JL, Milewski C. Management of the open labyrinth. *Otolaryngol Head Neck Surg* 1995; 112: 410-4. [\[CrossRef\]](#)
5. Copeland BJ, Buchman CA. Management of labyrinthine fistulae in chronic ear surgery. *Am J Otolaryngol* 2003; 24: 51-60. [\[CrossRef\]](#)
6. Quaranta N, Liuzzi C, Zizzi S, Dicorato A, Quaranta A. Surgical treatment of labyrinthine fistula in cholesteatoma surgery. *Otolaryngol Head Neck Surg* 2009; 140: 406-11. [\[CrossRef\]](#)
7. Bo Y, Yang Y, Xiaodong C, Xi W, Keyong T, Yu Z, et al. A retrospective study on post-operative hearing of middle ear cholesteatoma patients with labyrinthine fistula. *Acta Otolaryngol* 2016; 136: 8-11. [\[CrossRef\]](#)
8. Ueda Y, Kurita T, Matsuda Y, Ito S, Nakashima T. Surgical treatment of labyrinthine fistula in patients with cholesteatoma. *J Laryngol Otol Suppl* 2009; 31: 64-7. [\[CrossRef\]](#)
9. Albu S, Amadori M, Babighian G. Predictors of hearing preservation in the management of labyrinthine fistulas positioned on the semicircular canals. *Ann Otol Rhinol Laryngol* 2013; 122: 529-34. [\[CrossRef\]](#)
10. Stephenson M, Saliba I. Prognostic indicators of hearing after complete resection of cholesteatoma causing a labyrinthine fistula. *Eur Arch Oto-rhinolaryngol* 2011; 268: 1705-11. [\[CrossRef\]](#)
11. Jang CH, Jo SY, Cho YB. Matrix removal of labyrinthine fistulae by non-suction technique with intraoperative dexamethasone injection. *Acta Oto-Laryngologica* 2013; 133: 910-5. [\[CrossRef\]](#)

12. Meyer A, Bouchetemble P, Costentin B, Dehesdin D, Lerosey Y, Marie JP. Lateral semicircular canal fistula in cholesteatoma: diagnosis and management. *Eur Arch Otorhinolaryngol* 2016; 273: 2055-63. [[CrossRef](#)]
13. Carlson ML, Latuska RF, Pelosi S, Wanna GB, Bennett ML, Rivas A, et al. Evolving considerations in the surgical management of cholesteatoma in the only hearing ear. *Otol Neurotol* 2014; 35: 84-90. [[CrossRef](#)]