

Posttraumatic Intramuscular Hemangioma Arising from Scalene Muscles in Supraclavicular Region

Supraklaviküler Bölgede Skalen Kastan Kaynaklanan Posttravmatik İntramusküler Hemanjiom

Case Report
Olgu Sunumu

Erkan Öztürk, Eren Yılmaz, İlker Erdinç Öztürk, Beldan Polat, Kadir Serkan Orhan
Department of Otorhinolaryngology, İstanbul University İstanbul School of Medicine, İstanbul, Turkey

Abstract

Intramuscular hemangiomas (IMH) account for <1% of all hemangiomas and are rarely located in the head and neck region. The most common site of origin in the head and neck is the masseter muscle, whereas IMH originating from the scalene muscles are rarely seen. Surgical excision of intramuscular hemangioma is considered the main treatment modality. Here we present

the case of a male patient aged 17 with IMH that occurred after blunt trauma in the supraclavicular region, fed by the thyrocervical and costocervical trunks, and with an arteriovenous shunt.

Keywords: Intramuscular hemangioma, scalene muscle, traumatic

Öz

İntramusküler hemanjiomlar (İMİH) tüm hemanjiomların %1'inden daha azını oluşturur ve nadiren baş-boyun bölgesinde görülür. İMİH baş boyun bölgesinde en sık masseter kası içerisinde görülür ve skalen kaslardan kaynaklanan hemanjiomlar nadirdir. İntramusküler hemanjiomun ana tedavi modalitesi cerrahi eksizyondur. Bu çalışmada, supraklaviküler bölgede

künt travma sonrası oluşmuş tiroservikal ve kostoservikal trunkustan beslenen ve arteriovenöz şant (AV) içeren intramusküler hemanjiomlu 17 yaşında bir erkek hasta sunduk.

Anahtar Kelimeler: İntramusküler hemanjiom, skalen kas, travmatik



This study was presented at the 38th Turkish National Congress of Otorhinolaryngology Head and Neck Surgery, 26-30 October 2016, Antalya, Turkey.

Bu çalışma, 38. Türk Ulusal Kulak Burun Boğaz ve Baş Boyun Cerrahisi Kongresi'nde sunulmuştur, 26-30 Ekim 2016, Antalya, Türkiye.

Address for Correspondence/Yazışma Adresi:
Erkan Öztürk
E-mail: drerkanozturk@hotmail.com

Received Date/Geliş Tarihi: 01.12.2016

Accepted Date/Kabul Tarihi: 28.01.2017

Available Online Date

Çevrimiçi Yayın Tarihi: 22.05.2017

© Copyright 2017 by Official Journal of the Turkish Society of Otorhinolaryngology and Head and Neck Surgery Available online at www.turkarchotorhinolaryngol.org

© Telif Hakkı 2017 Türk Kulak Burun Boğaz ve Baş Boyun Cerrahisi Derneği Makale metnine www.turkarchotorhinolaryngol.org web sayfasından ulaşılabilir.

DOI: 10.5152/tao.2017.2138

Introduction

Intramuscular hemangioma (IMH) is a rare benign vascular tumor that accounts for <1% of all hemangiomas (1). Although IMHs are generally located in the truncus and extremities, the most common site of origin is the masseter muscle in the head and neck region (2). They rarely originate in the trapezius, sternocleidomastoid, and temporal muscles. In English literature, there are only five reported cases of intramuscular hemangioma that were all originating from scalene muscles (3-6).

In this report, we present a male patient aged 17 with a gradually growing mass and IMH that occurred within the left scalene muscles after blunt trauma and underwent surgical excision with a preliminary diagnosis of arteriovenous fistula.

Case Presentation

A male patient aged 17 presented with a mass on the left side of the neck. On taking patient's history, we found that a gradually growing mass appeared on his neck after he suffered a blunt trauma 2 years previously. Physical examination showed a 6-7 cm swelling in the left supraclavicular region (Figure 1).

The mass was painless, mobile, and nonpulsatile on palpation but a thrill was heard in the mass. Ultrasonography (USG) demonstrated a hypervascularized and hyperechogenic solid tumor that was adherent to the adjacent muscle tissue. Magnetic resonance imaging (MRI) revealed a well-defined and lobulated mass in the scalene muscles with a hypointense signal void on T1-weighted images (Figure 2a) and a hyperintense signal void on

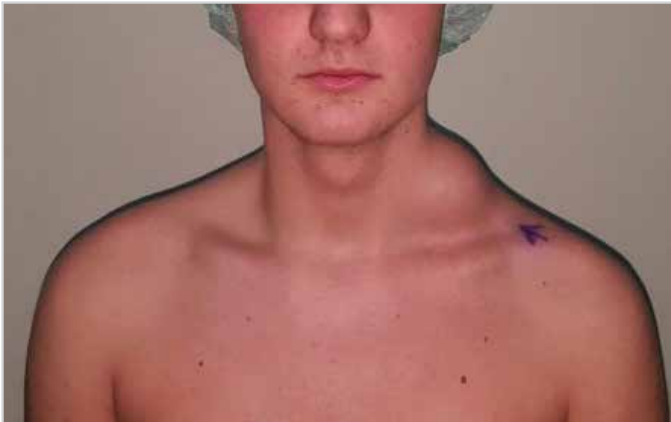

Figure 1. Physical examination revealed a 6-7 cm semisolid mass in the left posterior cervical triangle

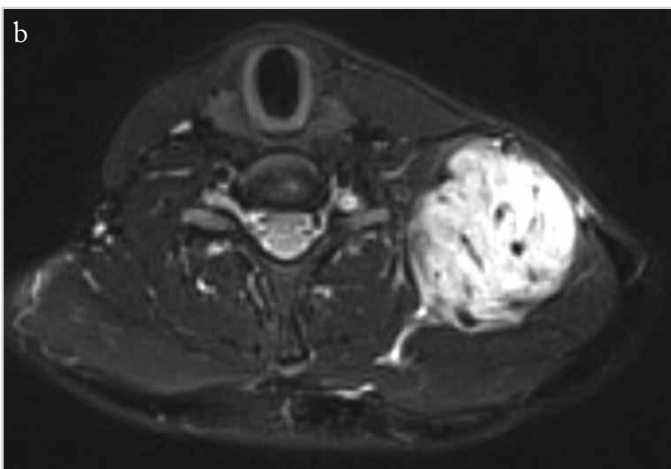
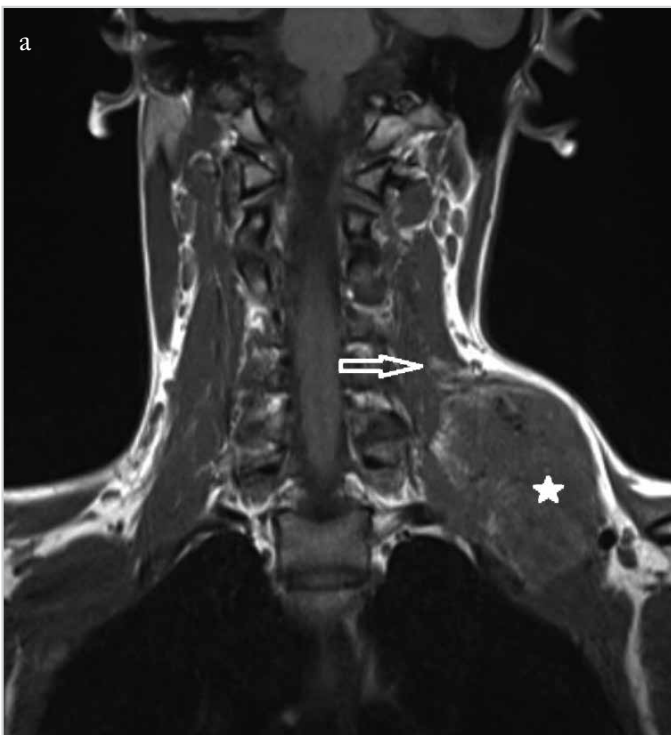

Figure 2. a, b. Magnetic resonance imaging showed a lobulated tumor in the left scalene muscles, which has (a) hypointense signal voiding on T1 coronal section (star indicates the tumor and arrow indicates the left scalene muscles) and (b) increased signal intensity on T2 axial section

T2-weighted images (Figure 2b), and it showed extensive enhancement on gadolinium-enhanced T1-weighted images.

Also, the tumor was in close proximity with the left subclavian artery and pressed upon the brachial plexus. Based on the USG and MRI findings, the tumor was considered a vascular pathology, and thus, digital subtraction angiography (DSA) was performed via the right femoral artery. DSA identified a hypervascularized solid tumor fed by the thyrocervical and costocervical trunks, including a high-flow arteriovenous (AV) shunt (Figure 3a, b).

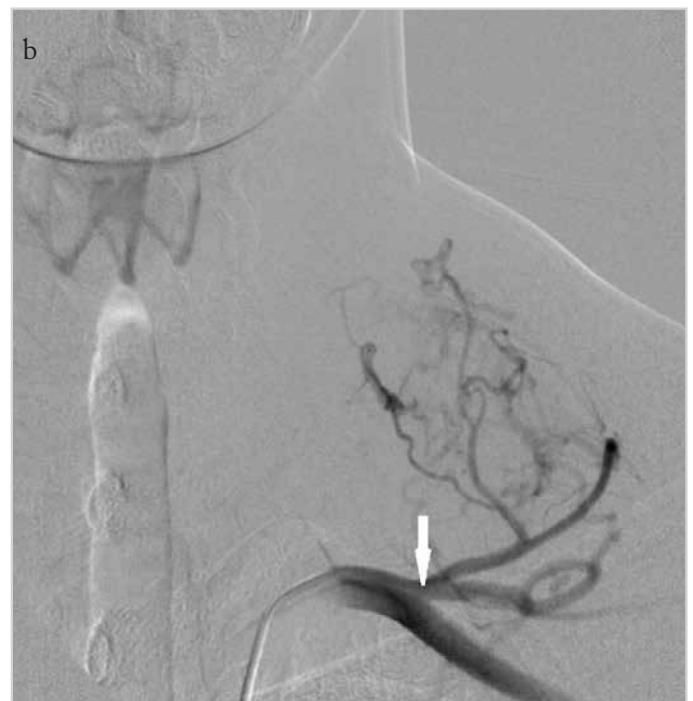
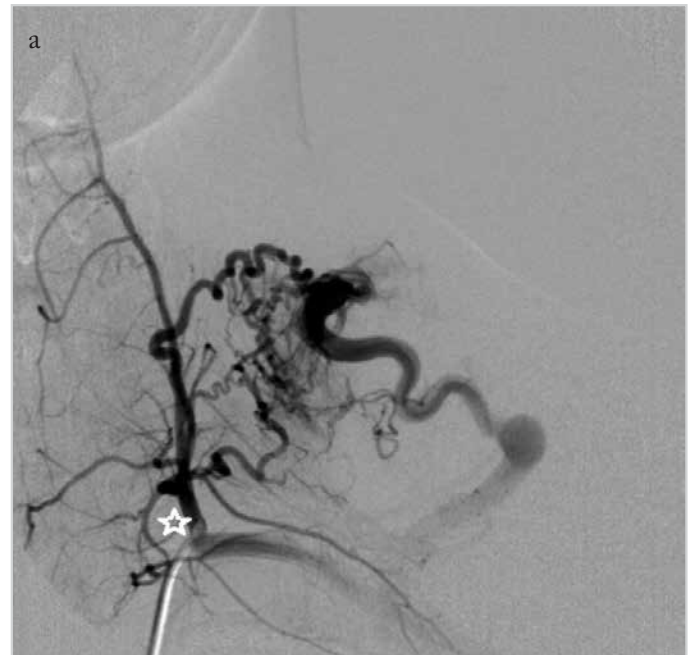

Figure 3. a, b. Digital subtraction angiography of the left subclavian artery demonstrates a hypervascularized tumor, which was fed by the thyrocervical trunk (star) and costocervical trunk (arrow)

Accurate diagnosis was not obtained with fine needle aspiration biopsy (FNAB) that was performed on the solid component of tumor to exclude malignancy. A preliminary diagnosis of post-traumatic AV fistula was made because of thrill and trauma history. Therefore, we decided to perform excision and did not try beta-blocker treatment before the surgery. The tumor was completely resected after providing information to the patient with regard to injuries of the subclavian artery, phrenic nerve, or brachial plexus, and patient's informed consent form was obtained. The patient did not require intraoperative blood transfusion, and there were no complication related to brachial plexus or other structures in the postoperative period. The postoperative histopathologic examination revealed an IMH.

Discussion

Intramuscular hemangioma is a benign vascular tumor that generally occurs in the extremities and chest wall, rarely appearing in the head and neck region (1, 2). Although IMH most commonly arises from the masseter muscle in the head and neck region, other sites of origin are the trapezius, periorbital, sternocleidomastoid, and temporal muscles (2). To date, five cases of IMH have been published in the literature (3-6). Of the five cases, one was located in the middle scalenius muscle, one in the posterior scalenius muscle, one in the anterior scalenius muscle, and the others originated from unspecified scalene muscles (3-6). This is the sixth case, wherein IMH originated from the scalene muscles in the literature.

Intramuscular hemangiomas generally occur in adolescents and young adults and do not have a significant difference in sex predominance (1). As they are mostly congenital, endocrinologic causes and especially trauma comprise the major part of their etiology (4). In our patient, we believe trauma played a role in this tumor's etiology due to the gradual growth of swelling that occurred as a result of blunt trauma to the neck while wrestling 2 years ago.

Intramuscular hemangioma usually presents as a soft, well-defined, mobile, fluctuant mass. Findings such as pulsation, thrill, or discoloration on the skin is not observed in IMHs, which are different from AV fistulas or intracutaneous hemangiomas. Pain may be present if the tumor is pressed (5). Despite the huge mass, pain was not present in our case. The presence of thrill was indicative of AV fistula. The differential diagnosis of neck masses with these findings includes paragangliomas, schwannomas, lymphadenopathy, branchial cysts, lymphangiomas, rhabdomyosarcomas, arteriovenous malformation, or myositis ossificans (7).

The preoperative diagnosis of IMH contains several difficulties. Preoperative histopathologic diagnosis in hypervascularized masses such as hemangioma and arteriovenous malformation is difficult because the biopsy could not be performed because of the risk of bleeding and would require many units of blood if performed (4). However, USG-guided FNAB was performed to exclude malignancy because of tumor's solid component and the result was nondiagnostic in our case. Regardless of reports

that USG-guided core needle biopsy was as helpful as FNAB in the diagnosis of IMH, core needle biopsy is extensively regarded as contraindicated in vascular pathologies such as hemangioma because of the risk of excessive bleeding (5). Hence, core needle biopsy was not performed in this patient to avoid hemorrhage.

The diagnostic value of MRI in soft tissue tumors is undisputed (8). IMH has a hypointense signal voiding in T1-weighted images and hyperintense signal voiding in T2-weighted images and is also characterized by extensive enhancement in gadolinium-enhanced MRI (2). Although calcification foci may be observed in computed tomography (CT) scans of hemangiomas, MRI is superior to CT in the differential diagnosis of hemangiomas (8). Furthermore, angiography, especially DSA, plays an important role in the detection of feeder vessels in the preoperative evaluation of vascular lesions in addition to its diagnostic feature in hemangiomas (9). Preoperative angioembolization could be performed to prevent intraoperative bleeding in surgical planning (2).

Although the main treatment of choice of IMH is surgical excision, observation is recommended by some authors (10). Observation is preferred if a tumor is tightly adhered to the adjacent structures. Unlike superficial hemangiomas, IMHs do not demonstrate spontaneous regression (7). Surgical excision of IMH should be considered at the forefront if the mass is gradually growing; if the patient has pain, local skin necrosis, thrombocytopenia, and cosmetic concerns; or if malignancy is suspected (2, 11). In addition, according to the literature, radiotherapy is contraindicated in the treatment of IMH because of the possibility of malignant transformation and low success rate (7). Based on our knowledge, our patient's tumor was surgically resected along with the adjacent muscle tissues while taking care to preserve the phrenic nerve, brachial plexus, and left subclavian artery. No complications were observed in the 3-month follow-up period.

Conclusion

Intramuscular hemangiomas that originate from the scalene muscles are rarely seen. Although USG and CT are important in the preoperative diagnosis of IMH, MRI and DSA are distinctly superior to other modalities. Surgical en-bloc resection is the main modality in the treatment of IMH and excision with adjacent muscle tissue reduces the risk of recurrence.

Informed Consent: Written informed consent was obtained from patients' parents who participated in this study.

Peer-review: Externally peer-reviewed.

Author Contributions: Concept - E.Ö., E.Y.; Design - E.Ö., E.Y., İ.E.Ö.; Supervision - B.P., K.S.O.; Resource - B.P., K.S.O.; Materials - E.Ö., E.Y., İ.E.Ö.; Data Collection and/or Processing - E.Ö., E.Y., İ.E.Ö.; Analysis and/or Interpretation - B.P., K.S.O.; Literature Search - E.Ö., E.Y., İ.E.Ö.; Writing - E.Ö., E.Y.; Critical Reviews - B.P., K.S.O.

Conflict of Interest: No conflict of interest was declared by the authors.

Financial Disclosure: The authors declared that this study has received no financial support.

Hasta Onamı: Yazılı hasta onamı bu çalışmaya katılan hastanın ailesinden alınmıştır.

Hakem Değerlendirmesi: Dış bağımsız.

Yazar Katkıları: Fikir - E.Ö., E.Y.; Tasarım - E.Ö., E.Y., İ.E.Ö.; Denetleme - B.P., K.S.O.; Kaynaklar - B.P., K.S.O.; Gereçler - E.Ö., E.Y., İ.E.Ö.; Veri Toplanması ve/veya İşlemesi - E.Ö., E.Y., İ.E.Ö.; Analiz ve/veya Yorum - B.P., K.S.O.; Literatür Taraması - E.Ö., E.Y., İ.E.Ö.; Yazıyı Yazan - E.Ö., E.Y.; Eleştirel İnceleme - B.P., K.S.O.

Çıkar Çatışması: Yazarlar çıkar çatışması bildirmemişlerdir.

Finansal Destek: Yazarlar bu çalışma için finansal destek almadıklarını beyan etmişlerdir.

References

1. Fletcher CDM, Unni KK, Mertens F. (Eds.) World Health Organization Classification of Tumors: Pathology and genetics of tumours of soft tissue and bone. IARC Press: Lyon 2002.
2. Rossiter JL, Hendrix RA, Tom LW, Potsic WP. Intramuscular hemangioma of the head and neck. Otolaryngol Head Neck Surg 1993; 108: 18-26. [CrossRef]
3. Ferlito A, Nicolai P, Gale N. Intramuscular haemangioma of the middle scalene muscle. Acta Otorhinolaryngol Belg 1980; 34: 345-9.
4. Scott JES. Haemangioma in skeletal muscle. Br J Surg 1957; 44: 496-501. [CrossRef]
5. Cho JK, Cha W, Sung MW. Intramuscular hemangioma in the anterior scalene muscle diagnosed by core needle biopsy. Clin Exp Otorhinolaryngol 2015; 8: 298-301. [CrossRef]
6. Van Abel KM, Carlson ML, Janus JR, Torres-Mora J, Moore EJ, Olsen KD, et al. Intramuscular hemangioma of the scalene musculature masquerading as a paraganglioma: A case series. Am J Otolaryngol 2013; 34: 158-62. [CrossRef]
7. Wolf GT, Daniel F, Krause CJ, Kaufman RS. Intramuscular hemangioma of the head and neck. Laryngoscope 1985; 95: 210-3. [CrossRef]
8. Griffin N, Khan N, Thomas JM, Fisher C, Moskovic EC. The radiological manifestations of intramuscular haemangiomas in adults: Magnetic resonance imaging, computed tomography and ultrasound appearances. Skeletal Radiol 2007; 36: 1051-9. [CrossRef]
9. Burrows PE, Mulliken JB, Fellows KE, Strand RD. Childhood hemangiomas and vascular malformations: Angiographic differentiation. AJR Am J Roentgenol 1983; 141: 483-8. [CrossRef]
10. Stofman GM, Reiter D, Feldman MD. Invasive intramuscular hemangiomas of the head and neck. Ear Nose Throat J 1989; 68: 612-6.
11. Doğan R, Korkut AY, Eren SB. İntramasseter hemanjiom. Turk Arch Otolaryngol 2012; 50: 46-9.