

Lingual Osseous Choristoma

Şükrü Turan¹, Mehmet Özgür Pınarbaşı¹, Mustafa Açıklan², Ercan Kaya¹, Erkan Özüdoğru¹

¹Department of Otorhinolaryngology, Eskişehir Osmangazi University School of Medicine, Eskişehir, Turkey

²Department of Pathology, Eskişehir Osmangazi University School of Medicine, Eskişehir, Turkey

Case Report

Abstract

An osseous choristoma is a rare benign lesion consisting of normal bone tissue; it is seen in abnormal locations. It is most often seen in the posterior 1/3 of the tongue in the head. Its etiopatogenesis is controversial, and till date, less than 100 cases have been reported in the literature. Although a lingual osseous choristoma is asymptomatic, in some patients, symptoms such as swelling sensation in the throat, globus pharyngeus, dysphagia, retching, nausea, and sore

throat have been reported. In this article, a 41-year-old female patient admitted to our clinic with throat pain and globus pharyngeus who underwent an excision from the region of radix lingua and the result of histopathological examination was reported as "osseous choristoma" was presented and related literature is reviewed.

Keywords: Choristoma, osteoma, tongue, surgery

Introduction

Osseous choristoma is a rare benign lesion that develops histologically from normal matured bony tissue, but seen in an anatomic region in which bone tissue is not normally found (1). Less than 100 cases of lingual osseous choristoma have been published from first defined until now. In this study, a 41-year-old female patient, who applied with the complaints of sore throat and globus pharyngeus, underwent mass excision from the posterior 1/3 of the tongue and the result of histopathological examination was reported as "osseous choristoma" was presented and related literature is reviewed.

Case Report

A 41-year-old female patient applied to our clinic with the complaints of swelling sensation in the throat and globus pharyngeus that had occurred for about 6 months. In the ear-nose-throat examination, an approximately 1×0.5 cm-sized white mass was found in the right posterior 1/3 of the tongue, in the anterior part of the foramen caecum linguae, in line with the circumvallate papilla (Figure 1). Lingual thyroid, mucocele, and lingual thyroglossal duct cyst was considered as the clinical pre-diagnosis. Ultrasonographic evaluation of the neck revealed normal-sized thyroid gland with normal localization, and the results of thyroid function tests were normal. The patient received

antibiotic and anti-inflammatory therapy for two weeks and no regression was observed in the mass during the control examination. The patient was recommended to undergo an operation. Before the operation, written informed consent was received from the patient. Through direct laryngoscopy under general anesthesia, the solid and white mass covered with normal mucosa in the posterior 1/3 part of the tongue was completely excised. In the microscopic examination, matured bony tissue was observed in a large area beginning below the epithelium in the stroma. Minimal chronic inflammatory cell infiltration was found beside the bony tissue (Figure 2). The histopathological examination was reported as "osseous choristoma." No recurrence was observed in the control endoscopic examination performed in the postoperative 1st week and 4th month (Figure 3).

Discussion

Lingual osseous choristoma is a rare, slowly growing, well-demarcated, and benign lesion that develops from matured bony tissue. It was first defined with an excised lesion from the dorsum of the tongue by Monserrat in 1913. The author used the term "lingual osteoma" to describe the mass (1). Krolls et al. (2) used the definition of osseous choristoma in their series, including nine cases in 1971, and they specified that osseous choristoma



This study was presented as a poster at the 37th Turkish National Otorhinolaryngology and Head and Neck Surgery Congress on 28 October - 1 November 2015, Antalya, Turkey.

Address for Correspondence:

Mehmet Özgür Pınarbaşı

E-mail: ozgurpinarbasli@gmail.com

Received Date: 30.12.2015

Accepted Date: 21.03.2016

© Copyright 2016 by Official Journal of the Turkish Society of Otorhinolaryngology and Head and Neck Surgery Available online at www.turkarchotorhinolaryngol.org

DOI: 10.5152/tao.2016.1448

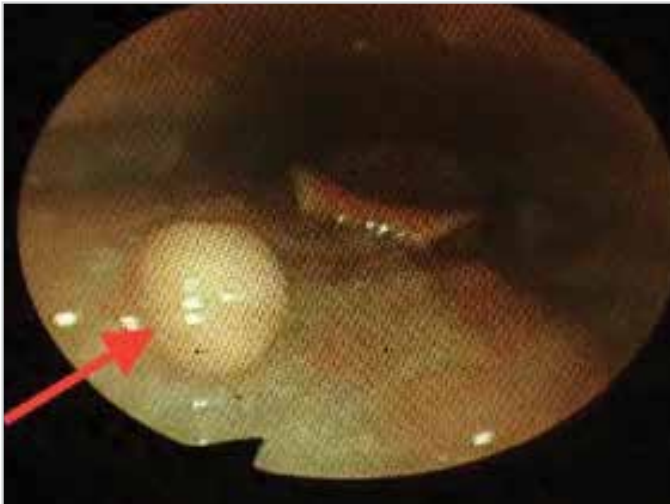

Figure 1. Endoscopic image of the mass in the posterior 1/3 of the tongue

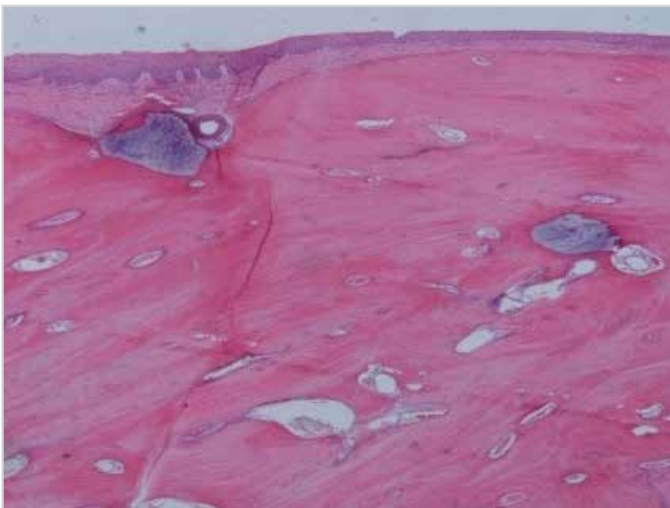


Figure 2. Mature bony tissue appearing nodular and beginning under the epithelium in the mucosa (H&E×40)

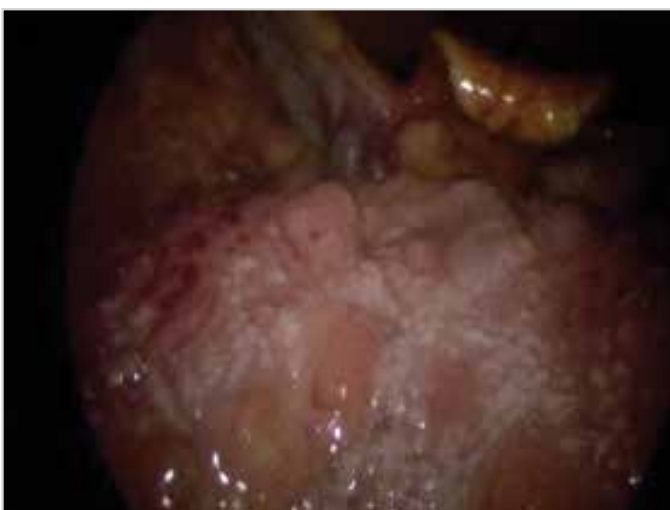

Figure 3. Endoscopic image of the patient in the postoperative 4th month

is formed from normal bony tissue placed in an abnormal localization. Lingual osseous choristoma is seen in the age range of 5 to 73 years, particularly between the ages of 20 to 50, and the

mean age of patients is 28.7 years (3-6). The frequency of lingual osseous choristoma is 2.7-4 times higher among females than among males (3, 5-7). In our case, the patient was a 41-year-old female, which was consistent with the literature expectation.

Osseous choristoma is localized in the oral cavity, mostly in the tongue. Buccal mucosa and alveolar mucosa are also defined in the oral cavity in addition to the tongue (4). Lingual osseous choristoma is mostly (71%) located beside the foramen caecum and circumvallate papilla in the posterior 1/3 of the tongue. Less frequently, it is located in the lateral edge of the tongue and in the middle 1/3 of the tongue (at rates of 17% and 6%, respectively) (3, 4). In 1931, Liu and Tan (7) published a case of bilateral osseous choristoma located on both sides of the foramen caecum. Except this case, other osseous choristoma cases published in the literature are unilateral. Lingual osseous choristoma is localized at the dorsum of the tongue (1, 8). In our case, lingual osseous choristoma was unilateral and located in the posterior 1/3 of the tongue dorsum.

Although lingual osseous choristoma is generally asymptomatic, some symptoms including swelling sensation in the throat, globus pharyngeus, a sticking feeling while swallowing, dysphagia, retching reflex, nausea, and sore throat were reported in symptomatic cases (3, 9). Yamamoto et al. (10) reported a case with the complaint of a severe vomiting reflex. In the study of Maqbool et al. (11), the patient had the complaint of respiratory distress due to airway obstruction. Our case had the complaints of swelling sensation in the throat and globus pharyngeus. Some authors suggested that the symptoms were associated with the diameter and localization of the lesion (3, 5). On the other hand, Supiyaphun et al. (6) reported no relationship between the size of osseous choristoma and symptoms. We think that the presence of cases with asymptomatic large diameter masses, as well as symptomatic cases with small diameter masses, in literature supports this view. Also in our case, although the mass was small in diameter, the patient had some symptoms.

Lingual osseous choristoma appears as a pedunculated or sessile mass. Its pedunculated form is more common. It is often covered with normal mucosa. In the literature, papillomatous forms covered with ulcerated surface have been reported (2). In our case, the mass was covered with normal mucosa and it was in sessile form. The diameters of lingual osseous choristomas have been reported to range from 3 mm to 50 mm. In a case with respiratory distress due to airway obstruction, Maqbool et al. (11) excised a lesion with the dimensions of 50×40 mm, which is the largest lesion ever reported. The size of the lesion in our case was 10×5 mm.

Although the pathogenesis of lingual osseous choristoma is still controversial, two theories are emphasized. These are the developmental theory and the posttraumatic (reactive) theory (1, 3, 12). Histologically, osseous choristomas which are benign and normal in appearance of bony tissue locate submucosally. Bony tissue is usually observed in fibrovascular tissue without real encapsulation. Lingual choristoma is formed from mature lamellar

bone with a well-developed Haversian system and bone marrow spaces that are covered with mucosa; but real osteoblastic and osteoclastic activity is not observed (1, 8).

Diagnosis of the lingual osseous choristoma is difficult because of its very rare occurrence, being asymptomatic in many cases, and its localization. It can be overlooked even in a detailed physical examination since it is located in the posterior 1/3 of the tongue. Some patients are coincidentally diagnosed as a result of examinations performed for other complaints. The most important differential diagnosis for the lesions around the foramen cecum is the ectopic thyroid gland. For differentiation, the ultrasonography of the neck and thyroid function tests can be used. In our case, ectopic thyroid tissue was considered as a pre-diagnosis and the USG of the neck and thyroid function tests were performed. The results of these tests helped us to eliminate this diagnosis. Computed tomography of the neck is helpful in the radiological diagnosis of lingual osseous choristoma (8).

The treatment of lingual osseous choristoma is simple surgical excision. In the literature, recurrence and malignant transformation in lingual osseous choristoma has not been reported. Recurrence was not observed in the endoscopic examination of our patient that was performed for control in the postoperative 1st and 4th months.

Conclusion

Lingual osseous choristoma is a rare lesion that has a benign clinic. It should be kept in mind in the differential diagnosis of patients presenting with masses at the tongue base.

Informed Consent: Written informed consent was obtained from patient who participated in this study.

Peer-review: Externally peer-reviewed.

Author Contributions: Concept - Ş.T.; Design - Ş.T.; Supervision - E.Ö.; Analysis and/or Interpretation - E.K., M.Ö.P.; Literature Search

- Ş.T., E.K.; Writing Manuscript - Ş.T., M.Ö.P.; Critical Review - E.Ö., M.Ö.P.; Other - Histopathologic Examination - M.A.

Conflict of Interest: No conflict of interest was declared by the authors.
Financial Disclosure: The authors declared that this study has received no financial support.

References

1. Benamerand MH, Elmangoush AM. Lingual osseous choristoma case report and review of literature. *Libyan J Medicine* 2007; 2: 46-8. [\[CrossRef\]](#)
2. Krolls SO, Jacoway JR, Alexander WN. Osseous choristomas (osteomas) of intra oral soft tissues. *Oral Surg Oral Med Oral Pathol* 1971; 32: 588-95. [\[CrossRef\]](#)
3. Gorini E, Mullace M, Migliorini L, Mevio E. Osseous choristoma of the tongue: A review of etiopathogenesis. *Case Rep Otolaryngol* 2014; 2014: 373104. [\[CrossRef\]](#)
4. Andressakis DD, Pavlakis AG, Chrysomali E, Rapis AD. Infected lingual osseous choristoma. Report of a case and review of the literature. *Med Oral Patol Oral Cir Bucal* 2008; 13: 627-32.
5. Chou L, Hansen LS, Daniels TE. Choristomas of the oral cavity: a review. *Oral Surg Oral Med Oral Pathol* 1991; 72: 584-93. [\[CrossRef\]](#)
6. Supiyaphun P, Sampatanakul P, Kerekhanjanarong V, Chawakit-hareon P, Sastarasadhith V. Lingual osseous choristoma: a study of eight cases and review of the literature. *Ear Nose Throat J* 1998; 77: 316-25.
7. Liu JY, Tan KKH. Lingual osteoma: case report and literature review. *Singapore Med J* 2011; 52: 198.
8. Khanna R. Khanna R. Osseous choristoma of the oral cavity: A rare entity review. *Int J Dent Med Spec* 2014; 1: 25-7.
9. McClendon EH. Lingual osseous choristoma. Report of two cases. *Oral Surg Oral Med Oral Pathol* 1975; 39: 39-44. [\[CrossRef\]](#)
10. Yamamoto M, Migita M, Ogane S, Narita M, Yamamoto N, Takaki T, et al. Osseous choristoma in child with strong vomiting reflex. *Bull Tokyo Dent Coll* 2014; 55: 207-15. [\[CrossRef\]](#)
11. Maqbool M, Ahmad R, Ahmad R. Osteoma of the tongue: a rare cause of upper airway obstruction. *Indian Pediatr* 1992; 29: 1429-31.
12. Shimono M, Tsuji T, Iguchi Y, Yamamura T, Ogasawara M, Honda T, et al. Lingual osseous choristoma. Report of 2 cases. *Int J Oral Surg* 1984; 13: 355-9. [\[CrossRef\]](#)