

# The Analysis of Patients Operated for Frontal Sinus Osteomas

## Original Investigation

Şükrü Turan, Ercan Kaya, Mehmet Özgür Pınarbaşı, Hamdi Çaklı

Department of Otorhinolaryngology, Eskişehir Osmangazi University School of Medicine, Eskişehir, Turkey

## Abstract

**Objective:** Paranasal sinus osteomas are benign tumors that are smooth-walled, slow-growing, and induced by bone tissue. Although their most common localization is the frontal sinus, some osteomas are seen in the ethmoid, maxillary, and sphenoid sinuses. Frontal sinus osteomas are often asymptomatic; however, when they become symptomatic, headache is the most common complaint. In this study, we aimed to analyze the postoperative results of patients who were diagnosed with frontal sinus osteoma and were operated with appropriate surgical techniques.

**Methods:** We retrospectively evaluated 14 patients who were diagnosed with frontal sinus osteoma and were operated in our department between March 2009 and July 2014. The following parameters were analyzed: patients' age and gender, complaints at the time of admission to our clinic, pathological findings from physically examination, tumor features observed in preoperative paranasal sinus computed tomography (size and localization), surgical methods applied, intra- and postoperative complications, and recur-

rence rates. All patients preoperatively provided informed consent.

**Results:** Of the 14 patients, 7 were males and 7 were females, with a mean age of 40.57 years. A total of 11 (79%) osteomas were located within the frontal sinus and 3 (21%) within the frontal recess. External surgical approach was performed to 11 patients, endoscopic approach was performed to 2 patients and external and endoscopic approach was performed to 1 patient together.

**Conclusion:** Although the preferred surgical method in frontal sinus osteoma depends on size and localization of tumors, experience of surgeon is also important. Although the external surgical approach is appropriate for large and laterally localized osteomas, the endoscopic approach is appropriate for small and inferomedially localized osteomas. In both surgical approaches the site of origin should be drilled.

**Keywords:** Endoscopic sinus surgery, osteoma, paranasal sinus and surgery, frontal sinus

## Introduction

Paranasal sinus osteomas are rare benign lesions. Paranasal sinus osteomas are most commonly seen in the frontal sinus (1, 2). Frontal sinus osteomas often remain asymptomatic because of their slow growth. They are frequently detected incidentally. Most frequently, the complaints of head and facial pain are seen when frontal sinus osteomas become symptomatic. In addition, nonspecific complaints such as a runny nose, postnasal drip, and nasal congestion can be seen. Although it is rare, particularly large frontal sinus osteomas cause intraorbital extension and intracranial complications (edema around the eye, loss of vision, exophthalmos, diplopia, pneumocephalus, intracranial mucocele, ce-

rebrospinal fluid leakage, bacterial meningitis, and brain abscess) (3). Osteomas are often seen as a single lesion. Multiple osteomas are seen in Gardner syndrome, which shows autosomal dominant inheritance (4).

In this study, we aimed to analyze the postoperative outcomes of patients who were diagnosed with frontal sinus osteoma in our clinic and operated with an appropriate surgical technique.

## Methods

In this study, 14 patients who were diagnosed with frontal sinus osteoma in our clinic between March 2009 and July 2014 and who had under-



This study was presented as a poster presentation with 054 poster number in 11<sup>th</sup> Turkish Rhinology Congress on April 16-19, 2015 in Antalya, Turkey.

### Address for Correspondence:

Şükrü Turan  
 E-mail: drsukruturan@gmail.com  
 Received Date: 11.06.2015  
 Accepted Date: 31.12.2015

© Copyright 2015 by Official Journal of the Turkish Society of Otorhinolaryngology and Head and Neck Surgery Available online at [www.turkarchotorhinolaryngol.org](http://www.turkarchotorhinolaryngol.org)

DOI: 10.5152/tao.2015.1149

gone surgical interventions were retrospectively evaluated. The approval of the Clinical Research Ethics Board of Eskişehir Osmangazi University was received with the ethical committee protocol number 80558721/248. The patients' ages, genders, complaints for which they applied to our clinic, pathological findings determined on physical examination, tumor characteristics (size and location) found through preoperative paranasal sinus computed tomography (PNS CT), surgical procedures, intraoperative/postoperative complications, and recurrence rates were evaluated. Osteomas were assessed according to the classification system of Chiu et al. (5). Written informed consent was obtained from all patients before the surgery.

Surgery was performed in symptomatic patients. Although the surgical approach was determined according to the place and diameter of the osteoma and the experience of the surgeon, an external approach was mostly applied. Although the incision above the eyebrow area under general anesthesia varies according to each case in the external approach, it was generally applied in a length of 3–6 cm. In all cases, the osteoma was tried to be removed as a whole by out-fracture, after the base got thinner with the help of a burr. Then, it was cleaned using a burr in order not to leave remnants in the place of origin. Because the mucosal membrane was protected in all cases, the sinus obliteration was not implemented. After being placed minutely, the osteoplastic flap was sutured by making holes with a burr in all cases. The opening of the nasofrontal channel was checked in all cases. The endoscopic approach was particularly applied in small and inferomedially located osteomas.

All the patients were postoperatively followed with anterior rhinoscopy and endoscopic examination at 2-month intervals in the first 6 months and at 6-month intervals thereafter. PNS CT was also requested in the postoperative controls.

## Results

Seven of the patients (50%) included in the study were male and seven were female (50%). The youngest patient was 22 years old and the oldest was 63 years old; thus, the average age was calculated as 40.57.

While the most common complaint of the patients was headache, with a rate of 71%, nasal congestion was the second, with a rate of 35%. The complaints of the patients in application to our outpatient clinic are shown in Table 1.

In the ear, nose, and throat physical examination and PNS CT of the patients, in addition to the frontal sinus osteoma, a deviated septum in five patients (35%), nasal polyposis in three patients (21%), frontal mucopyocele in three patients (21%), bilateral inferior concha hypertrophy in two patients (14%), and middle concha bullosa in one patient (7%) were detected.

**Table 1.** The complaints of patients applying to the outpatient clinic

Symptoms	Number of patients	%
Headache	10	71
Nasal congestion	5	35
Postnasal drip	4	29
Swelling in the eye	1	7

**Table 2.** The frontal sinus osteoma staging system of Chiu et al. (5)

Stage 1	Origin of the osteoma posterior and inferior in the frontal recess; localization of the osteoma medial to a virtual sagittal plane passing through the lamina papyracea; anteroposterior (AP) diameter of the tumour is less than 75% of the AP diameter of the frontal sinus
Stage 2	As stage I; AP diameter of the tumour greater than 75% of the AP diameter of the frontal recess
Stage 3	Origin of the osteoma anterior and/or superior in the frontal sinus and/or osteoma extending lateral to a virtual sagittal plane passing through the lamina papyracea
Stage 4	The tumor filling the entire frontal sinus

The average of the follow-up duration was calculated as 35.2 months, with the shortest period 7 months and the longest 64 months.

According to the preoperative PNS CT measurements of the patients, the smallest osteoma was measured as 8×8 mm and the largest as 25×37 mm; the average was detected as 14.5×20.5 mm. Osteomas larger than 30 mm are considered as a giant osteoma, with giant osteoma detected in three of our patients. The surgical osteoplastic flap procedure was applied in cases of giant osteomas. Eight of the frontal osteomas (57%) were located on the right while six of them (43%) were found on the left. While 11 (79%) of the osteomas were located in the frontal sinuses, three (21%) of them were located in the frontal recess. Bilateral localization was not detected in any patient. Extension of the osteomas into the orbital and intracranial field was not detected in the preoperative and intraoperative assessments. Samples of frontal sinus osteomas on PNS CT coronal and axial sections are shown in Figure 1.

Frontal sinus osteomas were assessed according to the staging system of Chiu et al. (5) (Table 2). According to this staging system, three patients (21%) were found to be stage 4, nine patients (64%) stage 3, and two patients (14%) stage 2.

The external approach was performed in eleven patients; the endoscopic approach was performed in two patients and the external and endoscopic approaches were performed together in one patient. The endoscopic approach was applied in two cases

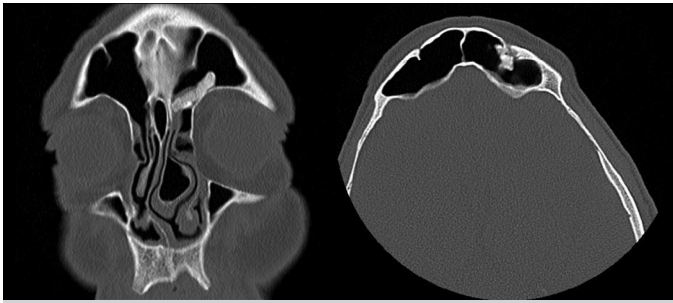


Figure 1. PNS CT images in coronal and axial sections

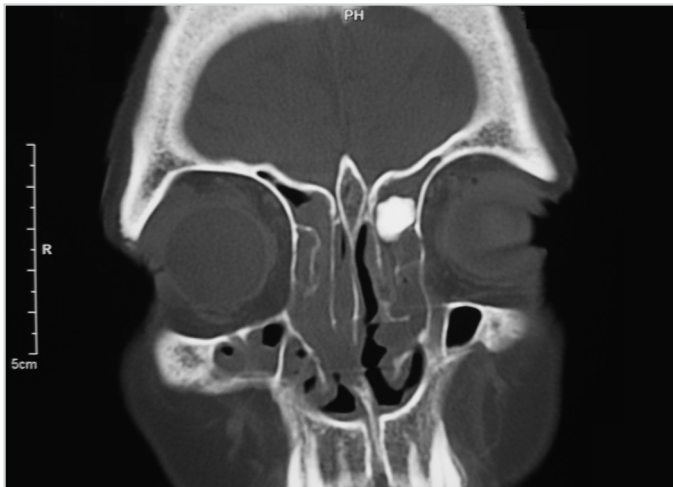


Figure 2. Preoperative PNS CT of the patient who had undergone the endoscopic approach

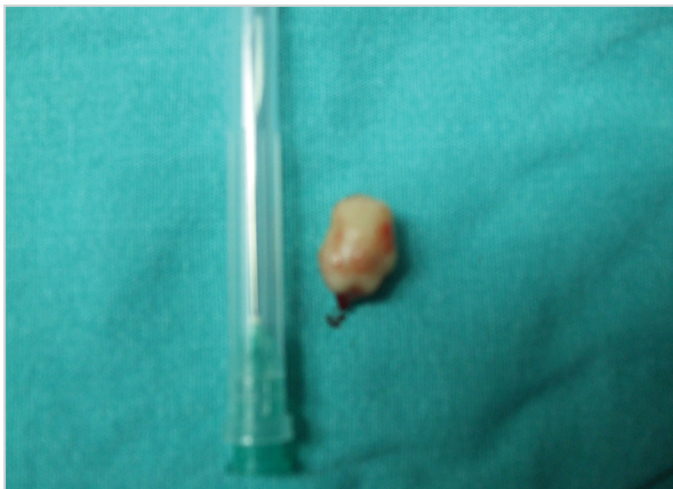


Figure 3. Osteoma excised with the endoscopic approach

having an osteoma located in the frontal recess and smaller than 1 cm in diameter. Osteoma excision was performed using an endoscopy guided burr. Combined treatment was applied to the patient in whom osteoma excision was performed in the right frontal sinus through the external approach in an outside medical center in 2004 and in whom recurrence was detected in the five-year follow-up. The patient had an osteoma showing

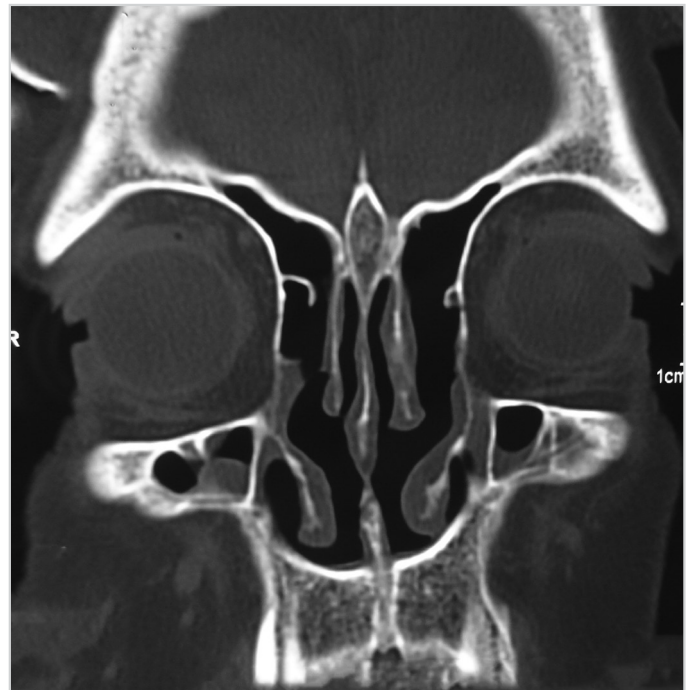

Figure 4. Control PNS CT in the 4<sup>th</sup> postoperative month

extension from the right frontal sinus toward the ethmoid. On account of the fact that recurrence was detected in the patient in whom a combined surgical approach was applied by us in the postoperative 19<sup>th</sup> month, external surgery was again performed with the right osteoplastic flap approach. No recurrence was detected at the 7-month follow-up.

The preoperative PNS CT, the osteoma excised intraoperatively and the control PNS CT examinations obtained in the postoperative 4<sup>th</sup> month of the patient who had undergone an endoscopic approach are seen in Figures 2, 3, and 4.

The osteoma tissue was attempted to be completely removed in all cases. Recurrence was attempted to be prevented by burring the area where the osteoma arose from.

In a case, after the osteoma arising from the posterior wall of the frontal sinus was removed, dural defects occurred in the posterior wall, while remnant tissue was burred. The resulting defect was repaired with oxidized cellulose (Surgicel) by taking the recommendation of neurosurgery. No intracranial complications developed in the patient in the early postoperative period and in a 51-month follow-up.

While the remnant tissue was burred after the osteoma was removed from a case where the osteoma arose from the frontal sinus inferior wall, the defect that occurred in the orbital superior wall was closed with bone wax. In the patient in whom edema developed in the left eye in the early postoperative period, no complications were encountered in the subsequent 39-month follow-up.

## Discussion

Paranasal sinus osteomas are benign tumors that are well-circumscribed, slow-growing, arising from bone tissue, and between 1 and 5 cm (2). The incidence of paranasal sinus osteomas in the general population is 0.43-3% (1). The most frequent location of paranasal sinuses is the frontal sinus, with the incidence reported to be 37-80%. In the order of frequency, osteomas are seen in the ethmoid, maxillary, and sphenoid sinuses, following the frontal sinus (6-8). In the study of Erdogan et al. (9), the ethmoid osteoma was observed as the most frequent (55%). The frequency of frontal sinus osteomas was found to be 37.5% in the same study. Osteomas observed in the middle turbinates have also been reported in the literature (10).

Headache was the most common complaint of patients in our study, which is consistent with the literature, with a rate of 71%. Next, the complaint of nasal congestion draws attention, with a rate of 35%. Septal deviation was detected in our four patients, with a complaint of nasal congestion and bilateral inferior turbinate hypertrophy in one patient. We believe that the complaints of nasal congestion were high because of these accompanying pathologies.

The etiology of osteoma is still a controversial issue. Embryology, traumas, inflammation, polyp calcification, metaplasia, heredity, and calcium metabolism changes are the factors that are emphasized in the etiology (11). Three of our patients (21%) had a history of head trauma, while five patients (35%) had a history of chronic sinusitis.

Paranasal sinus osteomas are often detected in the age range of 30-40 (12, 13). The youngest patient was 22 years old and the oldest was 63 years old; thus, the average age was calculated as 40.57 in our study. The incidence is higher in men than in women (M/F: 1.5-3.1) (12). No gender differences were found in our study. In the study of Keskin et al. (14) that included 17 cases, the incidence in women was calculated to be more than in men (1.42/1).

Frontal sinus osteomas are usually detected incidentally in PNS CT taken due to the complaints of sinusitis and headache. Osteomas appear as a hyperdense and homogeneous mass in CT. PNS CT is the basic examination used in the diagnosis of frontal sinus osteoma, in planning the surgical treatment, and in the observation of small osteomas that do not require surgery (14). Ossifying fibroma and fibrous dysplasia are in the differential diagnosis of osteoma (15). Preoperative PNS CT scans were obtained in all patients in our study).

Osteomas are histologically divided into three different types: compact osteoma, cancellous osteoma, and a mixed type of osteoma having the characteristics of both. There is no difference reported among these types in terms of clinical symptoms and

recurrence tendency (16). While compact osteoma was detected in four of our cases, subtypes were not determined in the others.

Chiu et al. (5) classified the frontal sinus osteomas (Table 2). Endoscopic surgery can be performed in stage 1-2 osteomas according to the staging system. Trephination can be applied in stage 2 osteomas and in the osteomas obliterating the frontal recess much. External surgery should be applied in stage 3-4 osteomas (5). According to this staging system, three (21%) cases were determined as stage 4. Nine (64%) as stage 3, and two (14%) as stage 2 in our study. Endoscopic approach was applied in stage 2 patients. In one of our stage 3 patients, external and endoscopic approaches were applied together. The external approach was applied to the other cases.

Surgical treatment of the frontal sinus osteomas depends on the location and diameter of the osteoma, the anatomical size, the characteristics of the sinus, and the surgeon's experience. External and endoscopic approaches are available in the surgical treatment of frontal sinus osteomas. Osteoplastic flap and frontal ethmoidectomy (Lynch procedure) can be applied as the external approach. In addition to the fact that the external approach gives the surgeon a wider vision, it also provides other advantages, such as easier excision of the osteomas and easier interventions to the intraoperative complications. The disadvantages are postoperative edema in the frontal region, incision scars, and pain. Bignami et al. (17) applied the external approach in frontal sinus osteomas located in the lateral of the virtual line drawn on lamina papyracea, eroded in the anterior posterior wall, showing intracranial or intraorbital extension, and having a smaller anterior posterior diameter than 10 mm.

Osteoma can be removed without the obliteration of the sinus in the osteoplastic flap approach, which is one of the external surgical approaches; also obliteration can be applied after removing the tumor. The basic principle in the related literature is to provide for continuity of the natural frontal sinus drainage, and there is even a suggestion of a mucosal transposition flap for the damaged recess mucosa (5, 18-21). The option of obliteration can be considered in cases where problems are thought possibly might occur during the frontal sinus drainage, in cases where most of the sinus is also removed during the resection of the giant osteoma, and when cerebrospinal fluid leak is encountered. However, serious problems, such as mucocele or mucopyocele, may occur after obliteration. Foramina of Bresschet and residual sinus mucosa that might remain in the recess may cause mucocele or mucopyocele formation even years later. Sinus obliteration has also been shown to cause mucocele or mucopyocele formation (22). Mucoceles may develop after six months, even up to forty years after the first intervention (23). One of the drawbacks of sinus obliteration is that it causes difficulty in detecting recurrence in the postoperative follow-up.



Obliteration was not needed in any of our patients who had undergone external surgery.

The endoscopic approach has some advantages, such as the lack of an incision scar and little postoperative edema. The endoscopic approach may be preferred in small-diameter osteomas located in the medial of the virtual line drawn on the lamina papyracea (24).

Osteomas larger than 30 mm are known as giant osteomas. Osteoplastic flap, external frontoethmoidectomy, and the endoscopic approach can be performed in these cases (25). The surgical osteoplastic flap method was applied to three cases with giant osteoma in our study. Giant osteomas can also be intervened endoscopically using Draf III or Lothrop approaches (26). However, it is important to perform these approaches along with navigation in order to reduce the risk of complications (27).

In the literature, the recurrence rates were reported to be low in cases in which surgery was performed appropriately (12). In our study, recurrence was detected in one patient (7%). The reason for recurrence in patients is non-removal of the osteoma tissue completely. The reasons for leaving the osteoma tissue in the place of intervention can be as follows: insufficient burring because of the risk of defect formation in the burred region, an inexperienced surgeon, not providing a good and adequate surgical view, and the structural similarity between osteoma tissue and the bone tissue that it arises from. Although the posterior wall of the frontal sinus was burred, reconstructions with calvarial bone grafts or synthetic materials were suggested in patients with recurrence after posterior wall resection (28, 29).

## Conclusion

The surgical approach should be selected depending on the location and size of the frontal sinus osteoma, anatomical size, characteristics of the sinus, surgeon's experience, and available existing technical facilities (navigation). Based on all these factors, an external or endoscopic approach is then applied. No matter which surgical approach is used, the osteoma tissue should be fully removed by burring.

**Ethics Committee Approval:** Ethics committee approval was received for this study from the ethics committee of Eskişehir Osman-gazi University / serial number : 80558721-248.

**Informed Consent:** Written informed consent was obtained from patients who participated in this study.

**Peer-review:** Externally peer-reviewed.

**Author Contributions:** Concept - Ş.T.; Design - Ş.T.; Supervision - H.Ç., E.K., M.Ö.P.; Data Collection and/or Processing - Ş.T., H.Ç.,

E.K.; Analysis and/or Interpretation - M.Ö.P.; Literature Search - Ş.T., E.K.; Writing Manuscript - Ş.T.; Critical Review - H.Ç., E.K., M.Ö.P.

**Conflict of Interest:** No conflict of interest was declared by the authors.

**Financial Disclosure:** The authors declared that this study has received no financial support.

## References

1. Earwalker J. Paranasal sinus osteomas: a review of 46 cases. *Skeletal Radiol* 1993; 22: 417-23. [CrossRef]
2. Cıtak EC, Karadeniz C, Oguz A. Osteom in frontal sinus: two case reports. *Turkiye Klin J Pediatr* 1999; 8: 35-7.
3. Gezici AR, Okay O, Ergun R, Daglioglu E, Ergungor F. Case Report: Rare intracranial manifestations of frontal osteomas. *Acta Neurochir* 2004; 146: 393-6. [CrossRef]
4. Cristofaro MG, Giudice A, Amantea M, Riccelli U, Giudice M. Gardner's syndrome: a clinical and genetic study of a family. *Oral Surg Oral Med Oral Pathol Oral Radiol* 2013; 3: 115. [CrossRef]
5. Chiu AG, Schipor I, Cohen NA, Kennedy DW, Palmer JN. Surgical decisions in the management of frontal sinus osteomas. *Am J Rhinol* 2005; 19: 191-7.
6. Brunori A, Santis S, Bruni P, Delitela A. Life threatening intracranial complications of frontal sinus osteomas: Report of two cases. *Acta Neurochir* 1996; 138: 1426-30. [CrossRef]
7. Namdar I, Edelstein DR, Huo J, Lazar A, Kimmelman CP, Soletic R. Management of osteomas of the paranasal sinuses. *Am J Rhinol* 1998; 12: 393-8. [CrossRef]
8. Savastano M, Nardini LG, Marioni G, Staffieri A. The bicoronal approach for the treatment of a large frontal sinus osteoma; A technical note. *Am J Otolaryngol* 2007; 28: 427-9. [CrossRef]
9. Erdogan N, Demir U, Songu M, Ozenler NK, Uluc E, Dirim B. A prospective study of paranasal sinus osteomas in 1,889 cases: changing patterns of localization. *Laryngoscope* 2009; 119: 2355-9. [CrossRef]
10. Kutluhan A, Salviz M, Bozdemir K, Deger HM, Culha I, Ozveren MF. Middle turbinate osteoma extending into anterior cranial fossa. *Auris Nasus Larynx* 2009; 36: 702-46. [CrossRef]
11. Larrea-Oyarbide N, Valmaseda-Castellón E, Berini-Aytés L, Gay-Escoda C. Osteomas of the craniofacial region. Review of 106 cases. *J Oral Pathol Med* 2008; 37: 38-42. [CrossRef]
12. Streck P, Zagólski O, Składzień J, Kurzyński M, Dyduch G. Osteomas of the paranasal sinuses: surgical treatment options. *Med Sci Monit* 2007; 13: CR244-50.
13. Akın I, Tezel Z, Celik H, Gokler H. Frontal osteomlarda osteoplastik flep sonuçlarımız. *K.B.B. ve BBC Dergisi* 2002; 10: 32-7.
14. Keskin İG, İla K, İşeri M, Öztürk M. Paranasal sinüs osteomları. *Turkiye Klinikleri J Med Sci* 2013; 33: 1250-8. [CrossRef]
15. Castelnovo P, Valentini V, Giovannetti F, Bignami M, Cassoni A, Iannetti G. Osteomas of the maxillofacial district: endoscopic surgery versus open surgery. *J Craniofac Surg* 2008; 19: 1446-52. [CrossRef]
16. McHugh J, Mukeherji S, Lucas D. Sino-orbital osteoma: a clinicopathologic study of 45 surgically treated cases with emphasis on tumours with osteoblastoma-like features. *Arch Pathol Lab Med* 2009; 133: 1587-93.

17. Bignami M, Dallan I, Terranova P, Battaglia P, Miceli S, Castellnuovo P. Frontal sinus osteomas: the window of endonasal endoscopic approach. *Rhinology* 2007; 45: 315-20.
18. Mendonça-Caridad J, Lopez PJ, Fayos FV, Miery G. A novel approach to human cranial tissue regeneration and frontal sinus obliteration with an autogenous platelet-rich/fibrin-rich composite matrix: 10 patients with a 6-10 year follow-up. *J Tissue Eng Regen Med* 2013; 7: 491-500. [\[CrossRef\]](#)
19. Dubin MG, Kuhn FA. Preservation of natural frontal sinus outflow in the management of frontal sinus osteomas. *Otolaryngol Head Neck Surg* 2006; 134: 18-24. [\[CrossRef\]](#)
20. Melroy CT, Dubin MG, Senior BA. Management of benign frontal sinus tumors with osteoplastic flap without obliteration. *Operative Techniques in Otolaryngol Head and Neck Surg* 2004; 15: 16-22. [\[CrossRef\]](#)
21. Kuhn FA, Javer AR, Nagpal K, Citardi MJ. The frontal sinus rescue procedure: early experience and three-year follow-up. *Am J Rhinol* 2000; 14: 211-6. [\[CrossRef\]](#)
22. Hybels RL, Newman MH. Posterior table fractures of the frontal sinus: I. An experimental study. *Laryngoscope* 1977; 87: 171-9. [\[CrossRef\]](#)
23. Bordley JE, Bosley WR. Mucocoeles of the frontal sinus: causes and treatment. *Ann Otol Rhinol Laryngol* 1973; 82: 696-702. [\[CrossRef\]](#)
24. Cokkeser Y, Bayarogullari H, Kahraman SS. Our experience with the surgical management of paranasal sinus osteomas. *Eur Arch Otorhinolaryngol* 2013; 270: 123-8. [\[CrossRef\]](#)
25. Yiotakis I, Eleftheriadou A, Giotakis E, Manolopoulos L, Ferekidou E, Kandiloros D. Resection of giant ethmoid osteoma with orbital and skullbase extension followed by duraplasty. *World J Surg Oncol* 2008; 6: 110. [\[CrossRef\]](#)
26. Oleś K, Stręk P, Wiatr M, Paweł S, Wiatr M, Majiej W, et al. Endoscopic treatment of giant skullbase osteomas. *Otolaryngol Pol* 2011; 65: 410-3. [\[CrossRef\]](#)
27. Rokade A, Sama A. Update on management of frontal sinus osteomas. *Curr Opin Otolaryngol Head Neck Surg* 2012; 20: 40-4. [\[CrossRef\]](#)
28. Chang SC, Chen PK, Chen YR, Chang CN. Treatment of frontal sinus osteoma using a craniofacial approach. *Ann Plast Surg* 1997; 38: 455-9. [\[CrossRef\]](#)
29. Hayden MG, Guzman R, Dulai MS, Mobley BC, Edwards MS. Recurring osteoma within a calciumphosphate bone cement cranioplasty: case report. *Neurosurgery* 2009; 64: 775-6. [\[CrossRef\]](#)