

An Unusual Cause of Dysphagia: Live Leech in the Tongue Base

Case Report

Osman Erdoğan¹, Onur İsmi¹, Yusuf Vayisoğlu¹, Mustafa Azizoğlu², Kemal Görür¹, Cengiz Özcan¹

¹Department of Otorhinolaryngology, Mersin University Faculty of Medicine, Mersin, Turkey

²Department of Anaesthesiology and Reanimation, Mersin University Faculty of Medicine, Mersin, Turkey

Abstract

Inhaled or ingested foreign bodies are relatively common causes of airway obstructions. They can be associated with significant morbidity and even mortality. Although various foreign bodies are aspirated or ingested, live leeches are rarely encountered. We reported a case of a live leech at the base of the tongue in an 18-year-old

female patient with a history of unfiltered spring water drinking. We discussed the surgical technique and importance of anesthesia with this brief study.

Keywords: Larynx, dysphagia, leech, foreign body

Introduction

Leeches are blood-sucking hermaphroditic parasites that live in freshwater, natural spring water, and marine environments, particularly in rural areas (1). Direct contact with water, particularly during the leech season (from May to September) may cause infestation by the parasite. Reported infestation sites in the head and neck region include regions of the nose, nasopharynx, larynx, oropharynx, tonsils and the esophagus (2-5). However, leeches used in medicine, which are applied for flap survival in patients undergoing head and neck reconstruction, may migrate to the upper aerodigestive tract and cause ingestion (2). We have presented a case of live leech infestation at the base of the tongue in an 18-year-old female patient with a history of drinking unfiltered spring water.

Case Report

An 18-year-old female patient complaining of dysphagia, bloody saliva, and foreign body sensation in the throat 3 days after drinking from unfiltered spring water presented to the otorhinolaryngology clinic of our tertiary center. Indirect endoscopic laryngeal and oropharyngeal examination using a 70° telescope revealed a dark-green living foreign body with some bleeding on the right side of the base of the tongue (Figure 1). Other physical examination findings were nor-

mal. After admitting the patient to the operation theater, first we attempted to extract the parasite without local anesthesia, which can cause inhibition of the cough reflex and may cause aspiration of the living foreign body during surgery. Because the gag reflex of the patient did not permit any surgical intervention, after administration of 10% Lidocaine pump spray (Vemcaine; Vem İlaç, İstanbul, Turkey), we carefully removed the leech under topical anesthesia with laryngeal punch (Figure 2). One day after hospitalization, the patient completely recovered without any complication and was discharged from the hospital. On the first-week control, she remained well without any complaint. Informed consent of the patient was obtained for this case report.

Discussion

Leeches are parasites living in the fresh-water streams and lakes in the rural areas (6). In patients presenting with dysphagia, hoarseness, and hemoptysis with a history of contact with spring or unfiltered water, an upper airway leech parasite infestation must be considered in the differential diagnosis (7). The presence of a leech in the larynx and upper airway requires emergency intervention because it may result in hemoptysis and airway obstruction. The reason for bleeding in the case of a leech infestation is that the saliva of a leech contains hirudin, which has



This study was presented at the 36th Turkish National Congress of Otolaryngology Head and Neck Surgery as a poster, 05-09 November 2015, Antalya, Turkey.

Address for Correspondence:

Osman Erdoğan
 E-mail: osman_erdogan@outlook.com
 Received Date: 27.07.2015
 Accepted Date: 17.12.2015

© Copyright 2015 by Official Journal of the Turkish Society of Otorhinolaryngology and Head and Neck Surgery Available online at www.turkarchotorhinolaryngol.org

DOI: 10.5152/tao.2015.1240

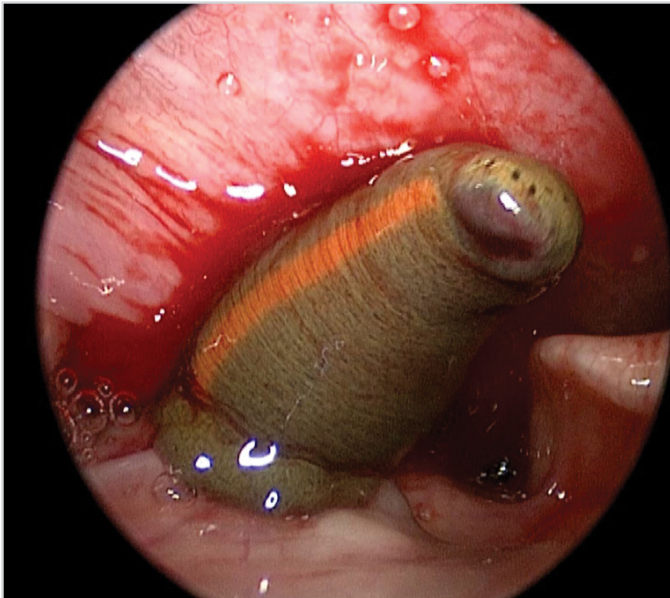


Figure 1. A dark-green living foreign body on right side of the base of tongue is shown

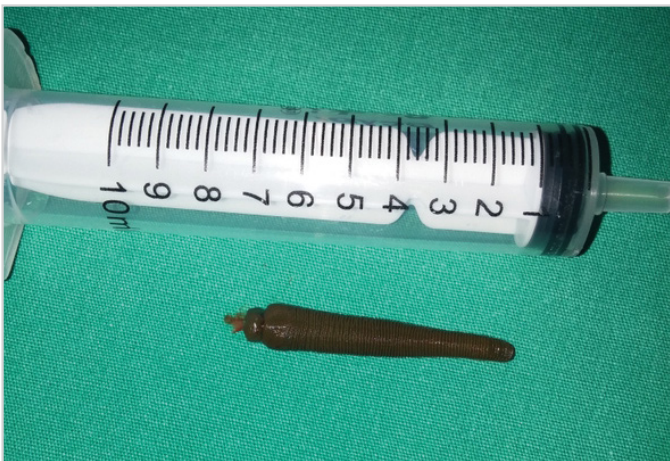

Figure 2. Live leech has been presented

anticoagulant properties. Furthermore, the saliva contains a histamine-like vasodilator that promotes bleeding, causing epistaxis, hemoptysis, or hematemesis (4).

The removal of the leech should be performed with great caution because it strongly attaches to the associated mucosa with its anterior suckers (1). Because the parasite has a slippery surface, there is a risk of rupture during intervention. Furthermore, if it ruptures during surgical intervention, bleeding may continue when some parts of its mouth remain in the mucosa (7). To minimize the risk of rupture, mostly blunt-ended surgical instruments such as laryngeal punches are recommended (6). In addition to the technique of removing the parasite, anesthesia during the surgical procedure is very important. Removal of leeches from the upper airway can be performed

under general or topical/local anesthesia (2). If the leech infestation area is near the lower airway such as the interarytenoid area or epiglottis, there is a risk of aspiration of the parasite during general anesthesia (2). Uygur et al. (2) recommended tubeless induction anesthesia with mask ventilation for the removal of a laryngeal leech, whereas Alioglu et al. (7) preferred removal of the parasite without local anesthesia to prevent the inhibition of reflexes for aspiration. San et al. (1) and Rajati et al. (6) preferred careful intubation under general anesthesia for supraglottic infestations. We removed the leech under topical anesthesia because the gag reflex did not permit the surgical intervention.

Conclusion

A live leech in the tongue base region should be considered in the differential diagnosis of patients presenting with dysphagia, sensation of a foreign body, and bloody saliva. Rural areas and contaminated or unfiltered spring water drinking are predisposing factors for leech infestations in the upper airway. The surgeon and the anesthesiologist should take the necessary measures to avoid hazardous complications such as aspiration and even death during the surgical procedure.

Informed Consent: Written informed consent was obtained from the patient who participated in this study.

Peer-review: Externally peer-reviewed.

Author Contributions: Concept - O.E., O.İ., Y.V., M.A., K.G., C.Ö.; Design - O.E., O.İ., Y.V., M.A., K.G., C.Ö.; Supervision - O.E., O.İ., Y.V., M.A., K.G., C.Ö.; Resources - O.E., O.İ., Y.V., M.A., K.G., C.Ö.; Materials - O.E., O.İ., Y.V., M.A., K.G., C.Ö.; Data Collection and/or Processing - O.E., O.İ., Y.V., M.A., K.G., C.Ö.; Analysis and/or Interpretation - O.E., O.İ., Y.V., M.A., K.G., C.Ö.; Literature Search - O.E., O.İ., Y.V., M.A., K.G., C.Ö.; Writing Manuscript - O.E., O.İ., Y.V., M.A., K.G., C.Ö.; Critical Review - O.E., O.İ., Y.V., M.A., K.G., C.Ö.

Conflict of Interest: No conflict of interest was declared by the authors.

Financial Disclosure: The authors declared that this study has received no financial support.

References

1. San T, Gürkan E, Karaaslan A, Erdoğan B. An unusual cause of hemoptysis: leech in the supraglottic region of the larynx. *J Craniofac Surg* 2014; 25: 531-2. [\[CrossRef\]](#)
2. Uygur K, Yasan H, Yavuz L, Doğru H. Removal of a laryngeal leech: a safe and 20 effective method. *Am J Otolaryngol* 2003; 24: 338-40. [\[CrossRef\]](#)
3. Chen WC, Chien CY, Yang CH, Li JH, Hwang CF. Nasal leech infestation: report of seven leeches and literature review. *Eur Arch Otorhinolaryngol* 2010; 267: 1225-9. [\[CrossRef\]](#)

4. Bilgen C, Karci B, Uluöz U. A nasopharyngeal mass: leech in the nasopharynx. *Int J Pediatr Otorhinolaryngol* 2002; 64: 73-6. [\[CrossRef\]](#)
5. Mohammad Y, Rostum M, Dubaybo BA. Laryngeal hirudiniasis: an unusual cause of airway obstruction and hemoptysis. *Pediatr Pulmonol* 2002; 33: 224-6. [\[CrossRef\]](#)
6. Rajati M, Irani S, Khadivi E, Bakhshae M. An unusual cause of dysphonia with hemoptysis: a laryngeal live leech. *Iran J Otorhinolaryngol* 2014; 26: 181-3.
7. Bulent A, Ilknur O, Beray S, Tulin C, Ulku T, Yildiz D. An unusual cause of hemoptysis in a child: live leech in the posterior pharynx. *Trop Biomed* 2010; 27: 208-10.