

A Rare Variation of Inferior Laryngeal Nerve: Nonrecurrent Laryngeal Nerve

Case Report

Adem Binnetoğlu, Ali Cemal Yumuşakhuyulu, Muhammet Fatih Topuz, Berat Demir, Tekin Bağlam, Murat Sarı

Department of Otorhinolaryngology, Marmara University Faculty of Medicine, İstanbul, Turkey

Abstract

A nonrecurrent laryngeal nerve variant of the inferior laryngeal nerve is very rarely seen, and surgeons should keep it in mind during thyroid surgery. Preoperative findings, like situs invertus and dysphagia lusoria, may be suggestive of a nonrecurrent laryngeal nerve. How-

ever, these findings always have not to be together with nonrecurrent laryngeal nerve, like our case.

Keywords: Thyroid surgery, nonrecurrent laryngeal nerve, dysphagia lusoria

Introduction

Inferior laryngeal nerve, in other words recurrent laryngeal nerve (RLN), is a branch of the vagus nerve. It is responsible for the motor innervation of the intrinsic muscles of the larynx and sensorial innervation of the mucosa in the inferior of vocal cords. It can be damaged in the surgical procedures of cervical and thoracic regions because of its long trace. The damaged RLN leads to vocal cord paralysis in the same side, and subsequently to hoarseness in the patient. If the nerves in both sides are damaged, aphonia and dyspnea are encountered.

Inferior laryngeal nerve anatomically branches from the vagus at the level of the subclavian artery in the right and the aortic arc in the left. It ascends towards the posterior and superior by turning around these formations and it passes through the tracheoesophageal sulcus to enter the larynx at the level of the cricoid cartilage. RLN occasionally (less than 1%) branches from the vagus in the cervical region, turns around the mentioned formations, and vertically enters the larynx (1). This is called non-recurrent laryngeal nerve (NRLN).

Total thyroidectomy was planned for a 41-year-old female patient who visited our clinic with the complaint of a neck mass. The operation was firstly initiated in the left thyroid lobe. It was observed that the left RLN passed through the tracheoesophageal groove. Then, the operation continued with left thyroid lobectomy. After the right thyroid artery and veins were ligated and the thyroid lobe was turned medially, it was observed that the right RLN was not in its normal localization. In this case report, a patient with right NRLN encountered during total thyroidectomy is presented in the light of the literature.

Case Report

In the physical examination of a 41-year-old female patient presenting with the complaint of a mass that had been in the midline of the neck for 2 years and growing over time, a 4×4 cm mobile mass was palpated in the thyroid lobe. The neck ultrasonography (USG) of the patient whose thyroid function tests were found to be normal revealed multiple nodules. One was a 4×3 cm, heterogeneous echogenic nodule that was covered with a thin halo, including cystic spaces, originating from the right thyroid lobe and contained internal vascularization. The other was a heterogeneous echogenic nodule that was 2×2 cm in size and covered with a thin halo in the left lobe. In the thyroid scintigraphy of the patient, the thyroid was observed to have a bilateral hyperplastic appearance, and it was consistent with multinodular goiter. Because the result of fine-needle aspiration biopsy was consistent with that of benign cytology, total thyroidectomy was planned for the patient with the pre-diagnosis of multinodular goiter. The operation was firstly initiated from the left thyroid lobe. The middle thyroid vein was ligated with superior and inferior thyroid arteries and veins. Fascial dissection was performed near the thyroid fascia while monitoring the parathyroid glands. It was observed that the left RLN passed through the tracheoesophageal groove. In the same manner, after the ligation of the arteries and veins of the right thyroid lobe, fascia dissection was performed by monitoring parathyroid glands. However, it was observed that the right RLN was not in its normal localization. The Sym's triangle was analyzed, but the nerve could not be seen. The right RLN was found at the point where it entered the larynx at the posterior cricothyroid



Address for Correspondence:
 Muhammet Fatih Topuz, Marmara Üniversitesi Tıp
 Fakültesi, Kulak Burun Boğaz Hastalıkları Anabilim
 Dalı, İstanbul, Turkey
Phone: +90 553 266 88 55
E-mail: drfatihtopuz@yahoo.com
Received Date: 03.12.2013
Accepted Date: 18.08.2014
Available Online Date/Çevrimiçi Yayın Tarihi:
 14.11.2014

© Copyright 2015 by Official Journal of the Turkish
 Society of Otorhinolaryngology and Head and
 Neck Surgery Available online at
 www.turkarchotorhinolaryngol.org
 © Telif Hakkı 2015 Türk Kulak Burun Boğaz ve Baş
 Boyun Cerrahisi Derneği Makale metnine
 www.turkarchotorhinolaryngol.org web
 sayfasından ulaşılabilir.
 DOI:10.5152/tao.2014.241

junction and was followed with retrograde dissection. It was observed that the nerve passed toward the lateral from the entry site of the posterior cricothyroid junction and left the vagus at the carotid sheath. Considering the existent anatomical variation of the nerve, it was evaluated as NRLN (Figure 1). The postoperative indirect laryngoscopy of the patient whose total thyroidectomy was completed revealed no paralysis in vocal cords. A written informed consent was obtained from the patient.

Discussion

The two most important complications of thyroidectomy are RLN injury and the development of hypoparathyroidism. For the safety of the operation, the surgeons dealing with thyroid surgery should know the anatomical localizations of RLN and parathyroid glands as well as the variations of these structures. During the whole anatomical course of RLN, there have been approximately 30 variations (2). In the literature, the incidence of NRLN was reported to be less than 1% (1). Henry et al. (3) reported NRLN only in 33 of the 6307 patients undergoing thyroidectomy and parathyroidectomy (0.52%). Moreover, in the literature, there are some studies showing that both RLN and NRLN can be found in the same side at the rate of 0.2% (4, 5).

NRLN branches from the vagus in the cervical area. During the whole anatomical course of RLN, there have been approximately 30 variations (2). It has the following three types (6): type 1: the nerve that directly arises from the vagus runs together with the superior thyroid artery pedicle (6); type 2a: NRLN passes parallel to the inferior thyroid artery and transversely above the artery; and type 2b: NRLN passes under the inferior thyroid artery or between its branches (6). In our case, the nerve passed approximately at 0.5 cm over the inferior thyroid artery, which was consistent with Type 2a.

It is quite difficult to establish the preoperative diagnosis of NRLN unless the patient has coexisting findings such as situs inversus and dysphagia lusoria. The finding of situs inversus in preoperative chest radiography is significant for the left NRLN. On the other hand, the appearance of dysphagia lusoria associated with the right aberrant retroesophageal subclavian artery is highly significant for the right NRLN. However, vascular anomaly does not coexist with NRLN in every case. The evaluation of the preoperative chest radiography conducted in our case did not reveal a variant of the subclavian artery. Similarly, no variation of the subclavian artery was observed in the postoperative computed tomography (CT) of the neck, thorax CT, and magnetic resonance angiography of the neck (Figure 2).

There are many discussions regarding which surgical technique decreases the risk of RLN injury during thyroid surgery. In our clinic, we prefer to operate near the thyroid capsule with fascial

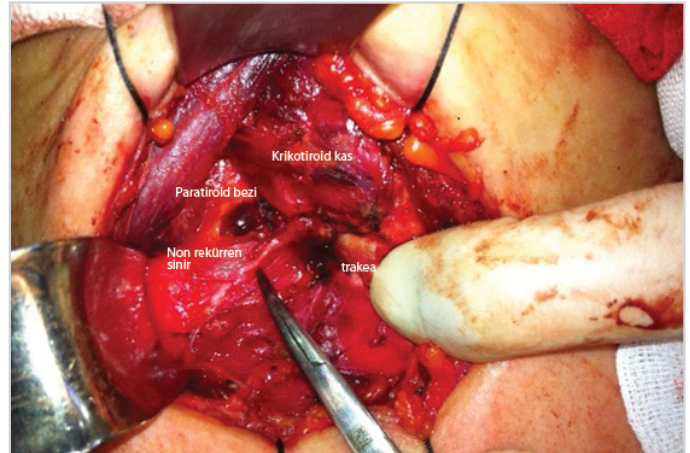


Figure 1. NRLN in intraoperative thyroidectomized patient
NRLN: Non-recurrent laryngeal nerve

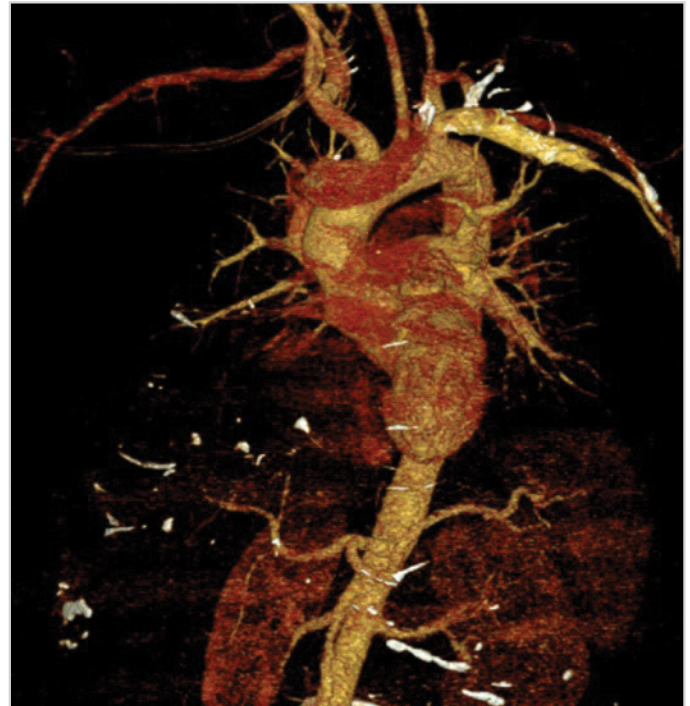

Figure 2. MR angiography. No aberrant subclavian artery accompanying NRLN was observed.

MR: magnetic resonance; NRLN: non-recurrent laryngeal nerve

dissection technique. In this technique, the fascia over the nerve is not removed. Superior and inferior thyroid veins and their arteries are ligated with the middle thyroid vein, and the thyroid is mobilized. The thyroid lobe is lifted using a Babcock forceps and dissected by protecting the blood supply of both parathyroid glands. While performing fascial dissection near the thyroid, the course of RLN is seen under transparent fascia. RLN is observed but thyroidectomy is completed without dissection of the fascia over it. However, RLN under transparent fascia cannot be seen in every case. In such a situation, Sym's triangle is found, and thyroidectomy is completed after identifying the nerve. If the

nerve cannot be explored in the Sym's triangle, NRLN should be kept in mind.

With this method, the possibility of injury is minimized due to the absence of direct contact with the nerve. There are also some schools beginning thyroid surgery with RLN exploration. In this technique, the nerve is initially identified in the Sym's triangle; then, thyroid excision is performed monitoring the nerve. In the literature, studies suggesting that this technique is more appropriate for the safety of the nerve are available (6).

During the intraoperative period, when the nerve is not identified in the tracheoesophageal groove, which is its normal anatomical location, structures entering into the larynx from the Killian-Jamieson area that arise transversely from the carotid cuff and are located in the posterior of the cricothyroid joint should be taken into consideration with the suspicion of NRLN. The more medial localization of the vagus than normal can be a clue for the surgeon (6). Of more than 200 thyroidectomy and parathyroidectomy cases in our clinic, the right NRLN detected only in one patient was consistent with the literature.

Conclusion

Inferior laryngeal nerve is an anatomical structure that should be paid attention to during thyroidectomy because it is a delicate anatomical structure and can have variations. Imaging procedures performed in the preoperative period can reveal information about possible variations, and normal results of imaging techniques do not always mean that there is no variation of the nerve.

Informed Consent: Written informed consent was obtained from the patient.

Peer-review: Externally peer-reviewed.

Author Contributions: Concept - A.B., T.B., M.F.T.; Design - M.F.T., A.B., A.C.Y., T.B.; Supervision - T.B., B.D., M.S.; Funding - M.F.T., A.B., B.D.; Materials - A.B., M.F.T., B.D., T.B.; Data Collection and/or Processing - M.F.T., M.S., T.B., A.C.Y.; Analysis and/or Interpretation - M.F.T., A.B., A.C.Y., T.B., Literature Review - M.F.T., A.B., T.B., M.S.; Writing - M.F.T., A.B., T.B., A.C.Y., M.S.; Critical Review - T.B., M.S., A.C.Y., A.B.

Conflict of Interest: No conflict of interest was declared by the authors.

Financial Disclosure: The authors declared that this study has received no financial support.

References

1. Page C, Monet P, Peltier J, Bonnaire B, Strunski V. Non-recurrent laryngeal nerve related to thyroid surgery: report of three cases. *J Laryngol Otol* 2008; 122: 757-61. [\[CrossRef\]](#)
2. Sadler GP, Clark OH, Von Heerden JA. Thyroid and parathyroid. In: Schwartz SI editor. *Principles of Surgery*. New York: Mc Graw Hill; 1999.p.1661-1715.
3. Henry JF, Audiffret J, Denizot A, Plan M. The nonrecurrent inferior laryngeal nerve: review of 33 cases, including two on the left side. *Surgery* 1988; 104: 977-84.
4. Thompson NW. Thyroid Gland. in: Greenfield LJ editor. *Surgery, scientific principles and practise*, 2nd ed. New York: Lippincott - Raven Publishers; 1997.p.1283-308.
5. Altaca G, Onat D. Tiroidektomi ve komplikasyonlar. *Temel Cerrahi*, 3. bask. Sayek 8 editör. Ankara: Güne Kitabevi; 2004.s.1621-30.
6. Shrinath D, Kamath P, Rathnakar P, Shetty K. Nonrecurrent laryngeal nerve: a rare entity. *Nitte University Journal of Health Science NUJHS* 2012; 2: 2249-7110.