

Otoplasty Outcomes and Results: Does Furnas Setback Suture Affect Complication Rates?

Original Investigation

Oğuz Kuşcu, Övsen Önay, Rıza Önder Günaydın, Taner Yılmaz

Department of Otolaryngology-Head and Neck Surgery, Hacettepe University, Ankara, Turkey

Abstract

Objective: Prominent ear is a common congenital deformity, and many modern otoplasty techniques have been described. In cartilage-sparing techniques, there are two main suture techniques: Mustarde and Furnas. The aim of this study is to evaluate our clinical outcomes comparing suture techniques.

Methods: A combined method (Furnas and Mustarde) and only Mustarde suture were evaluated retrospectively in 54 patients (27 male, 27 female, age range: 5-46). We evaluated the revision needs, elastic headband wearing time, and complications, such as infection and hematoma after otoplasty.

Results: Mustarde and Furnas sutures were performed on 87% (47) patients: 75% (41) bilaterally and 25% (13) patients unilaterally. In 13% (7), only Mustarde suture was performed. In 9% (5) of patients, we needed revision surgery due to unwanted aesthetic results. Among the

91.6 % (50) of patients who were followed with a mastoid head wrap for only 1 day, elastic headband wearing time was 1 week. It was performed for a duration of three days due to postoperative hematoma in 8.4% (4) of patients, and their bandaged follow-ups were extended to 10 days.

Conclusion: We had 91% success in primary surgery and 100% success in revision and secondary surgeries, which were accepted as being quite satisfactory. In our study, we used a standard approach rather than various techniques and came to the conclusion that more elevation may cause more complications. If Furnas suture is used, the complication rate may be higher, such as hematoma, infection, or revision need.

Key Words: Prominent ear, otoplasty, Mustarde technique, Furnas technique, complication

Introduction

Prominent ear is a common congenital deformity and may be a source of psychological distress in both sexes and at any age. It is seen in 5% and has an autosomal dominant heritage pattern. The most common causes of protruded external ear are an underdeveloped or flat antihelix, an overdeveloped, deep concha, or a combination of both of these features (1).

Otoplasty should be performed in the preschool period, before the child socializes and is ridiculed by classmates, because this situation can make irreversible psychological damage. Different techniques for correction of this deformity have been described in the literature, but there is no single widely accepted technique. In most of the techniques, the antihelical fold is frequently created using Mustarde sutures (2). Of cartilage-sparing techniques in our clinic, two main suture techniques are used: Mustarde and Furnas (Figures 1, 2). Sutures that are inserted to recreate the fold of the antihelix are named Mustarde sutures. When the sutures are used between the concha and the mastoid periosteum to decrease the concha-s-

caphoid angle, they are named Furnas setback sutures (3). Although the Mustarde suture technique is a reliable method in otoplasty, this technique has not been discussed enough in published reports. The aim of this study is to evaluate the clinical outcomes, revision needs, elastic headband wearing time, and rates of complications after otoplasty for surgical correction of prominent ears with Mustarde and Furnas sutures.

Methods

This retrospective study was accepted with decision number LUT09/31-4 by the Hacettepe University Faculty Medicine Ethics Committee, and informed consent was obtained from each patient at Hacettepe University Hospital Department of ENT and Head and Neck Surgery. This study included 54 patients who applied to our clinic with prominent ear deformities between 2010 and 2013. Before the surgery, a detailed history was taken from each patient, along with a full ENT examination, to investigate any other possible reason for the deformity, wound-healing tendencies, and connective tissue diseases. Surgery was not performed on patients with connective tissue diseases, wound healing defects, bleeding-clotting prob-



Address for Correspondence:
 Oğuz Kuşcu, Department of Otolaryngology-Head and Neck Surgery, Hacettepe University Faculty of Medicine, Ankara, Turkey
Phone: +90 312 305 14 30
E-mail: drkuscu@gmail.com
Received Date: 28.01.2014

Accepted Date: 05.05.2014

© Copyright 2014 by Official Journal of the Turkish Society of Otorhinolaryngology and Head and Neck Surgery Available online at

www.turkarchotolaryngol.net

DOI:10.5152/tao.2014.417

lems, or auricular atresia or patients or their parents who were diagnosed with psychiatric problems. We evaluated 27 male and 27 female patients for the clinical outcomes, revision needs, elastic headband wearing time, and complications, such as infection and hematoma, after otoplasty for surgical correction of prominent ears when Furnas suture was used. Photographic documentation was done preoperatively and postoperatively.

Surgical Techniques

Otoplasty was performed under general anesthesia. The operative site was prepared with povidone-iodine solution. To reduce the bleeding, 1% lidocaine with 1:200.000 epinephrine was infiltrated with a fine needle to postauricular subcutaneous tissue. The position of the antihelix was arranged by pressing the ear backward. The key markings of folds and suture sites were plotted with a violet marker. The skin incision was made postauricularly and long enough for accessing the posterior helix (Mustarde suture) and mastoid area (Furnas suture). Hemostasis was obtained with mono- and bipolar cautery. Small elliptical skin with subcutaneous tissue was excised from the posterior part of the concha. Subcutaneous tissue was separated from the conchal cartilage. The formation of a new antihelical fold was created according to the Mustarde technique. A row of horizontal mattress sutures was centered along the long axis of the root and superior crus of the antihelix. Each suture brought the cartilage of the scapha near to the concha. When tightened, they created or augmented the roll of the crest of the antihelix by drawing the scaphoid fossa towards the concha. The lowermost Mustarde suture was placed from the cauda helicis to the concha, and the uppermost suture was from the concha to the triangular fossa. These sutures were performed with 4/0 white polypropylene (3). Later, if performed, conchal setback procedure was applied to the Furnas technique. The posterior edge of the incision was elevated from the mastoid fascia. The postauricular soft tissue was dissected to expose the mastoid fascia. Furnas suture was applied as a 2/0 polypropylene mattress suture. After careful hemostasis, the skin was closed with 5/0 Ethilon suture (4). A "mastoid" head wrap was wrapped to all patients postoperatively. The dressing was opened on the first postoperative day; if there was no hematoma, it would not be wrapped again. The patient was instructed to wear an on-ear elastic headband after surgery for a week.

Statistical Analysis

All data were analyzed using the Statistical Package for the Social Sciences (SPSS) 15.0. The following statistics were used: t-test, homogeneity of variance (Levene) test, Mann-Whitney U-test, Fisher's chi-square test, simple correlation, and regression analysis method.

Results

A total of 54 patients (95 ears) were detected retrospectively after otoplasty. Twenty-seven (50%) of them were male and 27 (50%) were female. The patient age range was 5-46. Twenty-one patients (40 ears) were children and 33 (55 ears) were adults.

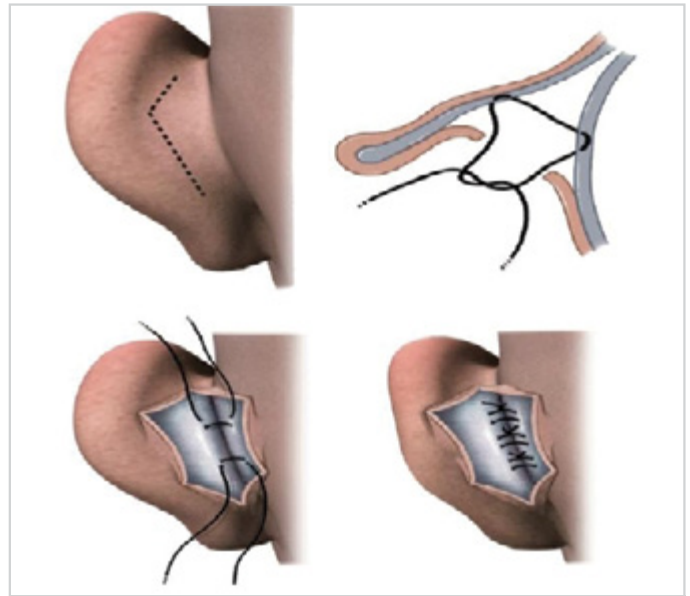


Figure 1. Furnas (setback) suture application

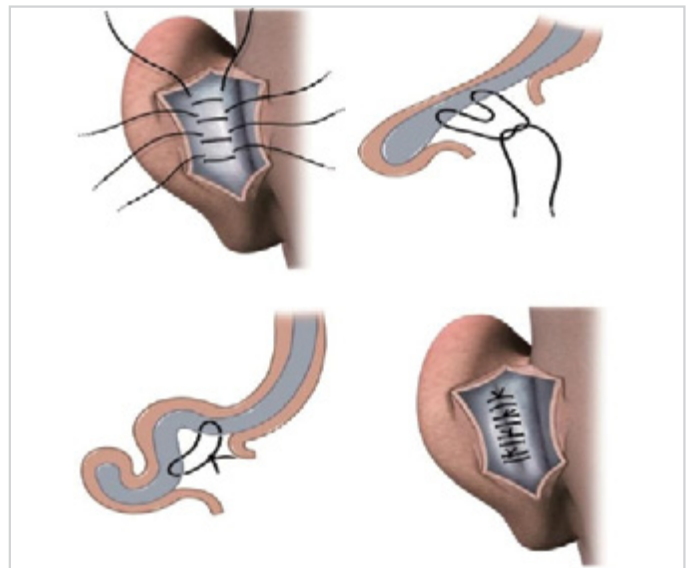


Figure 2. Mustarde suture application

Primary surgery was performed on 95 ears of 54 patients (41 of the patients had bilateral surgery and 13 had unilateral). Five patients (9%) needed revision surgery due to inadequate correction (Table 1). In 7 (13%) patients with an isolated absence of the antihelix, only Mustarde suture was performed (Figure 3). Both Furnas and Mustarde sutures were used in 47 (87%) of patients-41 bilaterally (Figures 4a, b). While using the Mustarde and Furnas suture, all patients underwent the same procedure described above (Table 2).

The minor complication rate of our cases that did not require any additional surgical intervention was found to be 12.6% (12/95). These minor complications included minimal low-flow bleeding for 1 day despite pressure headwrap and bandages in three ears of two patients (3.9%). Four ears of four patients had a hematoma (4.2%); 50 of them did not (95.8%). All hematomas

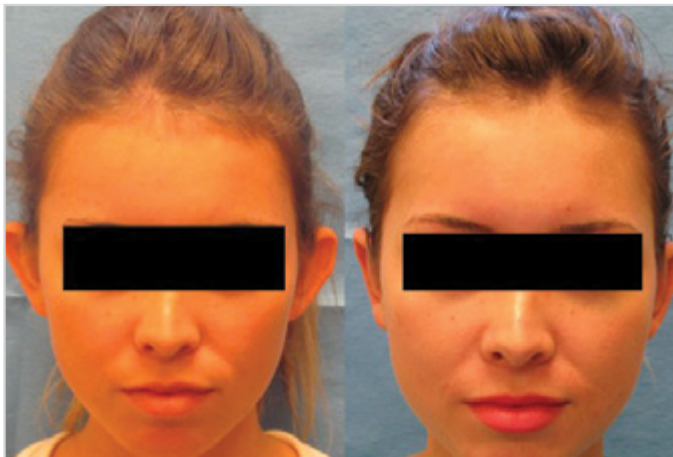

Figure 3. A patient with prominent ear, before and after surgical intervention. In the surgical operation, only Mustarde suture was used

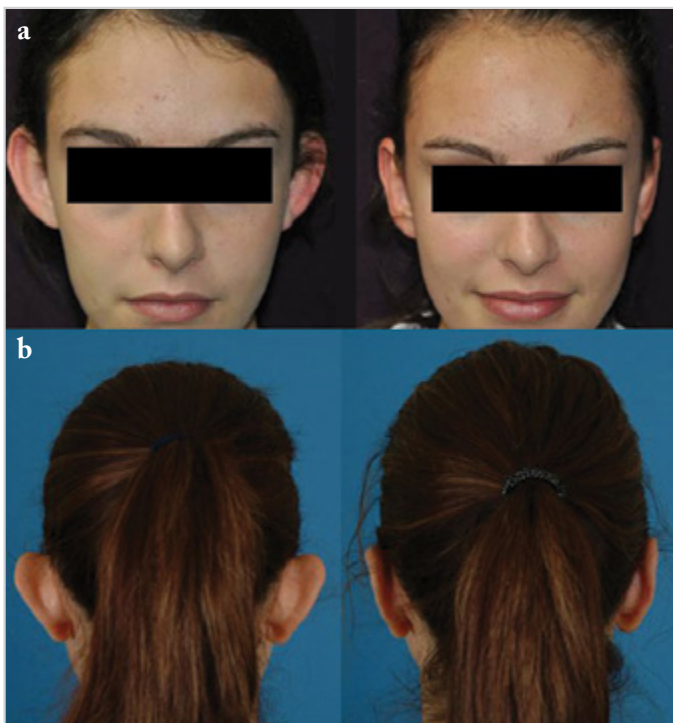

Figure 4 a, b. The front view of a patient with prominent ear, before and after surgical intervention. In the surgical operation, Mustarde+setback suture was used. The posterior view of the same patient with prominent ear, before and after surgical intervention. In the surgical operation, Mustarde+setback suture was used

were observed in patients with Furnas sutures. It was treated with simple drainage and continuation of the mastoid wrap for 3 days. Two ears of two patients were diagnosed for infection after the hematoma, and they recovered with antibiotic treatment. These patients were followed with a mastoid head wrap for 3 days, and their elastic headband wearing time was 10 days. The rest of the patients were followed with a head wrap for 1 day, and their elastic headband wearing time was 7 days (Table 3).

The shortest duration of follow-up in our cases was 4 months, and the longest was 12 months (mean 6 ± 1 months). Revision

Table 1. Demographic data of patients

Variables	Number of patients (n=54)	Number of affected ears (n=95)
Age		
Child (between 6 and 17)	21	40
Adult (between 18 and...)	33	55
Gender		
Male	27	44
Female	27	51
Affected ear		
Right	8	95
Left	5	95
Bilateral	41	95
Primary surgery	54	95
Revision	5	5

Table 2. Ear anomalies and performed surgical techniques

Variables	Number of patients (n=54)	Number of ear (n=95)	Revision (n=5)
No antihelix			
only Mustard	7	7	0
No antihelix+conchal hypertrophy			
Mustard+Furnas	47	88	5

surgery time was approximately 3 months after the first surgery. None of the patients underwent revision surgery earlier than the first 3 months after the primary surgery.

Complication rates among the Furnas suture-used patients were higher; they were more likely to have hematoma and infection. In total, Furnas suture was performed in 87% of the patients. All the hematomas and infections were observed in patients with Furnas suture, and the total complication rate was 11%. Mastoid head wrap application time was longer in the Furnas suture-used group rather than only the Mustarde suture-applied group. Six percent of the patients with setback suture needed 3 more days with a mastoid head wrap.

Discussion

The most common causes of protrusion of the external ear are an underdeveloped or flat antihelix, an overdeveloped, deep concha, or a combination of these features. The goals of otoplasty should be to create individually normal-appearing auricles by maintaining the angle between the mastoid plane and upper helical rim at less than 40 degrees and a distance from the helical rim to the skull of 15-20 mm and creating symmetry between the two auricles (4). Symmetrical intervention is the most important

Table 3. Complications and follow-up

Variables	Number of patients (n=54)	Number of affected ears (n=95)	Headwrap/Elastic bandage time
Bleeding	2	3	1 day/7 days
Hematoma	4	4	3 days/10 days
Infection	2	2	3 days/10 days
No complications	46	86	1 day/7 days

part of surgery. It should be related with experience. Crysdale in 1994 and Messner in 1996 based their measurements on the Frankfort horizontal line, the line from the infraorbital rim to the superior aspect of the external auditory meatus (5, 6). We used the same technical measurement points in our patients in this article. The first measurement point is from the most superior point on the auricle to the skin of the scalp. The Frankfort horizontal line is then projected onto the lateral aspect of the helix for the next reference point. Parallel to the Frankfort line, a third point is marked at the level of the superior point of insertion of the auricle to the scalp on the helix, and the fourth point is marked at the lowest point of the conchal bowl on the helical rim (6). These measurements are generally 25-35 mm preoperatively (6, 7). After the measurements, to solve the absence of the antihelix, we basically used the Mustarde suture technique and aimed to make these measurements: 13-15 mm postoperatively.

Numerous surgical techniques have been developed to correct prominent ear deformity, and the most well known of these techniques can be summarized as otoplasty by cartilage incision (Luckett), concha fossa (Mustarde) sutures, concha mastoid (Furnas) sutures, fossa fascia sutures, the cartilage resection method (Converse and Farnier techniques), isolated cartilage shaving technique, full-layer conchal cartilage shaving technique, full-layer conchal cartilage extraction, and reconstruction of the ear lobule (Webster) (8). Making a detailed examination can be helpful to determine which technique to choose, by understanding the reason for the deformity. When summarizing otoplasty techniques, they can be divided into two main groups: cartilage-sparing and cartilage-cutting.

In cartilage-cutting procedures, they involve reconstructing an antihelix with its cartilaginous curvature by incising the outlines of the antihelix, folding it back, and tubing it upon itself with buried sutures and/or correcting the excessive cupping of the concha by excising a strip of conchal cartilage via a dorsal excision of an ellipse of skin (9). Cartilage-cutting techniques are most appropriate for stiff, thick cartilage that requires a break in its inherent elastic spring to maintain results. With any cartilage cutting techniques, there is the risk of creating visible contour irregularities and sharp edges and scar hypertrophies that may limit the aesthetic acceptability of the results (9, 10) So, the general impression in the literature is that these techniques result in "unnatural" ears (11). We did not use any cartilage-cutting

or -scoring technique, because it is irreversible and has been reported to have high rates of edema, bleeding, and sharp edge formation but low success rates in the literature (12). Because of this reason, in our clinic, we prefer cartilage-sparing techniques.

Cartilage-sparing techniques are mostly aimed at creating an antihelix and correcting concha protrusion and lobule (13, 14). Furthermore, there are two main suture techniques: Mustarde and Furnas. The most common deformity seen in prominent ears is the absence of the antihelix (15). The Mustarde suture technique is used in cases where the antihelix is underdeveloped or not developed, and a new antihelix is formed (16). We used the Mustarde suture technique on 100% of the ears with isolated or no antihelix. In case of the coexistence of the absence of the antihelix and conchal hypertrophy, we used combined suture techniques (Mustarde and Furnas techniques) on 87% of the ears.

This study also found that 21% had unwanted results, such as hematoma, infection, and situations requiring revision. Infection rate was 4%, hematoma was seen 7% of patients, and 10% of patients needed revision. We needed revision surgery, due to unwanted aesthetic results (inadequate correction). None of the revision cases was due to hematoma or infection. For one of the revision cases, we performed a setback suture on the second operation. In other revision cases, we performed Mustarde sutures again, with different intensity. Our clinical outcomes were evaluated to be any difference when comparing the two suture techniques. According to the literature, after otoplasty, early complications are hematoma, bleeding, infection, skin necrosis, and wound dehiscence; late complications are suture extrusion, scarring, hypersensitivity, asymmetry, and unwanted aesthetic results. The cumulative incidence of early complications was low and varied from 0% to 8.4% in the literature (17).

Three major complications can be seen, such as chondritis, inadequate correction, and hematoma, when otoplasty is performed. The most important complication is chondritis, and the most common is inadequate correction. Hematoma is a complication that can be recognized easily, even on the first postoperative visit; a simple drainage and repetitive mastoid headwrap can prevent unwanted consequences. If infection develops, permanent anatomical changes can develop. The emergencies seen after otoplasty are acute infection and hematoma; so, we investigated whether these complications were encountered more when setback suture was used in otoplasty. According to our data, it has more than when both Mustarde and Furnas sutures were performed. It could be related with elevating the skin flap of the mastoid tip for the Furnas suture. Mastoid headwrap wearing time was longer because of hematoma in patients with setback sutures. If complications arise using setback, mastoid headwrap time would be longer than when the Furnas suture is used. Elevating the skin flap when performing setback suture could trigger a hematoma; so, as the treatment option of that complication, a mastoid headwrap would be used for a prolonged time.

We used these two suture techniques according to the deformity in our patients, and there was 91% success in the primary surgery and our revision rate was 9%. Patients were generally satisfied with the results in terms of shape and symmetry. It seems that using setback sutures has good aesthetic outcomes and is a safe method, and we have seen more complications while using it, but this technique avoids major irreparable complications and has a reproducible final outcome.

Conclusion

The success rates in otoplasty surgery are satisfactory in experienced hands. We had 91% success in the primary surgery (with 5 revision needs) and 100% success in the revision and secondary surgeries, which were accepted as being quite satisfactory. With this surgery, the aims are to ensure symmetry of the ears, avoid resurgery, and decrease patient complaints with lower complication rates. Hematoma and infection were early complications that occurred within hours to days. Fortunately, devastating major complications, such as chondritis, necrosis, and large hematomas, were not seen in our study. Postoperative complications of otoplasty can be related with operation technique. Cartilage-cutting techniques have high complication rates, such as hematoma and inadequate correction, and they are irreversible. Mustarde and Furnas suture techniques are more reliable. In our study, we used a standard approach rather than various techniques and had come to a conclusion that more elevation may cause more complications. In setback-used patients, the complication rate was higher, such as hematoma, infection, and need for revision. In addition, larger studies can help identify shortcomings and allow us to make appropriate modifications.

Ethics Committee Approval: Ethics committee approval was received for this study from the ethics committee of Hacettepe University Faculty of Medicine. (/LUT09/31-4)

Informed Consent: Written informed consent was obtained from the patients who participated in this study.

Peer-review: Externally peer-reviewed.

Author Contributions: Concept - O.K., Ö.Ö.; Design - O.K., Ö.Ö.; Supervision - T.Y., Ö.G.; Funding - O.K., Ö.G.; Materials - Ö.Ö., T.Y.; Data Collection and/or Processing - O.K., Ö.G.; Analysis and/or

Interpretation - T.Y., O.K.; Literature Review - Ö.Ö., Ö.G.; Writing - O.K., Ö.Ö.; Critical Review - T.Y., O.K.; Other - Ö.Ö., O.K.

Conflict of Interest: No conflict of interest was declared by the authors.

Financial Disclosure: The authors declared that this study has received no financial support.

References

1. Maslauskas K, Astrauskas T, Viksraitis S, Samsanavidius D. Comparison of otoplasty outcomes using different types of suture materials. *Int Surg* 2010; 95: 88-93.
2. Connolly A, Bartley J. 'External' Mustarde suture technique in otoplasty. *Clin Otolaryngol Allied Sci* 1998; 23: 97-9. [\[CrossRef\]](#)
3. Furnas DW. Otoplasty for prominent ears. *Clin Plast Surg* 2002; 29: 273-88. [\[CrossRef\]](#)
4. Strychowsky JE, Moitri M, Gupta MK, Sommer DD. Incisionless otoplasty: a retrospective review and outcomes analysis. *Int J Pediatr Otorhinolaryngol* 2013; 77: 1123-7. [\[CrossRef\]](#)
5. Vuyk HD. Cartilage-sparing otoplasty: A review with long-term results. *J Laryngol Otol* 1997; 111: 424-30.
6. Rubino C, Farace F, Figus A, Masia DR. Anterior scoring of the upper helical cartilage as a refinement in aesthetic otoplasty. *Aesthetic Plast Surg* 2005; 29: 88-93. [\[CrossRef\]](#)
7. Perez-Macias, JM. The correction of concha-mastoid angle in otoplasty. *J Plast Reconstr Aesthet Surg* 2008; 61: 229-31. [\[CrossRef\]](#)
8. Scharer SA, Farrior EH, Farrior RT. Retrospective analysis of the Farrior technique for otoplasty. *Arch Facial Plast Surg* 2007; 9: 167-73. [\[CrossRef\]](#)
9. Chim H, Wong MT, Tan YC, Foo CL. Fronding of the caudal helical cartilage in anterior scoring for otoplasty. *Ann Plast Surg* 2007; 58: 231-2. [\[CrossRef\]](#)
10. Naumann A. Otoplasty - techniques, characteristics and risks. *GMS Curr Top Otorhinolaryngol Head Neck Surg* 2007; 6: 38-46.
11. Owsley TG, Biggerstaff TG. Otoplasty complications. *Oral Maxillofac Surg Clin North Am* 2009; 21: 105-18. [\[CrossRef\]](#)
12. Burres S. The anterior-posterior otoplasty. *Arch Otolaryngol Head Neck Surg* 1998; 124: 181-5. [\[CrossRef\]](#)
13. Janis JE, Rohrich RJ, Gutowski KA. Otoplasty. *Plast Reconstr Surg* 2005; 115: 60-72. [\[CrossRef\]](#)
14. Campbell AC. Otoplasty. *Facial Plast Surg* 2005; 21: 310-6. [\[CrossRef\]](#)
15. Stucker FJ, Vora NM, Lian TS. Otoplasty: an analysis of technique over a 33-year period. *Laryngoscope* 2003; 113: 952-6. [\[CrossRef\]](#)
16. Toplu Y, Sapmaz E, Toplu AS, Deliktas H. Otoplasty: results of suturing and scoring techniques. *Eur Arch Otorhinolaryngol* 2014; 271: 1885-9. [\[CrossRef\]](#)
17. Gault D. Commentary on: Complications of otoplasty: a literature review. *J Plast Reconstr Aesthet Surg* 2009; 62: 19-27. [\[CrossRef\]](#)