

## Foreign Body in Frontal Sinus: Case Report

### Case Report

İbrahim Çukurova, Erhan Demirhan, Murat Gümüşsoy, Yusuf Yalçın, O. Gazi Yiğitbaşı

Department of Otolaryngology-Head and Neck Surgery, Ministry of Health in İzmir Training and Research Hospital, İzmir, Turkey

### Abstract

A foreign body in the frontal sinus is extremely rare and most cases are related to maxillo-facial trauma. Sixty eight year-old female patient was admitted to our clinic with left nasal obstruction and left frontal pain. A polypoid mass was detected at the left middle meatus by endoscopic examination. Loss of frontal sinus aeration and soft tissue density, especially at the anterior ethmoid region, were observed in the computed tomography scans. The history of the patient was unremarkable except for

a neurosurgical operation due to a benign frontoparietal tumour in 1998. Fronto-ethmoidectomy was performed with an endoscopic transnasal approach under general anaesthesia. The histopathological examination was reported as "bone-wax". The patient had no problem in the 3<sup>rd</sup> postoperative month. This rare case is presented with clinical and radiological findings and a picture of the foreign body.

**Key Words:** Frontal sinus, endoscopy, foreign bodies

### Introduction

Foreign bodies are quite rarely encountered in the paranasal sinuses. In the literature, intracranial foreign bodies are usually observed in the orbital and frontal sinuses and nasal region (1, 2). Garces and Norris (3) reported that 70% of these foreign bodies usually appeared after maxillofacial traumas and 30% appeared during or after dental procedures of maxilla. Foreign bodies are less common in the frontal sinus as compared to maxillary sinus. Hemostasis or supporting materials that are used in the intracranial lesions treated via transfrontal craniotomy are also among the causes of foreign bodies of frontal sinus (3, 4). Foreign bodies in paranasal sinuses may sometimes be asymptomatic. The diagnosis is difficult unless they are recognized. Foreign bodies can be detected incidentally during investigation for the complications developed in their localization sites or during routine radiological screenings (5).

Although the number of published articles on this subject is limited, herein, we present a case, who had undergone surgical intervention due to giant arachnoid cyst in the left cranial sylvian sulcus and in which bone wax was detected during surgery performed for complaints due to ethmoido-frontal sinusitis developed 11 years after the first surgery, in the light of literature review.

### Case report

A 68-year-old female patient presented to our clinic in January 2009 with headache over the left eyebrow, which was present for 4-5 months and gradually becoming intense, left nasal obstruction, and intermittent left nasal haemorrhage. Endoscopic examination revealed that the left nasal passage was obstructed with polypoid tissue filling the left medial meatus and extending into the left nasal space. Computed tomography and magnetic resonance imaging revealed aeration loss in the left frontal sinus and signs of nonhomogeneous soft tissue particularly in the anterior ethmoid cells (Figure 1-3).

Medical history of the patient was unremarkable except for the surgery performed in 1998 at neurosurgery clinic for a giant arachnoid cyst in the sylvian fissure of the left frontoparietal lobe. The patient expressed that she had been regularly followed up by neurosurgery clinic and had no complaint until the last months. According to the surgery note, frontal craniotomy was performed after removing skin flap by left coronal incision, the benign tumour in the sylvian fissure region was accessed after dura mater was opened, cyst fenestration surgery was performed, internal tabula of the pneumatized frontal sinus was repaired, and obliterated with bone wax to support the defect that occurred during surgery and to provide hemostasis. The patient was consulted by the neurosurgery department. Result of the surgery was reported to be consistent with full recovery.



#### Address for Correspondence:

Murat Gümüşsoy, Department of Otorhinolaryngology and Head and Neck Surgery, Ministry of Health Tepecik Education and Research Hospital, 35120 İzmir, Turkey  
 Phone: +90 505 424 52 78

E-mail: mgumussoy@hotmail.com

Received Date: 16.02.2010

Accepted Date: 21.07.2010

Available Online Date: 30.10.2013

© Copyright 2013 by Official Journal of the Turkish Society of Otorhinolaryngology and Head and Neck Surgery Available online at [www.turkarchotolaryngol.net](http://www.turkarchotolaryngol.net)  
 doi:10.5152/tao.2013.1301

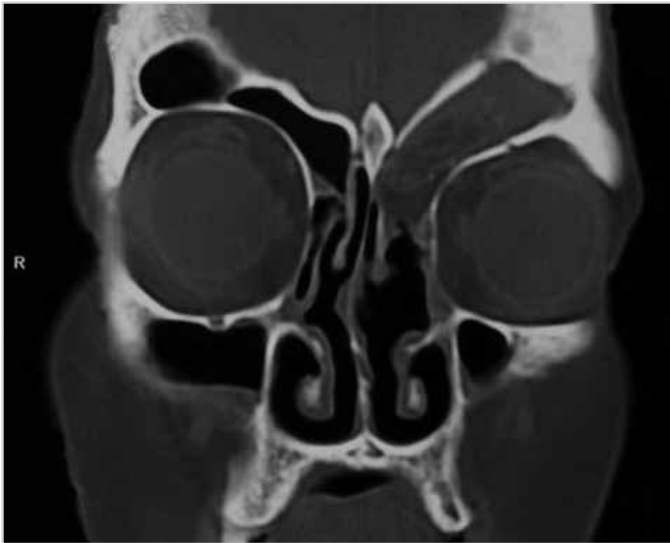

Figure 1. Preoperative coronal plane

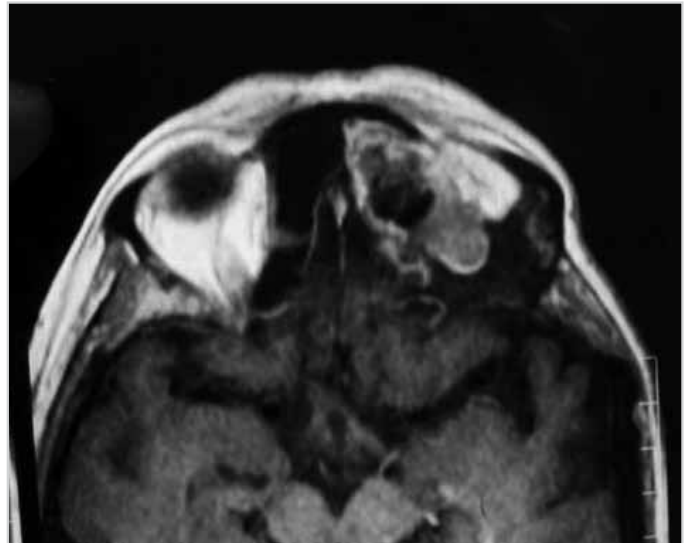


Figure 3. Preoperative axial plane

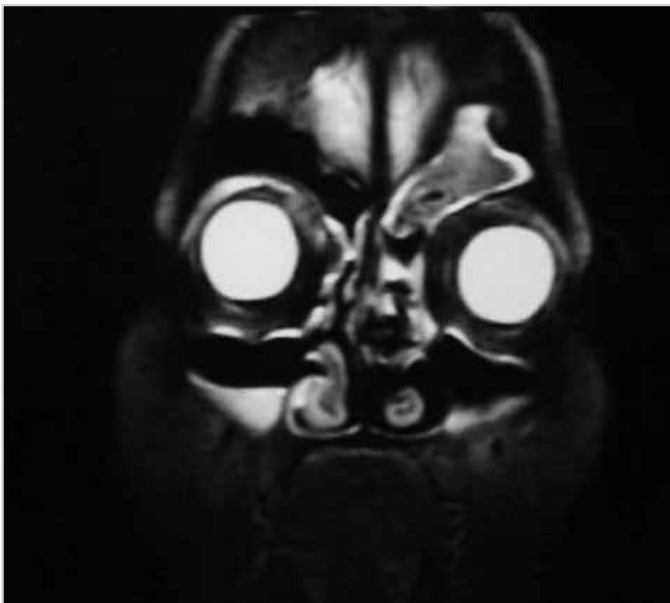


Figure 2. Preoperative coronal plane

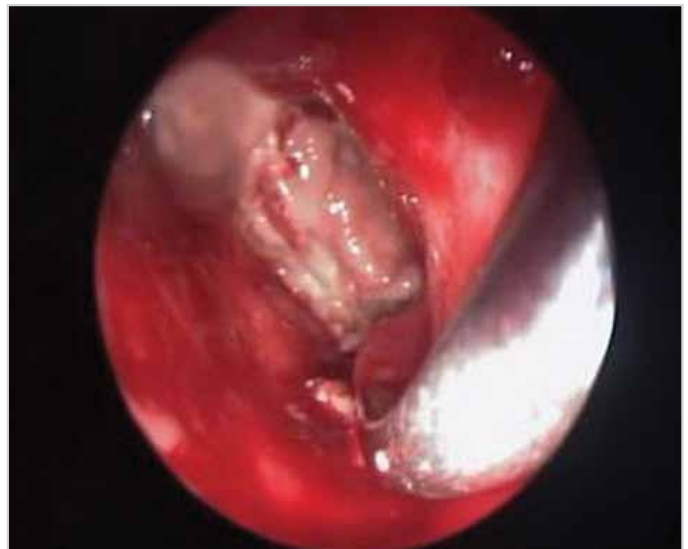

Figure 4. Nasal endoscopic examination revealing bone wax in the left frontal sinus

After routine analysis, the patient was informed about the procedure and her consent was obtained. She underwent left fronto-ethmoidectomy via transnasal endoscopic intervention under general anesthesia. At the beginning of surgical procedure, polypoid tissues in the left medial meatus were removed and a foreign body, which was considered to be the bone wax, was detected hanging down from the frontal recess of left medial meatus. It was observed that the foreign body extended to the frontal sinus and filled a substantial proportion of the sinus (Figure 4).

Entire cavity was cleaned with the help of angled endoscopes. Hemostasis was provided by spongostan support material and the surgery was completed. The foreign body, which was 4x3 cm in size, was referred to the pathology department for histopathological examination (Figure 5).

Pathology results were reported as bone wax and irritative granulation tissue (Ministry of Health Tepecik Training and Research Hospital, Pathology Laboratory, report no; C-1794/2009). Endoscopic and radiological controls on the postoperative 3<sup>rd</sup> month revealed no problem (Figure 6).

#### Discussion

More than 50% of the foreign bodies of paranasal sinuses are found in maxillary sinus. The rate of presence of foreign bodies in other sinuses is almost equal. A great variety of foreign bodies can be found in the paranasal sinuses. These may include wood, cotton, gauze, bullet, shrapnel, glass pieces, and bone wax (1-11). Foreign bodies are encountered much rarer in the frontal sinus. The patients may either be asymptomatic or present with recurrent infections or obstruction symptoms due to nasofrontal canal obstruction. History of surgery performed in neurosurgery

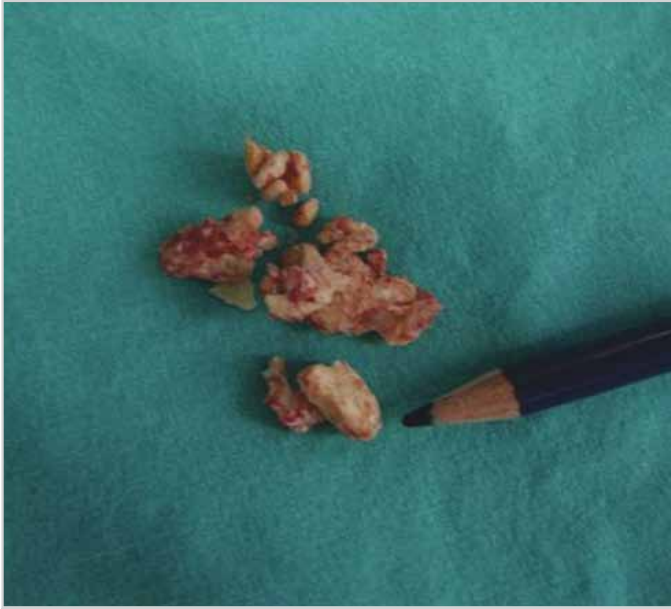

Figure 5. Surgical specimen

department and the method of obstruction with bone wax suggested that there might be a foreign body in our case. Providing hemostasis in bone is an important issue in neurosurgery. In 1892, Sir Victor Horsley defined bone wax method (Horsley Method) to provide regional hemostasis and stability in neurosurgery (12, 13).

We considered that transnasal endoscopic approach was suitable for the present case and performed fronto-ethmoidectomy under general anaesthesia. The soft tissue mass extending from the level of ethmoid bulla to the frontal sinus and completely filling the frontal sinus was totally removed. Polypoid mucosa around the soft tissue mass was excised. No bone defect was detected in the frontal sinus.

Inadequate protection of frontal sinus and bone wax tamponade are suggested among the causes of frontal sinusitis after transfrontal craniotomy (4). It has been reported that frontal abscess and fistulas are more common after the intervention performed by this method. Treatment is the removal of foreign body and providing patency of frontal recess (4). Mann et al. (14) evaluated 39 cases with frontal sinus problems after craniotomy and highlighted that using bone wax after craniotomy and obliterating frontal sinus cavity with muscle were not reliable methods. On the contrary, they covered the frontal sinus space with fascia or galea-periosteal flap and obtained a sinus with good aeration and drainage with an open nasofrontal canal.

### Conclusion

Throughout the literature, in the present case report, we intended to highlight the facilities of approaching to the similar frontal sinus pathologies through nasal way using advanced surgical and imaging instruments during examination and cleaning of both the foreign body and pathological tissue and formations because such an approach is effective, has mini-

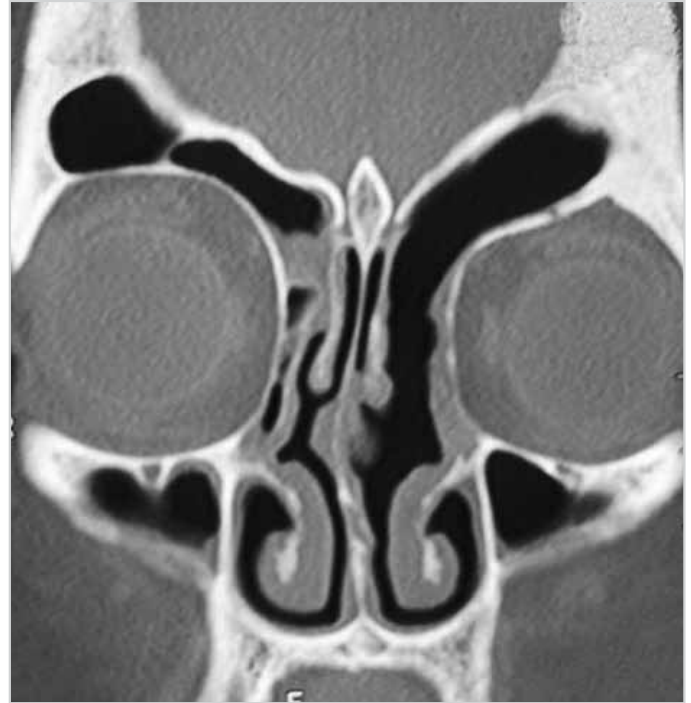

Figure 6. Postoperative 3rd month CT scan

imum morbidity, and does not require external incision as does the external approach.

### Conflict of Interest

No conflict of interest was declared by the authors.

**Peer-review:** Externally peer-reviewed.

**Informed Consent:** Written informed consent was obtained from patients who participated in this case.

### Author Contributions

Concept - İ.Ç.; Design - E.D.; Supervision - M.G.; Materials - Y.Y.; Literature Review - O.G.Y.; Writer - M.G.

### Kaynaklar

1. Jooma R, Bradshaw JR, Coakham HB. Computed tomography in penetrating cranial injury by a wooden foreign body. *Surg Neurol* 1984; 21: 236-8. [\[CrossRef\]](#)
2. Markham JW, McCleave DE, Lyngne HN. Penetrating craniocerebral injuries: report of two unusual cases. *J Neurosurg* 1964; 21: 1095-7. [\[CrossRef\]](#)
3. Garces SM, Norris CW. Unusual frontal sinus foreign body. *J Laryngol Otol* 1972; 86: 1265-8. [\[CrossRef\]](#)
4. Li SH, Shi HJ, Dong WD, Zou LG, Wu DH. Frontal sinusitis after transfrontal craniotomy: causes and management. *Zhonghua Er Bi Yan Hou Tou Jing Wai Ke Za Zhi* 2008; 43: 263-7.
5. Onerci M, Ogretmenoglu O, Yilmaz T. Glass in the frontal sinus: report of three cases. *J Laryngol Otol* 1997; 111: 156-8. [\[CrossRef\]](#)
6. Payne RF. Foreign bodies in the frontal sinus. *Br J Radiol* 1967; 40: 778-80. [\[CrossRef\]](#)

7. Tosun F, Ozkaptan Y. Practical approach to foreign bodies in the frontal sinus. *Otolaryngol Head Neck Surg* 2000; 122: 928-9. [\[CrossRef\]](#)
8. Hara A, Kusakari J, Shinohara A, Yamada Y, Sato N. Intrusion of an incisor tooth into the contralateral frontal sinus following trauma. *J Laryngol Otol* 1993; 107: 240-1. [\[CrossRef\]](#)
9. Kaplan AS, Green JD Jr, McCaffrey TV. Unsuspected foreign body in the frontal sinus and anterior cranial fossa. *Ann Emerg Med* 1989; 18: 988-90. [\[CrossRef\]](#)
10. Lancer JM. Glass in the frontal sinus. *J Laryngol Otol* 1982; 96: 357-60. [\[CrossRef\]](#)
11. Aydın S, Şanlı A, Eken M, Hardal Ü. Glass Particles in the Frontal Sinus Case Report. *Turk J Med Sci* 2009; 39: 313-5.
12. Hadeishi H, Yasui N, Suzuki A. Mastoid canal and migrated bone wax in the sigmoid sinus: technical report. *Neurosurgery* 1995; 36: 1220-4. [\[CrossRef\]](#)
13. Gaurav G, Charles JP. From sealing wax to bone wax: predecessors to Horsley's development. *Neurosurg Focus* 2007; 23: 16.
14. Mann W, Riechelmann H, Glisbach J. The state of the frontal sinus after craniotomy. *Acta Neurochir (Wien)* 1998; 100: 101-3. [\[CrossRef\]](#)