

OLGU BİLDİRİSİ / CASE REPORT

An unusual variant of laryngeal squamous cell carcinoma: condylomatous carcinoma

G. Özbilen Acar, M. Toprak, B. Öz, S. Uyar Bozkurt

Larengeal skuamöz hücreli karsinomun sıradışı bir formu: Kondilomatöz karsinom

Skuamöz hücreli karsinom larenkste lokalize olan malign tümörlerin en sık görülen histopatolojik tipidir. Ancak, kondilomatöz karsinom skuamöz hücreli karsinomun değişik bir formudur ve kondilomatöz skuamöz hücreli karsinom konsepti ile larenkste çok ender karşılaşılr. Bu yazıda, larenksinde kondilomatöz skuamöz hücreli karsinom tespit edilen 70 yaşındaki bir hasta sunulmuştur. Bu tümörün karakteristik özellikleri, etyolojik, klinik ve histopatolojik olarak vurgulanmıştır. Ayrıca bu malignensinin verrüköz karsinom ile ayırıcı tanısı üzerinde durulmuş ve bu hastalığa olan tedavi yaklaşımları literatür ışığı altında tartışılmıştır.

Anahtar Sözcükler: Kondilomatöz karsinom, verrüköz karsinom, skuamöz hücreli karsinom, larenks, human papilloma virüs (HPV).

Abstract

Squamous cell carcinoma is the most common histopathological type of malignant tumors in the larynx. However, condylomatous carcinoma is an unusual variant of squamous cell carcinoma, and the concept of condylomatous squamous cell carcinoma is rarely encountered in the larynx. In this article, a 70-year-old patient with condylomatous carcinoma of the larynx is presented. Characteristics of this tumor are emphasized etiologically, clinically, and histopathologically. Additionally, treatment options of this disease are discussed in light of the literature.

Key Words: Condylomatous carcinoma, verrucous carcinoma, squamous cell carcinoma, larynx, human papilloma virus (HPV).

Türk Otolarengoloji Arşivi, 2010; 48(2): 89-93

Turk Arch Otolaryngol, 2010; 48(2): 89-93

Gül Özbilen Acar, MD

Department of Otolaryngology and Head&Neck Surgery, Istanbul Göztepe Training and Research Hospital, Istanbul

Murat Toprak, MD

Department of Otolaryngology and Head&Neck Surgery, Cerrahpaşa Faculty of Medicine, Istanbul University, Istanbul

Buge Öz, MD

Department of Pathology, Cerrahpaşa Faculty of Medicine, Istanbul University, Istanbul

Süheyla Uyar Bozkurt, MD

Department of Pathology, Faculty of Medicine, Marmara University, Istanbul

Introduction

Condylomatous carcinoma is an uncommon and distinct variety of squamous cell carcinoma, and is described as prominent condylomatous changes.¹ Involvement of the larynx rarely occurs in this tumor.

Condylomatous carcinoma of the larynx should be distinguished from verrucous carcinoma that is

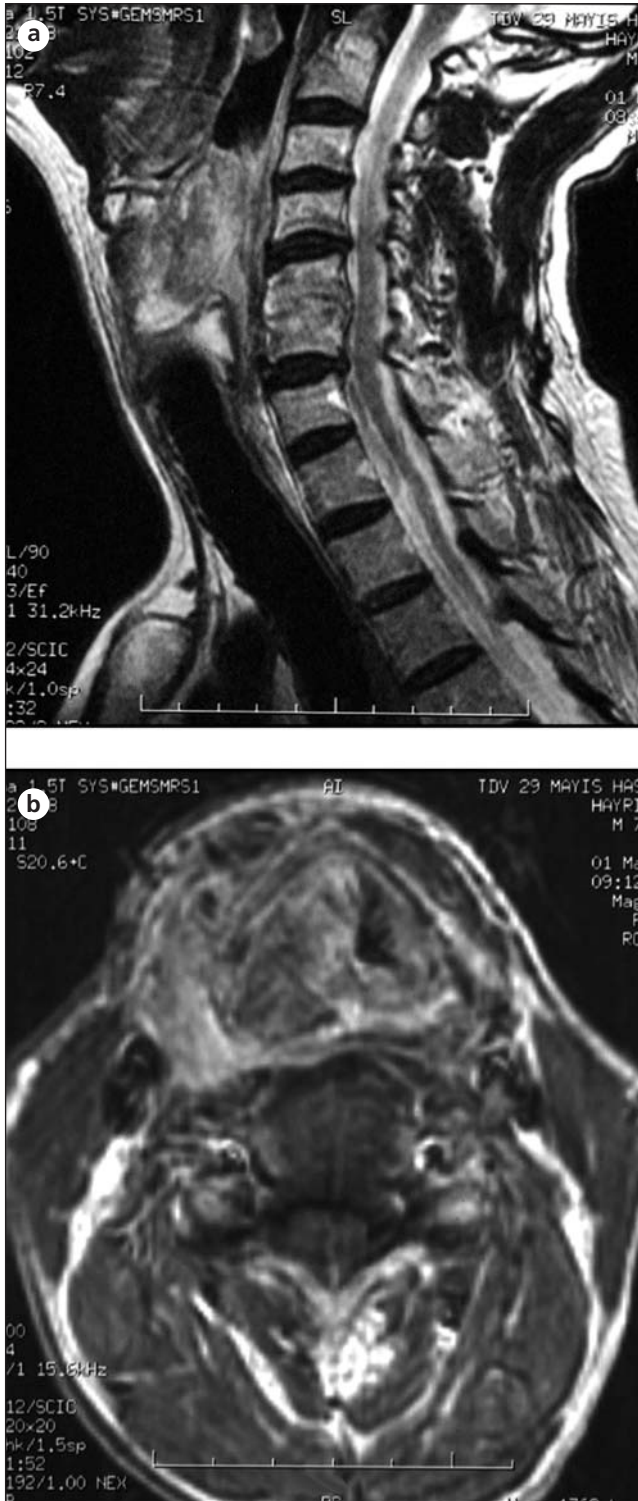

Figure 1. Sagittal (a) and transverse (b), T1 and T2 weighted MRI scans with contrast showed an infiltrative mass which filled up right hypopharynx and larynx.

also a rare laryngeal neoplasm.² Histological evidence indicates that human papilloma virus (HPV) has a critical etiological role in the progression of condylomatous lesion coexisting with laryngeal squamous cell carcinoma.³

In this case report, we focus on the etiological factors, clinical picture, histopathological evaluation, and treatment alternatives of this disease, with special attention to the differentiation of this tumor from verrucous carcinoma.

Case Report

A 70-year-old male applied to our hospital with severe hoarseness, dyspnea and dysphagia for a duration of three months, in May 2006. The patient underwent indirect laryngoscopy. Right pyriform sinuses, right aryepiglottic fold and right vocal band and cord were invaded by lesion. Macroscopically, the tumor was characterized as ulcerative and exophytic. There was no right vocal cord mobility. Subsequently, direct laryngoscopy was planned for biopsy under general anaesthesia. The result of the biopsy revealed in-situ laryngeal squamous cell carcinoma.

In the radiological evaluation, cranial magnetic resonance imaging (MRI) showed an infiltrative mass 6x4x3.5 cm in diameter involving right pyriform sinuses, right aryepiglottic fold, right epiglottic area, right vocal band and cord, additionally with infiltration of right parapharyngeal space, right thyroid cartilage and right strap muscles. Minor lymphadenopathies were detected around right submandibular area (Figure 1).

Total excision of the tumor through total laryngectomy, and right functional neck dissection were performed under general anaesthesia in May 2006. Right submandibular gland and right thyroid gland were also resected.

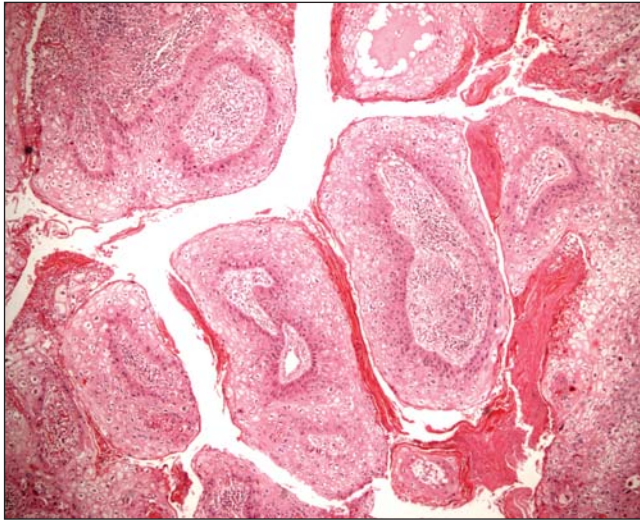


Figure 2. Histopathological evaluation of the specimen indicates papillary growth pattern in tumor (HE x40). [Color figure can be viewed in the online issue, which is available at www.turkarchotolaryngol.org]

Final diagnosis of the histopathological examination showed condylomatous laryngeal carcinoma. Lymphatic invasion was positive in the larynx. The tumor was located as adjacent to the surgical boundary of right pyriform sinuses. The histopathological evaluation of the specimen revealed marked pleomorphism and koilocytotic atypia (Figures 2 and 3). Additionally, the specimen was further investigated with immunohistochemistry for presence of HPV. Immunohistochemistry by using avidin-biotin-immunoperoxidase technique for HPV Ab(3) (Neomarker, clone K1H8), HPV-16 (Neomarker, clone CAMVIR-1) was performed. Neoplastic cells were not stained with HPV Ab(3) and HPV-16. Further evaluation for HPV by polymerized chain reaction (PCR) was failed to detect DNA from paraffin blocks of the tumor. Right neck dissection material showed reactive hyperplasia. No tumor was detected in the submandibular gland and thyroid gland.

A fistula developed in the neck after 10 days postoperatively. Approximately after 3 weeks, total

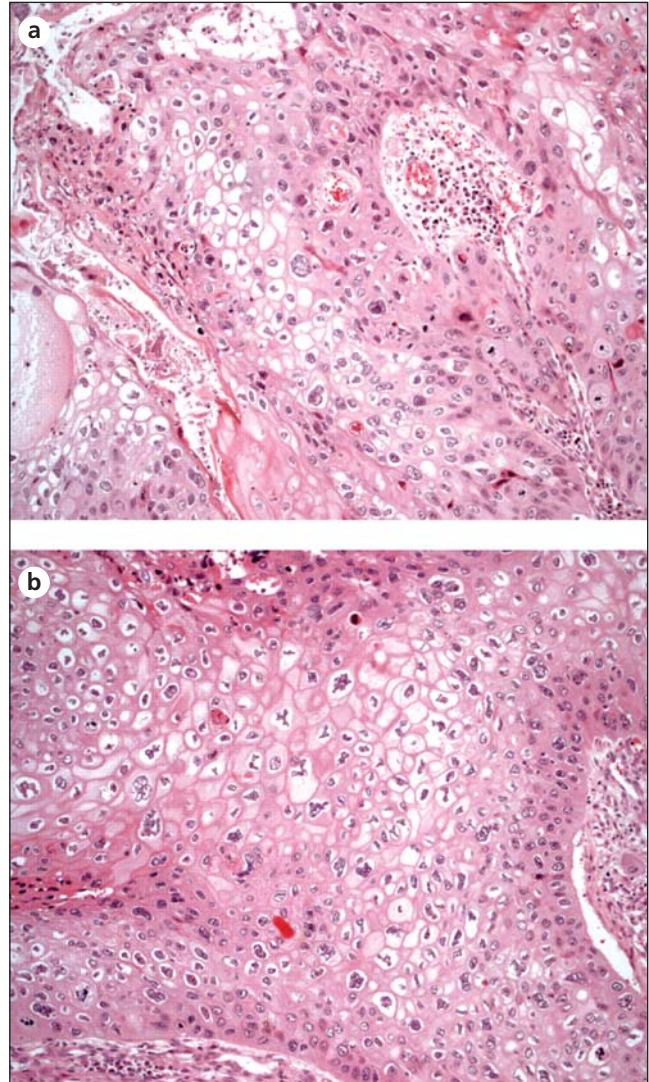


Figure 3. Marked pleomorphism and koilocytotic atypia are demonstrated in the histopathological examination of the specimen in two different microscopic areas (a-b) (HE x200). [Color figure can be viewed in the online issue, which is available at www.turkarchotolaryngol.org]

recovery of the fistula was achieved. The patient was discharged 1 month after operation, with radiation therapy planned. Subsequently, the patient was irradiated on the primary site for 1 month postoperatively. In 3 years and 3 months postoperative follow up, no radiological and clinical signs of recurrence were detected.

Discussion

Condylomatous carcinoma is a seldomly seen variant of squamous cell carcinoma, which may involve the larynx, cervix, vulva, penis and skin.¹⁻⁴ To present date, only two series related to this neoplasm of the larynx have been published by some authors.^{3,4} Our case report is third study about condylomatous carcinoma of the larynx in the literature. The human papilloma virus (HPV) has been reported as etiological agent for development of this tumor.^{3,4} However, in the histopathological evaluation of our case's specimen, positivity was not detected regarding presence of HPV in koilocytotic cells by immunohistochemical study.

Condylomatous carcinoma reveals features of a well-differentiated squamous cell carcinoma at the deep margin. In this tumor, numerous malignant cells have cytoplasmic vacualization and nuclear changes similar to koilocytotic atypia.¹

It is known that condylomatous carcinoma exhibits a more favorable prognosis than well-differentiated squamous cell carcinoma in the cervix and the penis.^{1,2} This tumor is considered to be a low grade malignant tumor.⁵ However, in this case, the lesion was a high grade malignant tumor. Thus, condylomatous carcinoma may have very invasive behaviour in the head and neck localization.

It is crucial that condylomatous carcinoma should be differentiated clinicopathologically from verrucous carcinoma.² Verrucous carcinoma is described as a variety of squamous cell carcinoma involving oral cavity, larynx, esophagus, skin and genital tract.^{1,2,6,7} Histopathologically, condylomatous carcinoma is distinguished from verrucous carcinoma upon presence of long and undulating, condylomatous papillae, with marked fibrovascular cores and a base which is rounded or irregular and

jagged. Moreover, significant and diffuse koilocytotic atypia is observed, whereas this is not present in the verrucous carcinoma.²

Verrucous carcinoma of the larynx has a low grade malignancy and locally invasive character. It appears that surgical therapy is the main treatment for this neoplasm. Radiotherapy is usually not proposed since it may cause anaplastic transformation with metastatic spread. The metastasis of the cervical lymph nodes and other organs is very rare. Thus, the neck dissection is not considered essential.⁸

Conclusion

Macroscopically, it may be difficult to differentiate condylomatous carcinoma from verrucous carcinoma. Condylomatous carcinoma is characterized by marked atypia, pleomorphism and koilocytosis which are not seen in verrucous carcinoma. Accordingly, condylomatous carcinoma is considered to be a low grade malignant tumor in some regions such as cervix, penis. However, this tumor was found very aggressive in our case with larynx localization. Unfortunately, there are not many studies about the natural history, and efficacy of different treatment modalities, such as surgery, radiotherapy or chemotherapy for this tumor in the localization of the larynx. Therefore, we could not present more clinical data about this condition in our article. We believe that further clinical studies are needed to be reported about condylomatous carcinoma of the larynx.

References

1. **Wright TC, Ferenczy A, Kurman RJ.** Carcinoma and other tumors of the cervix. In: Blaustein's pathology of the female genital tract. Kurman RJ, editor. 5th ed. New York: Springer-Verlag; 2002. p. 325-81.
2. **Weedon D.** Tumors of the epidermis. In: Skin pathology. Weedon D, editor. 2nd ed. London: Churchill Livingstone; 2002. p. 753-802.

3. **Syrjanen K, Syrjanen S, Pyrhonen S.** Human papilloma virus (HPV) antigens in lesions of laryngeal squamous cell carcinomas. *ORL J Otorhinolaryngol Relat Spec* 1982; 44: 323-34.
4. **Syrjanen KJ, Surjanen SM.** Histological evidence for the presence of condylomatous epithelial lesions in association with laryngeal squamous cell carcinoma. *ORL J Otorhinolaryngol Relat Spec* 1981; 43: 181-94.
5. **Robboy SJ, Anderson MC, Russel P.** Robboy's pathology of the female reproductive tract. London: Churchill Livingstone; 2002.
6. **McKee PH.** Tumors of the surface epithelium. In: Pathology of the skin with clinical correlation. McKee PH, editor. 2nd ed. St. Louis: Mosby-Wolfe; 1996. p. 14.1-14.40.
7. **Kirkham N.** Tumors and cysts of the epidermis. In: Lever's histopathology of the skin. Elder DE, editor. 9th ed. Philadelphia: Lippincott Williams&Wilkins; 2005. p. 836-49.
8. **Ferlito A, Recher G.** Ackerman's tumor (verrucous carcinoma) of the larynx: a clinicopathologic study of 77 cases. *Cancer* 1980; 1: 1617-30.

Conflict of interest statement:

No conflicts declared.

Correspondence: Gül Özbilten Acar, MD

Ata 3/4 D:29 Sedef Cad. 3. Ada

Kadıköy 34750 İSTANBUL

GSM: +90 532 266 90 23

Fax: +90 216 414 34 08

e-mail: gulozbiltenacar@gmail.com