

OLGU BİLDİRİSİ / CASE REPORT

Congenital stapes fixation with uncommon middle ear defects: a case report

H. Emir, Z.K. Kaptan, Ü. Bayız, H. Uzunkulaoglu

Nadir orta kulak defektleriyle birlikte konjenital stapes fiksasyonu: Olgu sunumu

Konjenital kulak anomalileri, sporadik olabildikleri gibi birinci ya da ikinci brankial ark kaynaklı bir sendromun parçası da olabilirler. Konjenital stapes taban fiksasyonunun diğer konjenital kemikçik defektleri ya da orta kulak anomalileri ile birlikte olması da çok nadir görülen bir durumdur. Bu makalede, kliniğimize, sol kulakta 2 yaşından itibaren ortaya çıkan, ilerleyici özellikte olmayan, işitme kaybı şikayeti ile başvuran 10 yaşında bir kız çocuğu bildirilmiştir. Eksploratif timpanotomi uygulandığında, patolojinin esas olarak stapes taban fiksasyonu ile birlikte stapedial tendon yokluğu ve defektli inkus uzun kolu olduğu görüldü. Literatür tarandığında bizim olgumuzun, aynı anda birçok farklı anomalinin birlikte bulunduğu tek ve nadir bir olgu olduğu görülmektedir.

Anahtar Sözcükler: Konjenital, orta kulak anomalisi, stapedial tendon, stapes taban fiksasyonu, inkus defekti.

Abstract

The presence of congenital stapes footplate fixation with other congenital ossicular defects or middle ear anomalies is a rare condition. Anomaly can be sporadic or a part of a syndrome originated from first or second branchial arch. Here we report a case of 10 years old female patient who appealed to our clinic with the complaint of non-progressive hearing loss from 2 years of age at her left ear. When an exploratory tympanotomy was performed, stapes footplate fixation with absent stapedial tendon and defective long process of incus was the pathology. When literature was evaluated, it was realized that this is a unique case who has these kinds of multiple abnormalities at the same time.

Key Words: Congenital, middle ear anomaly, stapedial tendon, stapes footplate fixation, incus defect.

Türk Otolarengoloji Arşivi, 2010; 48(1): 47-50

Turk Arch Otolaryngol, 2010; 48(1): 47-50

Introduction

Congenital middle ear anomalies are rare, sporadic and generally non-familial.¹ They may have other congenital abnormalities and can also appear as a part of other syndromes. The origin of these anomalies are usually first or second branchial arch.^{1,2}

In addition, syndromes like cervico-oculo-acoustic, Pfeiffer, branchio-oto-renal or Kleippel-Feil can also be the resource of these anomalies.^{1,2}

We investigated the literature in detail and found out that our case is unique. We could not find another case who had stapes footplate fixation with absent stapes muscle tendon and defective long process of incus at the same time.

Case Report

On November 2007, a 10 years old female patient presented to us with a hearing loss at her left ear. Her hearing loss had been noticeable since the age of 2. There was not a history of trauma and episodes of chronic otitis media and also there was no history of familial otological abnormalities.

On her otorhinolaryngological examination, she had normal tympanic membranes. Tuning fork tests revealed a conductive hearing loss on the left ear with a mixed hearing loss in pure tone audiogram (bone threshold 26 dB, air threshold 81 dB). On her right ear, hearing was normal. Speech discrimination scores were 75% on the left and 100% on the right ear. Impedence audiometry revealed increased compliance in left ear with normal middle ear pressure. High-resolution temporal bone computed tomography revealed a defect in long process of incus with normal mastoid air cells.

We performed exploratory tympanotomy to the left ear of the patient on December 2007 under general anaesthesia. It was realised that long process of incus was absent as it was seen in CT with the absence of stapedius tendon and eminentia pyramidarum. During the operation, otosclerotic focus was not realised. All these findings suggested us the diagnosis of congenital stapes footplate fixation.

As there was an increased compliance in impedance audiometry and an incus long process defect in CT preoperatively, the diagnosis of stapes footplate fixation was made intraoperatively. We termi-

nated the surgery without performing stapedotomy and hearing reconstruction as her family decided to wait until she can make her own decisions.

Discussion

Congenital ossicular anomalies are very rare and the incidence is less than 1/15000 births.³ Generally cases have non-progressive conductive hearing loss with no history of recurrent ear infections. Otosopic findings are normal in these patients. Investigations like impedance audiometry, audiogram or high resolution CT are usually not enough to reach an accurate diagnosis.⁴ Our case had normal tympanic membranes with non-progressive mixed hearing loss, increased compliance in impedance audiometry and defect at the long process of the incus in CT. Although with these findings ossicular defect was diagnosed preoperatively; stapes footplate fixation with the other anomalies of, absent stapedia tendon and eminentia pyramidarum in exploratory tympanotomy, final diagnosis was congenital stapes footplate fixation. In postoperative multislice CT scan we had the chance to display the absence of eminentia pyramidarum at the left side (Figure 1).

Congenital anomalies of ear can be divided into major and minor anomalies.⁵ While major anomalies consist of pinna, external ear canal, tympanic cavity abnormalities; we can mention ossicular chain fixations and defects, oval and round window anomalies as minor anomalies.⁵ In our case minor anomalies were identified like stapes footplate fixation, absent stapedia tendon and defective long process of incus. In previous literature there exist no other anomaly like this.

When we evaluate the embryological development of these structures in order to analyze the abnormality in detail, we found two different theories about embryological origin of stapes. In one of these theories, suprastructure and the tympanic part of the footplate develop from second branchial arch

and the vestibular part of footplate from otic capsule.⁵ Otic capsule can differentiate to lamina stapedialis which gives rise to annular ligament that enables the stapes to be mobile. If this fails, stapes footplate will fixate. According to this theory, our case have both first and second branchial arch anomalies at the same time. In another theory, stapedia draft develop from cranial tip of second branchial arch and stapedia tendon can arise from interhyale at the second arch. Stapedia footplate can alter from superior part and suprastructure from inferior part of this stapes draft. This seems that otic capsule have no effect on stapes footplate development.⁶ The footplate of stapes, stapedia muscle and its tendon and long process of incus have the same embriological origin and they are all parts of second branchial arch.⁷ If we accept this theory, in our case the occurrence of all defects can be explained on the same embriological process.

The stapedotomy in congenital stapes footplate fixation is still a controversy in literature as the results are different and usually worse than otosclerosis. In addition, complications like SNHL and perilymphatic gusher can be seen more frequently in congenital stapes fixation group than otosclerosis.⁸

Especially in children the reason for not preferring stapedectomy are concomitant otitis media, increased risk of SNHL and the unexpected hearing results compared to otosclerosis. As most of the children are prone to otitis media they are not operated till their tubal disfunction improve.⁹ Dornhoffer et al.¹⁰ stated that preoperative SNHL in congenital stapes footplate fixation can demonstrate an otic capsule anomaly and the manipulation of footplate increase the risk of gusher or SNHL.¹⁰

In unilateral congenital stapes footplate fixation, stapedotomy can be performed when the child can make her or his own decision about surgery.¹¹ In our case we also did not perform stapedotomy as her family decided to wait because of the possible complications.

To reveal the correct diagnosis in congenital stapes footplate fixation one have to evaluate the pre and intraoperative findings carefully. In children, especially if a congenital anomaly is suspected, thin multislice CT scan is necessary in order to evaluate the other congenital ear abnormalities. Hearing results with stapedectomy are usually good in congenital stapes fixation but complications must be kept in mind.

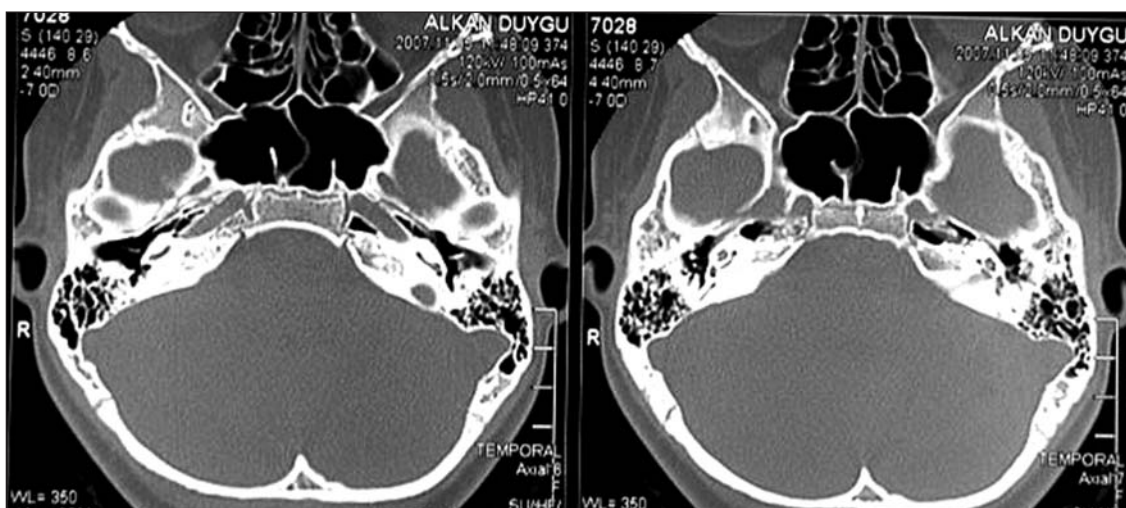


Figure 1. The absence of eminencia pyramidarum on the left side.

References

1. **Teunissen B, Cremers WR, Huygen PL, Pouwels TP.** Isolated congenital stapes ankylosis: surgical results in 32 ears and a review of the literature. *Laryngoscope* 1990; 100: 1331-6.
2. **Makowski A, Makowska-Piontek A.** Stapedectomy in children. *Central Eastern European Journal of Otolaryngology and Head & Neck Surgery* 2000; 5: 14-8.
3. **Farrior JB.** Surgical management of congenital conductive deafness. *South Med J* 1987; 80: 450-3.
4. **Raveh E, Hu W, Papsin BC, Forte V.** Congenital conductive hearing loss. *J Laryngol Otol* 2002; 116: 92-6.
5. **Nandapalan V, Tos M.** Isolated congenital stapes suprastructure fixation. *J Laryngol Otol* 1999; 113: 798-802.
6. **Rodríguez-Vázquez JF.** Development of the stapes and associated structures in human embryos. *J Anat* 2005; 207: 165-73.
7. **Bellucci RJ.** Congenital aural malformations: diagnosis and treatment. *Otolaryngol Clin North Am* 1981; 14: 95-124.
8. **Welling DB, Merrell JA, Merz M, Dodson EE.** Predictive factors in pediatric stapedectomy. *Laryngoscope* 2003; 113: 1515-9.
9. **Massey BL, Hillman TA, Shelton C.** Stapedectomy in congenital stapes fixation: are hearing outcomes poorer? *Otolaryngol Head Neck Surg* 2006; 134: 816-8.
10. **Dornhoffer JL, Helms J, Hoehmann DH.** Stapedectomy for congenital fixation of the stapes. *Am J Otol* 1995; 16: 382-6.
11. **De la Cruz A, Angeli S, Slattery WH.** Stapedectomy in children. *Otolaryngol Head Neck Surg* 1999; 120: 487-92.

Conflict of interest statement:

No conflicts declared.

Correspondence: Hatice Emir, MD

Turan Güneş Bulvarı, 43. Sok.
Tuna Cantürk Sitesi 2. Blok No: 15
Oran ANKARA
GSM: +90 533 361 91 34
Fax: +90 312- 428 69 01
e-mail: emir.hatice@gmail.com