

## OLGU BİLDİRİSİ / CASE REPORT

# Vascular leiomyoma of the nasal cavity and the paranasal sinuses

A. Taş, R. Yağız, F. Öz Puyan, M. Koten, A.R. Karasalihoğlu

### Paranasal sinüsler ve nazal kaviteden kaynaklanan vasküler leiomyom

Paranasal sinüslerden ve nazal kaviteden kaynaklanan vasküler leiomyomlu nadir bir olgu sunuyoruz. Leiomyomlar düz kasın bulunduğu herhangi bir yerde olabilen kas kaynaklı selim tümörlerdir. En sıklıkla mide ve uterusda meydana gelir. Burun ve paranasal sinüslerin leiomyomu nadir bir tümördür. Vasküler leiomyomda tedavi cerrahidir.

**Anahtar Sözcükler:** Vasküler leiomyom, nazal kavite, paranasal sinüs neoplazm.

### Abstract

We present a rare case of vascular leiomyoma - developed in a 69-year-old man - arising from nasal cavity and paranasal sinuses. Leiomyomas are benign tumors of myogenic origin that may occur wherever smooth muscle is present. They occur most frequently in the stomach and uterus. Leiomyoma of the nose and paranasal sinus is a rare tumor. Treatment of the vascular leiomyoma is surgery.

**Key Words:** Vascular leiomyoma, nasal cavity, paranasal sinus neoplasm.

Türk Otolarengoloji Arşivi, 2008; 46(4): 315-319

Turk Arch Otolaryngol, 2008; 46(4): 315-319

## Introduction

Leiomyomas are benign tumors of myogenic origin that may occur wherever smooth muscle is present. They occur most frequently in the stomach and uterus. Other common localizations are the alimentary tract, skin and subcutaneous tissue.<sup>1,2</sup> Leiomyoma of the nose and paranasal sinus is a rare tumor.<sup>3</sup> There have been only three previously reported cases in the literature of vascular leiomyoma in the paranasal sinus.<sup>4,6</sup> In this study, we present a rare case of vascular leiomyoma develop from nasal cavity and paranasal sinuses. Also we present the clinical and histological features of the case.

Abdullah Taş, MD; Recep Yağız, MD; Muhsin Koten, MD; Ahmet R. Karasalihoğlu, MD  
Department of Otorhinolaryngology & Head and Neck Surgery, Trakya University  
School of Medicine, Edirne

Fulya Öz Puyan, MD  
Department of Pathology, Trakya University School of Medicine, Edirne

## Case Report

### Clinical data

A 69-year-old man was initially seen at the state hospital with several months' history of nasal obstruction and tinnitus. On initial exam, he was noted to have a mass in the right nasal cavity. Biopsy was performed from the mass. After the biopsy markedly bleeding occurred and nasal packing was required. Computed tomography (CT) scan of the paranasal sinuses and nasal cavity showed a solid mass in the nasal cavity, posterior ethmoid sinus, maxillary sinus, and extending into the nasopharynx and sphenoid sinus (Figure 1). The patient was sent to our hospital. After the nasal pacing had been removed, nasal bleeding continued markedly. We performed anterior nasal pacing two times, and we performed ligation of the external carotid artery up to superior thyroid artery under general anesthesia due to the suspicion of a tumor of vascular origin. Pathology was reported vascular leiomyoma. Then, right medial maxillectomy and endoscopic ethmoidectomy was performed under general anesthesia (Figure 2). The patient showed no recurrence after 15 months of follow-up

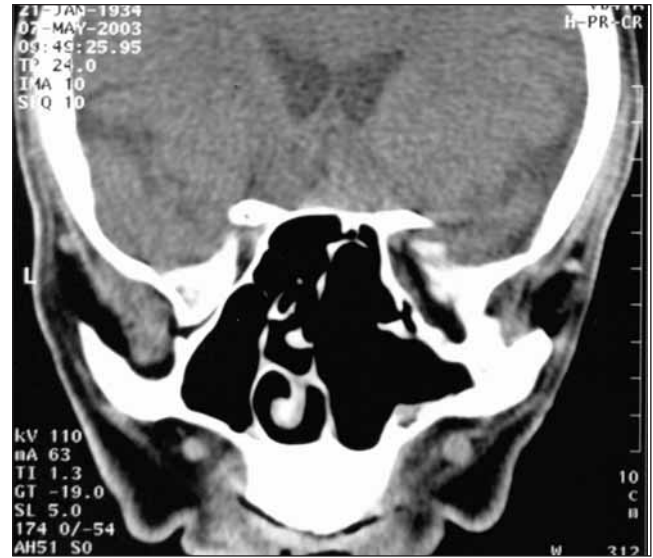

Figure 2. Postoperative coronal CT scan of the nasal and paranasal sinuses.

### Pathologic findings

Resected specimen consisted of a disordered grayish-pink solid tissue measuring 3.5 cm in diameter. On microscopic examination, a mass composed of elongated, blunt shaped, blinded, spindle cells was observed besides the normal edematous

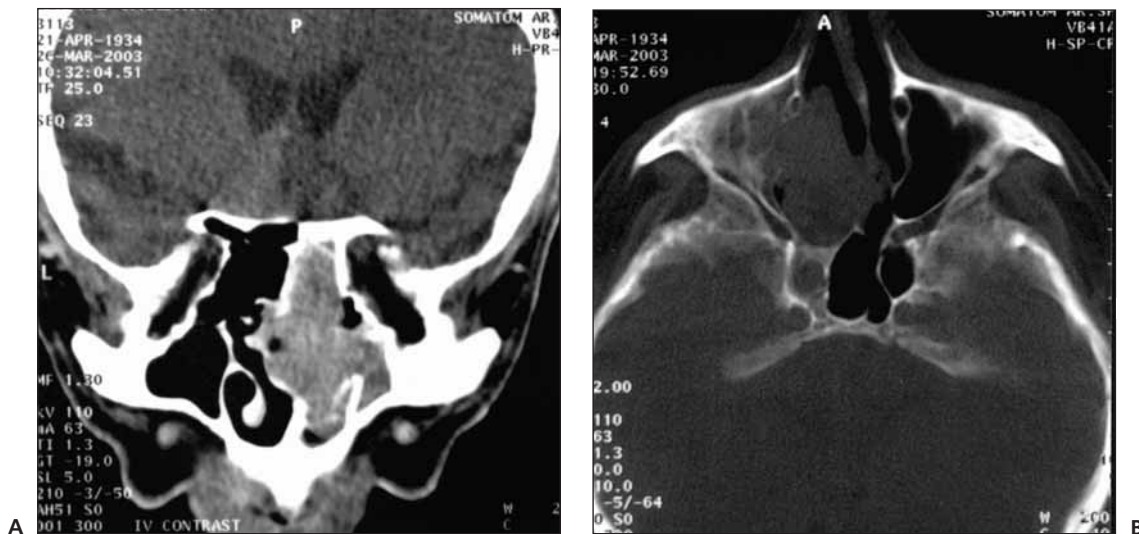
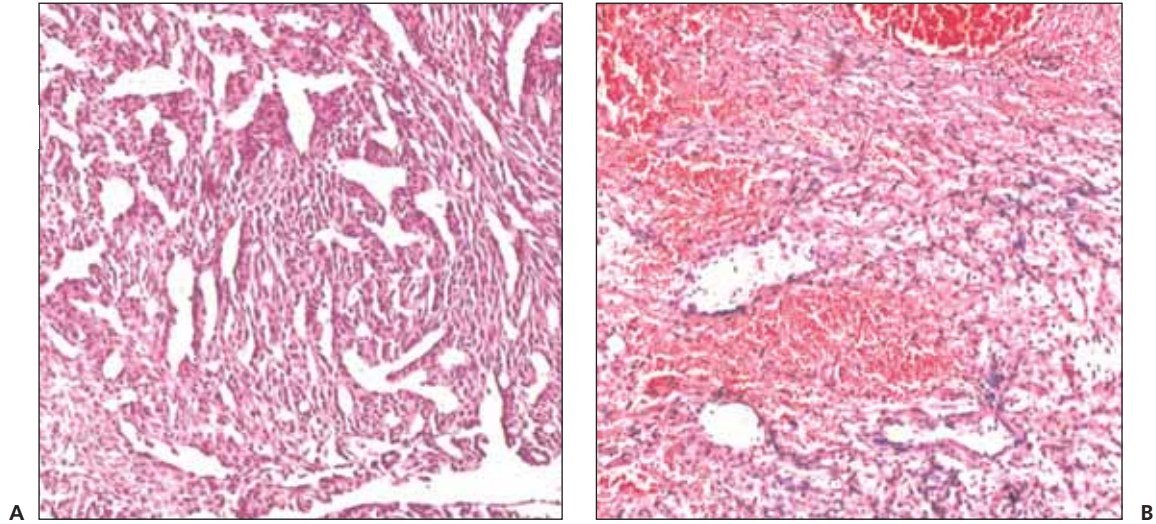


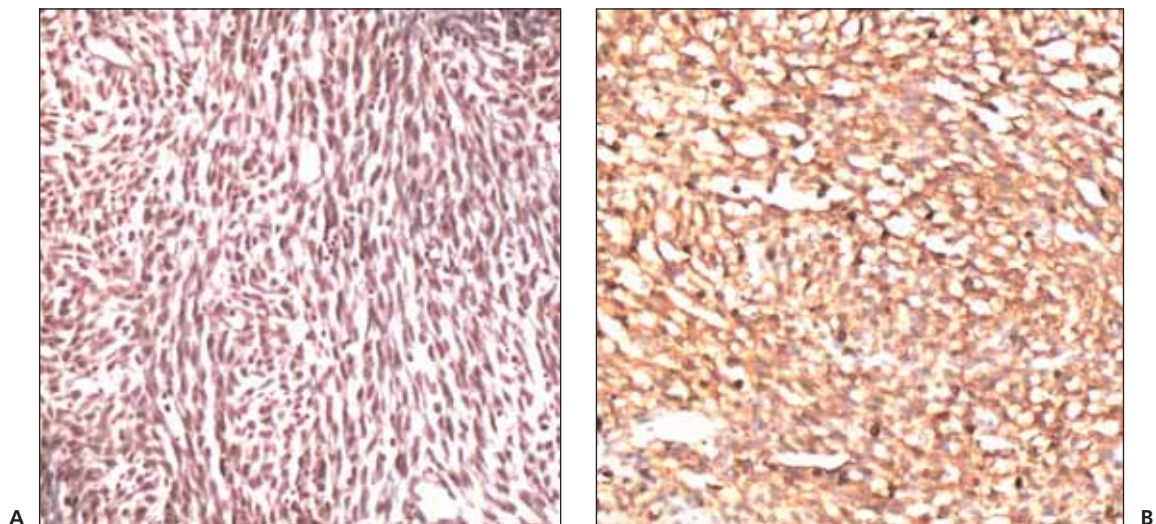
Figure 1. CT scan of the nasal and paranasal sinuses is showing, (A) coronal and (B) axial; tumor filling the right nasal cavity, ethmoid sinus, maxillary sinus and extending nasopharynx. Also there is destruction of the nasal septum.

mucosa. Numerous irregularly dilated blood vessels with hemorrhage were detected inside the tumor (Figure 3). The cellular tumor without of mitosis showed histochemically with Masson's trichrome stain positivity. On immunohistochemical examina-

tion, the tumor cells were positive for SMA and Vimentin, but they were negative for epithelial membrane antigen, cytokeratin and S100 (Figure 4). Endothelial cells of the vascular spaces were stained with factor-VIII and CD-34 antibodies.



**Figure 3.** Leiomyoma composed of cigar shaped elongated spindle cells with intervening vascular channels (A) (HE x12.5), edematous hemorrhagic stroma with dilated vascular structures (B) (HE x50). [Color figure can be viewed in the online issue, which is available at [www.turkarchotolaryngol.org](http://www.turkarchotolaryngol.org)]



**Figure 4.** Bundles of smooth muscle cells showing positive for Masson's trichrom stain (A) (Masson's trichrom x100), note the strong positive cytoplasmic reactivity for  $\alpha$  SMA within the tumor (B) (Immunoperoxidase method for  $\alpha$  SMA antigen x100). [Color figure can be viewed in the online issue, which is available at [www.turkarchotolaryngol.org](http://www.turkarchotolaryngol.org)]

## Discussion

Vascular leiomyomas are uncommon type of leiomyoma and rarely occur in the head and neck area.<sup>7</sup> They are rarely found in the nasal cavity, making up between one and two percent of all nonepithelial tumors of the nasal cavity.<sup>8</sup> Frequently these tumors present as painless polypoid or nodular masses with nasal obstruction, epistaxis or occasionally facial pain.<sup>9</sup> There appears to be a female preponderance.<sup>7</sup> The most common finding in conventional radiographs are opacification of the nasal cavity or sinuses, but CT scan and magnetic resonance imaging (MRI) are better able to delineate the precise extent of tumor involvement.<sup>9</sup> Incidence of leiomyomas from the turbinates is higher than in other locations of the nasal cavity due to the abundant vascular smooth muscle elements present in the turbinates.<sup>10</sup> Leiomyomas can develop from nasal septum,<sup>10-12</sup> inferior turbinate,<sup>1,13</sup> superior turbinate,<sup>7</sup> nasal vestibule,<sup>2,14</sup> nasal floor,<sup>15</sup> choana,<sup>3</sup> nasal cavity.<sup>8</sup> Also there have been only three cases of leiomyoma involving the paranasal sinus in the literature.<sup>4,6</sup> All of them were vascular leiomyoma. To account for the origin of smooth muscle tumors, three explanations have been given; origin from aberrant undifferentiated mesenchyme, origin from smooth muscle elements in the walls of blood vessels, and origin from both sources.<sup>8</sup> The histopathologic differential diagnosis for these lesions includes hemangiomas, nasal angiofibromas, fibromyoma, leiomyoblastoma, angiomyolipoma, and vascular leiomyosarcoma.<sup>7</sup> The vascular channels and immunohistochemically actin positive fascicles of spindle cells without mitosis excluded these differential diagnoses. There are three histological subtypes: solid or capillary, cavernous, and venous. The most common type found in the head and neck area is the venous type.<sup>12,16</sup> Our case was consisting of a mixture of subtypes. There were both cavernous vessels and

venous vascular channels with thick muscular walls. Surgical excision of these benign tumors results in high cure rates.

In conclusion, leiomyomas are benign tumors of myogenic origin. For the diagnosis, CT scan and/or MRI, and angiographic examination should be required. Also pathologic evaluation is necessary for the definite diagnosis. The differential diagnosis is from hemangiomas, nasal angiofibromas, fibromyoma, leiomyoblastoma, angiomyolipoma, and vascular leiomyosarcoma. Surgical excision of the tumor or more extended surgical approach according to tumor dimension should be performed.

## References

1. **Tang SO, Tse CH.** Leiomyoma of the nasal cavity. *J Laryngol Otol* 1988; 102: 831-3.
2. **Lijovetzky G, Zaarura S, Gay I.** Leiomyoma of the nasal cavity. Report of a case. *J Laryngol Otol* 1985; 99: 197-200.
3. **Van Ingen G, Stel HV, Tiwari RM.** Atypical leiomyoma of the choana. *J Laryngol Otol* 1991; 105: 1065-7.
4. **Schwartzman J, Schwartzman J.** Leiomyoma of the paranasal sinuses (case report). *Laryngoscope* 1973; 83: 1856-8.
5. **Zijlker TD, Visser R.** A vascular leiomyoma of the ethmoid. Report of case. *Rhinology* 1989; 27: 129-135.
6. **Harcourt JP, Gallimore AP.** Leiomyoma of the paranasal sinuses. *J Laryngol Otol* 1993; 107: 740-1.
7. **Nall AV, Stringer SP, Baughman RA.** Vascular leiomyoma of the superior turbinate: first reported case. *Head Neck* 1997; 19: 63-7.
8. **Fu YS, Perzin KH.** Non epithelial tumors of the nasal cavity, paranasal sinuses and nasofarenx; a clinicopathologic study. IV. Smooth muscle tumors (leiomyoma, leiomyosarcoma). *Cancer* 1975; 35: 1300-8.
9. **Huang HY, Antonescu CR.** Sinonasal smooth muscle cell tumors. A clinico-pathologic and immunohistochemical analysis of 12 cases with emphasis on the low-grade end of the spectrum. *Arch Pathol Lab Med* 2002; 127: 297-304.
10. **Llorente JL, Suarez C, Seco M, Garcia A.** Leiomyoma of the nasal septum: report of a case and review of the literature. *J Laryngol Otol* 1996; 110: 65-8.
11. **Barr GD, More IAR, McCallum HM.** Leiomyoma of the nasal septum. *J Laryngol Otol* 1990; 104: 891-3.
12. **Osaki M, Osaki M, Kodani I, Adachi H, Shibata I, Ito H.** Vascular leiomyoma of the nasal cavity: Case report and review of the literature. *Yonago Acta Med* 2002; 45: 113-6.

- 13. Hanna GS, Akosa AB, Ali MH.** Vascular leiomyoma of the inferior turbinate- Report of a case and review of the literature. *J Laryngol Otol* 1988; 102: 1159-60.
- 14. Sawada Y.** Angioleiomyoma of the nasal cavity. *J Oral Maxillofac Surg* 1990; 48: 1100-1.
- 15. Ragbeer MS, Stone J.** Vascular leiomyoma of the nasal cavity: - Report of a case and review of literature. *J Oral Maxillofac Surg* 1990; 48: 1113-7.
- 16. Khan MHZ, Jones AS, Haqqani MT.** Angioleiomyoma of the nasal cavity: Report of a case and review of literature. *J Laryngol Otol* 1994; 108: 244-6.

---

**Conflict of interest statement:**

*No conflicts declared.*

**Correspondence: Abdullah Taş, MD**

*Department of Otorhinolaryngology & Head and Neck Surgery,  
Trakya University School of Medicine  
22030 EDİRNE*

*Phone: +90 284 235 76 41 / 1230*

*Fax: +90 284 235 27 30*

*e-mail: abdultas@yahoo.com*