

OLGU BİLDİRİSİ / CASE REPORT

A Kimura disease case with buccal mucosa involvement

S.D. Micozkadıoğlu, C.A. Çağıcı, C. Yılmaz, N. Bal

Bukkal mukoza tutulumlu Kimura hastalığı olgusu

Kimura hastalığı baş boyunu tutan lenfadenopati ve subkütan kitleler ile karakterize, sıklıkla periferik kanda eozinofili ve yüksek serum Ig E düzeyinin eşlik ettiği kronik idiopatik bir hastalıktır. 52 yaşında bayan hasta beş yıldır rekürren ağız boşluğu lezyonları nedeniyle başvurdu. Sağ yanak içi mukozasında 3 cm x 2 cm eritemli vasküler dokuyla çevrili beyaz yama alanları mevcuttu. Histopatolojik olarak follikül oluşturan lenfositler, bunları çevreleyen inflamatuvar hücreler ile eozinofili ve fibrozis gözlemlendi. Bu olguyu sunmamızın nedeni tanının histopatolojik olarak konulması ve olgunun bayan hastada görülmesidir.

Anahtar Sözcükler: Kimura hastalığı, oral kavite, olgu sunumu.

Abstract

Kimura disease is a chronic idiopathic disease which is usually presented with lymphadenopathy or subcutaneous masses involving head and neck, frequently accompanied by peripheral blood eosinophilia and elevated serum Ig E level. A 52-year-old female presented with recurrent oral cavity lesions for 5 years. There was a 3 cm x 2 cm lesion on the right buccal mucosa which had white patchy areas surrounded by erythematous, vascular tissue. Histopathologically lymphocytes forming follicles surrounded by an inflammatory infiltrate with eosinophilia and fibrosis was observed. We report this case because the diagnosis was made histopathologically and it was seen in a female patient.

Key Words: Kimura disease, oral cavity, case report.

Türk Otolarengoloji Arşivi, 2008; 46(2): 113-116

Turk Arch Otolaryngol, 2008; 46(2): 113-116

Sıdıka Deniz Micozkadıoğlu, MD; Can Alper Çağıcı, MD; Cüneyt Yılmaz, MD
Department of Otorhinolaryngology&Head and Neck Surgery, Adana Teaching and Medical Research Center, Başkent University Faculty of Medicine, Adana

Nebil Bal, MD
Department of Pathology, Adana Teaching and Medical Research Center, Başkent University Faculty of Medicine, Adana

Introduction

Kimura disease (KD) is a chronic inflammatory disease of unknown etiology, manifesting as painless unilateral cervical lymphadenopathy or subcutaneous masses in the head and neck. The lesions tend to recur despite treatment.¹ The disease was first described in 1937 in the Chinese literature by Kimm and Szeto.¹ Its name was given by the definitive histological description published by Kimura in 1948.¹ KD is endemic in Asia (especially in China

and Japan) but rare and sporadic in the rest of the world. It is commonly seen in males.¹

Several etiological factors have been proposed in the pathogenesis of KD, including autoimmune, allergic, neoplastic and infective causes such as insect bites, parasites and candida, yet no infective agent has been isolated so far.^{2,3} TH2 mediated immune response has been proposed in the view of increased expression of IL-4, IL-5 and IL-13 mRNAs in the peripheral blood mononuclear cells.²

Histologically, there are prominent germinal centers composed of three elements: cellular, fibrocollagenous and vascular. The cellular component consists of dense eosinophilic infiltrate of interfollicular zones, lysis of follicles. Granuloma formations contain infiltrates of eosinophils, lymphocytes, plasma cells, and histiocytes. Dense tissue fibrosis and vascular proliferation are present.⁴ Immunohistochemistry shows CD20-positive B lymphocytes in the germinal centers of lymph follicles and CD3-positive T cells at the periphery.⁵

Most significant association is renal disease leading to nephrotic syndrome. It may develop before or concurrently with KD.⁶ In a few cases itchiness, urticaria and chronic eczema have been reported.⁶

Case Report

A 52-year-old female presented with recurrent oral cavity lesions for 5 years. There was a 3 cm x 2 cm lesion on the right buccal mucosa which had white patchy areas surrounded by erythematous, vascular tissue. The lesion had indistinct borders. The biopsy revealed suprabasal acantholytic cells, capillary proliferation and lymphoplasmocytic inflammatory cell infiltration forming lymphoid follicles lying beneath the stratified squamous epithelium. The lymphoid follicles had germinal centers. There were lysis of follicles, rich eosinophilic infiltration, lymphoid hyperplasia and fibrosis. The perivascular wall was proliferative and endothelium was oedematous. Neck examination revealed no lymphadenopathy. The patient had no systemic disease involvement. History revealed no etiologi-

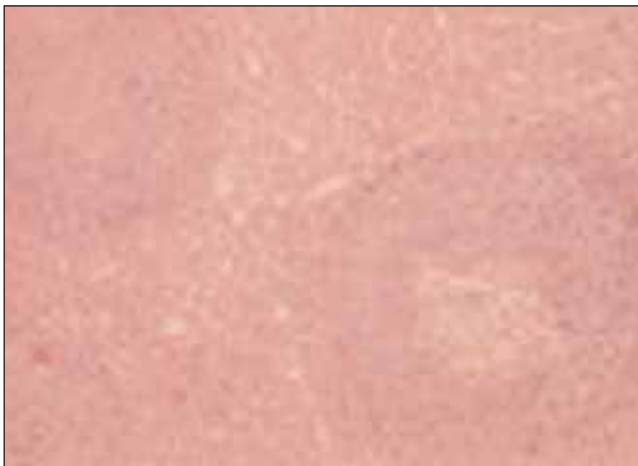

Figure 1. Prominent lymphoid and capillary proliferation. Lymphoid follicles have germinal centers (HE x100). [Color figure can be viewed in the online issue, which is available at www.turkarchotolaryngol.org]

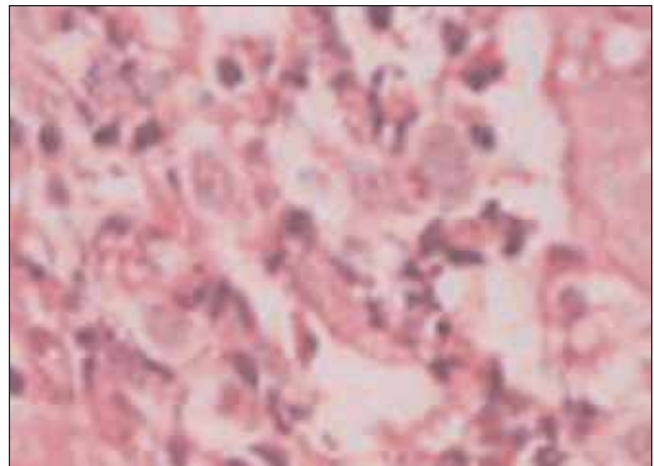


Figure 2. Endothelial proliferation and eosinophilic infiltration (HE x400). [Color figure can be viewed in the online issue, which is available at www.turkarchotolaryngol.org]

cal factor. History revealed that she was treated with antibiotics, topical steroids but the medications did not have any effect. The lesion was subsiding spontaneously. There was mild anemia, monocytosis, basophilia. Total eosinophil count and Ig E level were found normal. Creatinine, BUN and creatinine clearance were within normal limits and there was no renal involvement. Chest radiograph was normal.

Discussion

KD occurs mainly in young Oriental males presenting with single or multiple large asymptomatic masses involving the subcutaneous tissue or salivary glands, frequently accompanied by peripheral blood eosinophilia and elevated serum Ig E level.² KD is often confused with angiolymphoid hyperplasia with eosinophilia (ALHE). In contrast ALHE occurs predominantly in young to middle aged females of any race, presenting with multiple small erythematous dermal papules which may be associated with pruritus.² Both KD and ALHE have similar predilections for the head and neck region.²

Our case was a middle-aged female patient. There was not any lymphadenopathy associated with the disease. There was no peripheral eosinophilia and serum Ig E was normal. We did not think our patient as KD clinically but with lymphoid follicles having germinal centers, lysis of follicles, rich eosinophilic infiltration, lymphoid hyperplasia and fibrosis findings KD was diagnosed pathologically. Although lymphoid infiltration with eosinophils and vascular proliferation are similar features both in KD and ALHE there are distinct histologic differences.⁴ First, blood vessels are histiocytoid type specific to ALHE. Second, lysis of the follicles due to heavy infiltration of germinal centers with eosinophils is seen only in KD. Third, in KD germinal centers have Ig E that is stained

immunohistochemically.⁴ Another difference is that fibrosis is prominent in KD.⁷ To make differential diagnosis with pemphigus immunohistochemical staining was applied. The vessel walls were stained Ig G positive, Ig M positive focally, Ig A negative immunohistochemically. Because there was no staining neither in the intercellular space in epithelium nor in the epithelial basement membrane, we excluded pemphigus vulgaris and bullous pemphigoid.

Surgical excision, local radiotherapy, corticosteroids (intralesional or oral), pentoxifylline, cyclosporine, non-steroidal anti-inflammatory drugs and oral retinoids have been tried in treatment with different success rates.² Messina-Doucet⁴ suggested surgical excision as the treatment of choice for definitive diagnosis and initial management.⁸ Surgical excision can be preferred as localized initial recurrence. If recurrence is frequent or the patient develops symptomatic nephrotic syndrome, oral corticosteroids should be initiated. If these options fail, low dose radiotherapy may be considered but side-effects limit its use.⁴ Other treatment options are cryotherapy, electrodesiccation, and laser fulguration with different results.³

Our case is exceptional because the diagnosis was established on the basis of typical histopathological features, KD was not suspected clinically. KD should be considered in the differential diagnosis of oral mucosa lesions.

References

1. **Yuen HW, Goh YH, Low WK, Lim-Tan SK.** Kimura's disease: a diagnostic and therapeutic challenge. *Singapore Med J* 2005; 46: 179-83.
2. **Chong WS, Thomas A, Goh CL.** Kimura's disease and angiolymphoid hyperplasia with eosinophilia: two disease entities in the same patient. Case report and review of the literature. *Int J Dermatol* 2006; 45: 139-45.
3. **Kurukahvecioğlu S, Yardımcı S, Kurukahvecioğlu O, Yılmaz E.** Kimura's disease in the parotid and submandibular

regions: two case reports. *Kulak Burun Bogaz Ihtis Derg* 2003; 11: 157-60.

4. **Messina-Doucet MT, Armstrong WB, Allison G, Pena F, Kim JKV.** Kimura's disease: two case reports and a literature review. *Ann Otol Rhinol Laryngol* 1998; 107: 1066-71.
5. **Zhang JZ, Zhang CG, Chen JM.** Thirty-five cases of Kimura's disease (eosinophilic granuloma). *Br J Dermatol* 1998; 139: 542-3.
6. **Chen H, Thompson LD, Aguilera NS, Abbondanzo SL.** Kimura disease: a clinicopathologic study of 21 cases. *Am J Surg Pathol* 2004; 28: 505-13.
7. **Li TJ, Chen XM, Wang SZ, Fan MW, Semba I, Kitano M.** Kimura's disease: a clinicopathologic study of 54 Chinese patients. *Oral Surg Oral Med Oral Pathol Oral Radiol Endod* 1996; 82: 549-55.
8. **Chen H, Thompson LD.** Kimura disease. *Ear Nose Throat J* 2003; 82: 763.

Conflict of interest statement:

No conflicts declared.

Correspondence: Sidika Deniz Micozkadiođlu, MD

Department of Otorhinolaryngology Head and Neck Surgery

Adana Teaching and Medical Research Center

Bařkent University Faculty of Medicine

Baraj Yolu 1. Durak

Seyhan 01110 ADANA

Phone: +90 322 458 68 68

Fax: +90 322 459 91 97

e-mail: denizmicozkadioglu@yahoo.com