

## OLGU BİLDİRİSİ / CASE REPORT

# Necrotizing soft-tissue infections of the neck: a case report

U. Kubilay, O.S. Sezen, E. Aydın, S. Haytaoğlu, D. Berk, Ş. Ünver

### Nekrotizan yumuşak doku enfeksiyonu: olgu sunumu

Nekrotizan yumuşak doku enfeksiyonları yıkıcı ve hayatı tehdit edicidir. Boyun ve göğüs duvarı nekrotizan yumuşak doku enfeksiyonları nadirdir. Bu durum sıklıkla postoperatif dönemde, farklı cerrahi prosedürler sonrasında görülebilir. Biz burada etyolojinin belirlenemediği, boyun ve göğüs duvar tutulumu olan vakamızı sunduk.

**Anahtar Sözcükler:** Nekrotizan yumuşak doku enfeksiyonu, immün yetmezlik, nekrotizan fasiitis.

### Abstract

Necrotizing soft-tissue infections are destructive and life-threatening. Necrotizing soft-tissue infections of the neck and chest wall are uncommon. The condition is seen more frequently in postoperative patients undergoing a variety of procedures. We describe a patient with necrotizing soft-tissue infections of the neck and chest wall in whom the etiology remains obscure.

**Key Words:** Necrotizing soft-tissue infection, immune compromise, necrotizing fasciitis.

Türk Otolarengoloji Arşivi, 2008; 46(1): 41-44

Turk Arch Otolaryngol, 2008; 46(1): 41-44

## Introduction

Necrotizing fasciitis considered the most aggressive form of soft-tissue infection. They usually involve the abdominal wall, perineum or lower extremities.<sup>1</sup> Most patients who develop necrotizing soft tissue infections have evidence of preexisting immune compromise including diabetes mellitus, advanced age (older than 60 years of age), acute or chronic renal failure, postpartum state, alcoholism, intravenous drug abuse, malnutrition, malignancy, polymyositis, peripheral vascular disease and post-radiation status or local defects predisposing to cellulitis (peripheral vascular disease or lymphedema).<sup>1,2-4</sup> More rarely, the infection may occur spontaneously without apparent or simultaneously with distant infection such as paronychia.<sup>5,6</sup>

Utku Kubilay, MD

Department of Otolaryngology, Head and Neck Surgery, Sultanbeyli Government Hospital, Istanbul

Ozan Seymen Sezen, MD; Ercan Aydın, MD; Süheyl Haytaoğlu, MD; Derya Berk, MD; Şeref Ünver, MD

Department of Otolaryngology, Head and Neck Surgery, Dr. Lütfi Kırdar Kartal Training and Research Hospital, Istanbul

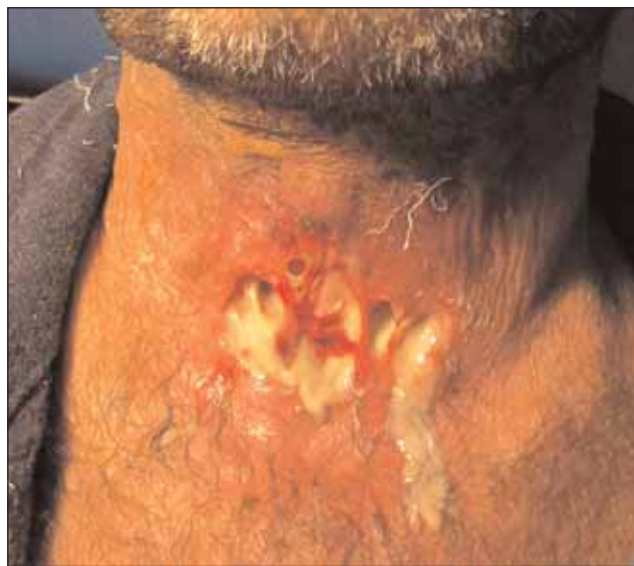Necrotizing soft-tissue infections of the neck and chest wall are uncommon and seen more frequently in postoperative patients undergoing a variety of procedures, including tube thoracostomy, breast, and pulmonary and laryngectomy surgery.<sup>7,8</sup> It is frequently accompanied by moderate to severe sepsis and septic shock. It is usually rapidly fatal especially in neck and chest wall without prompt recognition and surgical treatment. The mortality rate may be as high as 89%.<sup>1</sup> Although general treatment strategies of necrotizing infections in other anatomic locations are applicable to neck and chest wall infections, certain aspects of wound care and ventilatory physiology make neck and chest wall necrotizing infections particularly challenging to manage.

We describe a patient with necrotizing soft-tissue infections of the neck and chest wall, which led to local invasion of the overlying fascia and skin. The patient had a history of rheumatoid arthritis with long term oral corticosteroid treatment. He was on remission for two years and was not taking any medication. In this context, the etiology of the infection remains obscure.

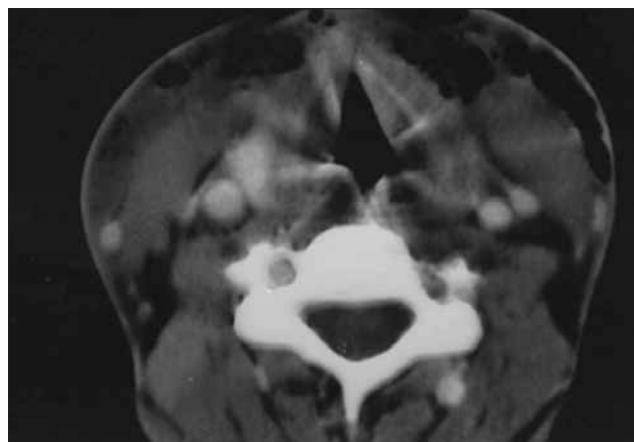
### Case Report

A 36-year-old male presented with a progressive, painful swelling in the submental region. Patient was questioned about his condition before this admission, which revealed that he had been febrile and painful swelling in the submental region, that had developed 48 hours before. Also the patient had a 4 years history of rheumatoid arthritis and long term oral corticosteroid treatment but was on remission and was not taking any medication for the last two years.

On examination he was alert and oriented. Surface temperature was 38.3°C, blood pressure 106/64 mm Hg, pulse 146/min, and 24/min respirations. Examination of the neck revealed red-blue, blistering swelling below both sides substernally. In the anterior neck region there was superficial necrosis

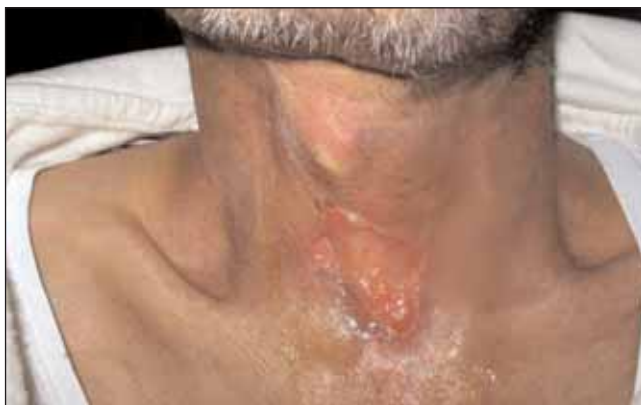

**Figure 1.** Photograph showing the wound in the anterior neck region. [Color figure can be viewed in the online issue, which is available at [www.turkarchotolaryngol.org](http://www.turkarchotolaryngol.org)]



**Figure 2.** Computed tomography (CT) scan of the region showing subcutaneous emphysema that surrounds the neck side.

of the skin, the affected area was an estimated 200 cm<sup>2</sup> (Figure 1). The abdomen was unremarkable. Admission studies were significant for an elevated white blood cell count of 19,400 and hypokalemia. A chest radiograph showed air in the right chest wall. Computed tomography (CT) scan of the region showed subcutaneous emphysema that surro-



**Figure 3.** Photograph showing the wound on the 13th postoperative day. [Color figure can be viewed in the online issue, which is available at [www.turkarchotolaryngol.org](http://www.turkarchotolaryngol.org)]

unds the neck site (Figure 2). Broad-spectrum antibiotic coverage was instituted until cultures from wound and blood were obtained. Intravenous antibiotic treatment consisting of and intravenous rehydration was started immediately. Wound and blood cultures both revealed group A -hemolytic streptococcus as the offending organism. In antibiogram study, isolated pathogen was found to be sensitive of the amoxicillin/clavulanate potassium.

On the 3rd day of admission, debridement of the affected tissues was carried out under general anesthesia. The affected area was debrided widely. All necrotic tissue was excised until bleeding from healthy tissue was noted. The affected area was lavaged with hydrogen peroxide. All incisions were with hydrogen peroxide soaked dressings packed open. On postoperative day metronidazole added. The dressing was changed every day at the bedside with adequate sedation and analgesia. Wounds were free of infection and nonviable tissue and with the presence of granulation tissue Antibiotics were stopped after 10 days the wound was granulating and there were no signs of systemic infection. The patient's condition progressively improved the total length of hospitalization from the time of surgical intervention until discharge was 13 days (Figure 3).

## Discussion

Diagnosis of necrotizing fasciitis is usually based on clinical findings and a high index of suspicion.<sup>3,9</sup> The external appearance of the skin wound may initially betray the magnitude of the necrotizing infection beneath it; this contributes to diagnostic delay. Most patients with necrotizing fasciitis (47-94%) present with pain, especially pain that seems disproportionate to the wounds.<sup>1-3</sup> The skin becomes anaesthetized well beyond the area of suspected infection and loses contact with the underlying tissues as a result of suppuration.<sup>4</sup> Rapid progression to septic shock with crepitus; foul, watery wound discharge; skin blistering; is observed.

Frozen-section biopsy may be helpful, but only if the diagnosis is suspected and the biopsy performed within the first 4 days after onset of symptom.<sup>8</sup>

The histopathological examination consists of obliterative vascular thrombosis, necrosis and a polymorphonuclear infiltrate that is initially confined to the deep dermis and superficial fascia. In the early stages, the skin, deep fascia and underlying muscles are typically spared.<sup>10</sup> CT scans or magnetic resonance imaging scans are helpful in confirming subcutaneous gas described as "pathognomonic" for necrotizing soft tissue infections, although it is not always present.<sup>1,2,3</sup> These imaging scans also determining the limits and demonstrating the extent of soft tissue involvement.<sup>7,3</sup> Generally, extensive diagnostic studies are unnecessary and may delay definitive therapy.

Some necrotizing infections are caused by single organisms however usually polymicrobial caused by a mixture of aerobic and anaerobic bacteria, which act synergistically to cause fulminant infection.<sup>1,11</sup> Organisms commonly identified include aerobic and anaerobic streptococci, coagulase-negative and coagulase-positive staphylococci, facultative and aerobic gram-negative rods, *Bacteroides species*, and *Clostridium species*.<sup>11</sup> Antibiotic coverage should be broad spectrum, and anaerobic coverage is essential. Antibiotics alone are not effective unless coupled with surgical treatment; However; survival has been described with no debridement.<sup>6,12</sup>

Surgical interventions are superficial debridement, or multiple and complex debridements which requires reconstruction of the resulting complex chest wall defect. The effectiveness of repeated debridement and hyperbaric oxygen therapy have an uncertain role in the management of necrotizing soft tissue infections.<sup>13</sup>

Necrotizing soft tissue infections carry reported mortality rates ranging from 6% to 76%.<sup>13</sup> In cases involving the chest wall, mortality rates are even higher, reported as 89% in a series of 9 patients reviewed by Urschel et al.,<sup>1</sup> and 77% in a slightly larger series of 13 patients compiled a few years later.<sup>13</sup> The mortality rate is 59% (10 deaths in 17 patients), lower than in previous reports of necrotizing soft tissue infections of the chest but still higher than the mortality rate described for necrotizing fasciitis in general.<sup>14</sup>

Death usually results from multisystem organ failure occurring as a complication of sepsis.<sup>2</sup> Intravenous fluid resuscitation, mechanical ventilation, and inotropic support follow well-established principles for managing septic shock.

Prognosis is associated, delay in surgical treatment and immune compromised subjects.<sup>4</sup> A high clinical suspicion, based on local and systemic signs, and directed diagnostic studies establish the diagnosis. Combination of early surgical debridement, broad-spectrum antibiotics and intensive supportive care mainstays of successful chest wall necrotizing fasciitis management. The dressing every day at the bedside with adequate sedation and analgesia can be helpful beside hyperbaric oxygen therapy. Intensive rehabilitation may be necessary to return the patient to premorbid function once the acute infection is treated.<sup>15</sup>

## References

1. Urschel JD, Takita H, Antkowiak JG. Necrotizing soft tissue infections of the chest wall. *Ann Thorac Surg* 1997; 64: 276-9.
2. Safran DB, Sullivan WG. Necrotizing fasciitis of the chest wall. *Ann Thorac Surg* 2001; 72: 1362-4.
3. Cunningham JD, Silver L, Rudikoff D. Necrotizing fasciitis: a plea for early diagnosis and treatment. *Mt Sinai J Med* 2001; 68: 253-61.
4. Kronish JW, McLeish WM. Eyelid necrosis and periorbital necrotizing fasciitis. Report of a case and review of the literature. *Ophthalmology* 1991; 98: 92-8.
5. Sutherland ME, Meyer AA. Necrotizing soft-tissue infections. *Surg Clin North Am* 1994; 74: 591-607.
6. Dayal A, Gupta LP, Patawari J, Dave KS. The chest wall gangrene in an infant. *Indian J Chest Dis Allied Sci* 1979; 21: 102-4.
7. Chen YM, Wu MF, Lee PY, Su WJ, Perng RP. Necrotizing fasciitis: is it a fatal complication of tube thoracostomy? Report of three cases. *Respir Med* 1992; 86: 249-51.
8. Beerens AJ, Strack van Schijndel RJ, Mahieu HF, Leemans CR. Cervical necrotizing fasciitis with thoracic extension after total laryngectomy. *J Laryngol Otol* 2002; 116: 639-41.
9. Frota Filho JD, Drews C, Leaes P, et al. Postoperative necrotizing fasciitis of the thorax in cardiac surgery. *Arq Bras Cardiol* 2001; 76: 245-54.
10. Banwell PE, Pereira J, Powell BW. Symmetrical necrotising chest wall infection following paronychia. *J Accid Emerg Med* 1998; 15: 58-9.
11. Giuliano A, Lewis F Jr, Hadley K, Blaisdell FW. Bacteriology of necrotizing fasciitis. *Am J Surg* 1977; 134: 52-7.
12. Atiyeh BC, Zaatari AM. Necrotizing fasciitis of the upper extremity. *J Emerg Med* 1994; 12: 611-3.
13. Pessa ME, Howard RJ. Necrotizing fasciitis. *Surg Gynecol Obstet* 1985; 161: 357-61.
14. Praba-Egge AD, Lanning D, Broderick TJ, Yelon JA. Necrotizing fasciitis of the chest and abdominal wall arising from an empyema. *J Trauma* 2004; 56: 1356-61.
15. Balbierz JM, Ellis K. Streptococcal infection and necrotizing fasciitis-implications for rehabilitation: a report of 5 cases and review of the literature. *Arch Phys Med Rehabil* 2004; 85: 1205-9.

## Conflict of interest statement:

No conflicts declared.

**Correspondence: Utku Kubilay, MD**  
Selimiye Mah. Bestekar Avni Anil Sk.  
Savtekin Apt. No: 32/10  
Üsküdar 34668 İSTANBUL  
Phone: +90 216 310 98 27  
e-mail: drutkukubilay@hotmail.com