

Effects of Steroids on Edema and Ecchymosis in Rhinoplasty

F. Erişir, F. Öktem, E. İnci

Rinoplasti Sonrasında Oluşan Ödem ve Ekimozu Steroidlerin Etkileri

Rinoplasti sonrasında oluşan postoperatif ödem ve ekimozu azaltmada tek doz deksametazonun etkinliğini belirlemek için plasebo kontrollü prospektif bir randomize, çift kör çalışma planlandı. Hump rezeksiyonu ve lateral osteotomi uygulanan elli altı hasta çalışmaya dahil edildi. Otuz hastaya cerrahiden önce 10 mg intravenöz deksametazon, yirmi altı hastaya plasebo verildi. Postoperatif ödem ve ekimozun skorlaması yaklaşık olarak operasyondan 24 saat sonra başladı. Tüm hastalar yazarlar tarafından opere edildi. 24 saat sonraki periorbital ödem ve ekimozun şiddetini değerlendirmek için 4 puanlık bir skala kullanıldı.

Intravenöz olarak uygulanan 10 mg deksametazonun postoperatif ödem ve ekimozu anlamlı derecede azalttığı gözlemlendi. Steroid ve plasebo grupları arasında, ilk iki gündeki ödem ve ekimoz arasındaki farklar klinik ve istatistiksel olarak anlamlı bulundu ($p < 0.05$).

Steroid uygulanan olgu grubu, plaseboyla kıyaslandığında steroidlerin rinoplastideki ödem ve ekimozu azaltmada anlamlı bir yararı olduğu, fakat etkisinin ilk iki günden sonra kaybolması nedeni ile iyileşme süresini kısaltmadığı gözlemlendi. Deksametazon uygulamasına bağlı herhangi bir komplikasyon görülmedi.

Anahtar Sözcükler: Rinoplasti, steroid, lateral osteotomi, ödem.

Abstract

A randomized, prospective double-blind study with placebo control was planned to determine the effects of a single-dose dexamethasone in reducing postoperative edema and ecchymosis after rhinoplasty. Fifty-six consecutive patients who underwent rhinoplasty with hump removal and lateral osteotomies were enrolled in this study. Thirty patients received 10 mg of dexamethasone intravenously before surgery and twenty-six patients received placebo. Postoperative scoring of edema and ecchymosis was begun approximately 24 hours after surgery. All patients were operated by the authors. A 4-point scale was used to assess the extent of periorbital edema and ecchymosis 24 hours postoperatively.

A single-dose of 10 mg of dexamethasone intravenously reduced postoperative edema and ecchymosis significantly. The first two days differences between the steroid and placebo groups for edema and ecchymosis were clinically and statistically significant ($p < 0.05$).

This study showed a statistically significant benefit of steroids when compared to placebo in decreasing edema and ecchymosis in rhinoplasty. However, the effect of dexamethasone has disappeared after the first two days, and its use did not shorten the recovery. No complications were attributed to the administration of dexamethasone.

Key Words: Rhinoplasty, steroids, lateral osteotomies, edema.

Türk Arch ORL, 2001; 39(3): 171-175

Türk ORL Arşivi, 2001; 39(3): 171-175

Introduction

In the rhinoplastic surgery postoperative swelling and discoloration can influence the cosmetic result and frustrate the patient and surgeon alike.¹

Swelling is caused by an accumulation of fluid in tissue spaces. Periorbital swelling and discoloration is distressing for the patient who may have difficulty in seeing 24 hours postoperatively due to edema and is quite conscious (as are the friends and family) of this battered appearance. In the standard rhinoplasty operation, the osteotomies are responsible for a significant amount of this periorbital swelling and ecchymosis due to the injury to the angular vessels, which cross the osteotomy sites and the trauma of fracturing the nasal bones.¹⁻³ A marked improvement in the usual postoperative appearance would occur if this subcutaneous bleeding and swelling, following the osteotomies and fracturing, could be decreased.

Several approaches have been advocated to decrease edema and ecchymosis occurring postoperatively. The technical refinements in the last fifteen years produced a considerable reduction in the ecchymosis and edema, resulting in quicker and better healing. The most important factors are;

- 1- Precise placement of the local vasoconstrictive and anesthetic solutions
- 2- The use of micro-osteotomes
- 3- Preservation of periosteal attachment
- 4- Medial-oblique osteotomies to eliminate transverse osteotomies.

Another way of minimizing or preventing edema and ecchymosis is administration of steroids, which were widely practiced in maxillofacial and plastic surgery.² Some experimental animal studies have demonstrated reduced edema in flap models or replants.^{3,4} Also, several clinical studies evaluated the use of steroids perioperatively in a variety of orthognathic and facial surgical procedures, but the results have been conflicting.^{5,6}

Various doses, schedules and routes of steroid administration have been used along with many methods of measuring postoperative edema. Studies by Beirne,⁷ Pedersen⁸ and Siste⁹ demonstrated statistically significant reduction in postoperative edema after steroid administration. Various corticosteroids have been used in previous studies, but dexamethasone seems most suitable because it has the highest anti-inflammatory activity and a biologic half life of 36 to 54 hours, the longest available.¹⁰ A randomized double-blind study was performed to determine the short-term effects of preoperative steroids in rhinoplasty.

Materials and Methods

Fifty-six consecutive rhinoplasties, all of which required hump removal and lateral osteotomies were randomized to receive either a 10 mg bolus of intravenous dexamethasone or a saline placebo 20 minutes prior to surgery. Specific exclusion from the study included a history of peptic ulcer disease, diabetes mellitus or allergy to steroids. In our study, no patient was excluded for these reasons. Thirty patients received 10 mg of dexamethasone intravenously before surgery and twenty-six patients received placebo. The dexamethasone or placebo was given by a nurse and both the physician and the patient were unaware which substance was administered until the completion of the study. The operations were performed under general endotracheal anesthesia. In addition, local anesthesia of 1% lidocain with 1:100.000 epinephrine was infiltrated to the osteotomy sites. A medial-oblique osteotomy was combined with a slightly curved lateral osteotomy with a 2 or 3 mm osteotome and there was no necessity to elevate the periosteum. Nasal packing with normal gauze routinely used. All patients underwent an operation using the same technique and received similar postoperative care. Postoperatively the patients were prescribed some painkillers only. Postoperative assessment of swelling and ecchymosis was performed after 24 hours by the authors. Edema and ecchymosis were evaluated using a 4-point grading scale. Severity of edema and ecchymosis were rated separately. Edema and ecchymosis of the medial one third of the periorbital region was rated 1+, lower two thirds was 2+, lower and upper two thirds was 3+, and the entire periorbital region was rated 4+ (Figure 1).

Results

A total of 56 patients who were undergoing rhinoplasty with osteotomies and hump removal were entered in this study. There were 20 women and 36 men. The age range was 17 to 44 years with a median age of 24. The distribution of patients undergoing a closed versus open rhinoplasty was nearly equal in each group.

Thirty of the patients were included into the group receiving steroids and twenty-six received placebo. It is apparent that edema and ecchymosis in the treatment group was less than in the control

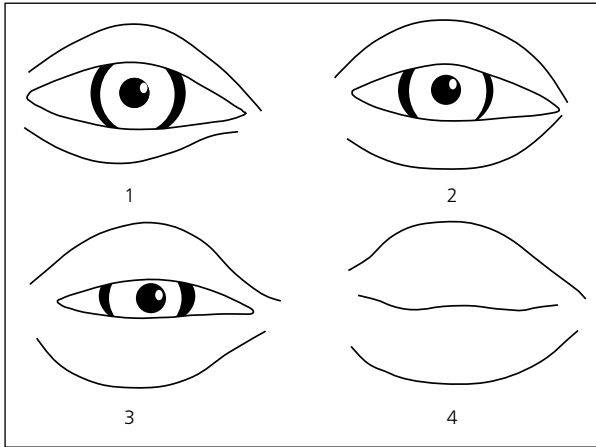


Figure 1. Method of evaluating eyelid edema. 0 indicates none; 1+, minimal; 2+, moderate; 3+, severe; 4+ complete (massive edema)

group (Figure 2). Edema and ecchymosis around the eyes of the steroid group was significantly lower than that of the placebo group on the first and second postoperative days ($p < 0.05$) (Fisher chi-square test) (Figures 3 and 4). Single-dose steroid use lost its effect after the first two days, and it did not shorten the recovery period. None of the patients had any complication due to the use of dexamethasone.

The mean edema and ecchymosis assessment scale scores of patients receiving steroids, and those

Edema	***		+4
	*****	*** **	+3
Rating	****	***** **	+2
	***	***** *****	+1
	Placebo	Steroids	

Figure 2. Ratings for postoperative edema. The higher rating indicates a judgement of greater edema.

receiving placebo, are shown in Table 1. Differences for edema and ecchymoses are both clinically and statistically significant.

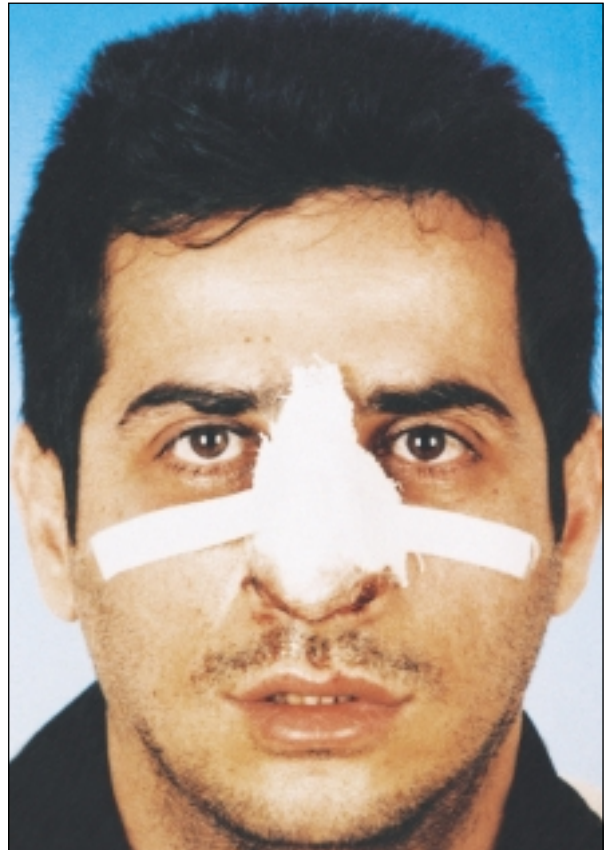

Figure 3. Edema and ecchymosis 24 hours postoperatively of the steroid group.

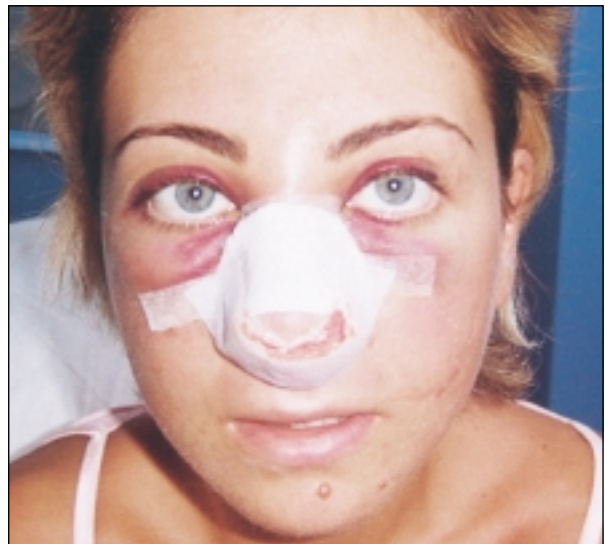

Figure 4. Edema and ecchymosis 24 hours postoperatively of the placebo group.

Table 1. Differences between means of edema and ecchymosis for treatment and control groups.

	Edema	Ecchymosis
Placobe	2.50	2.70
Steroids	1.50	1.60
p value	< 0.05	< 0.05

Discussion

For the prevention of edema and ecchymosis occurring postoperatively several approaches have been used. Recently the use of micro-osteotomes reduces these effects significantly without any medication.

In addition technical refinements, several steroid preparations have been used to minimize the edema and ecchymosis in rhinoplasty.¹⁻⁴

Steroids are known as gene-active hormones. Their mechanism of action is by binding with chromatin in a cell nucleus, which then regulates a specific gene sequence to produce enzymes and proteins. These enzymes and proteins act on a target cell to minimize the inflammatory process by stabilizing cell membranes, inhibiting certain cell mediators, and inhibiting fibroplasia of the reparative process.¹¹

Steroids produce an effect after a characteristic period of 30 minutes to several hours. The effect (beneficial or toxic) may persist from a few hours to several days, and does not correlate directly with plasma levels.¹²

There are a wide variety of synthetic glucocorticoids. Dexamethasone is one of the most potent anti-inflammatory steroid. Its onset is relatively fast and its effects are moderately long lasting.^{11,12}

In determining the optimal time to administer perioperative dexamethasone, the time sequence of the permeability changes in inflammation must be taken into consideration. The major type of permeability response associated with the surgical trauma of rhinoplasty is called the early response. In this type, a strong permeability response may begin within a few minutes of injury and reach a peak within 15 to 30 minutes or within 60 minutes with weaker stimuli.¹³ Since dexamethasone's onset is 30 to 60 minutes, it would seem rational, on a pharmacologic basis, to administer dexamethasone dose the start of the operation.

Beirne and Hollander⁷ performed a double blind prospective study to determine the benefit of methylprednisolone in decreasing swelling in third molar extractions. They found a statistically significant decrease in swelling in those patients who received steroids. They also noted some increased swelling in the treatment group on the second and third days after extraction, although still significantly lower than in placebo patients. Our study shows similar results to this study and this increase might be due to inflammation, in which during the first postoperative day the effect of the single-dose steroid decreases. Hoffmann et al.¹⁴ did not report swelling increment in the second day because they continued to steroids for five days and the inflammatory response might be overcome and the increment of edema on the second day would not appear.

Steroids sometimes may cause complications, especially on long-term administration. Dosage above the physiological levels of approximately 20 mg of hydrocortisone for five days or longer may cause adrenal suppression.¹⁵ However, a single dose of glucocorticoid, even a large dose, can be used without any harmful effect.¹¹ We used a single dose 10 mg steroid in our study and no complication were attributed to the administration of dexamethasone.

Conclusion

In the rhinoplastic surgery postoperative swelling and discoloration can influence the cosmetic result and frustrate the patient and surgeon alike. This study showed a statistically significant benefit with a single-dose 10 mg steroid administration 20 minutes prior to surgery when compared with placebo, in decreasing edema and ecchymosis.

Although swelling is a very individual phenomenon and an unpredicted postoperative result, the surgeon does exercise some control over it. It is unlikely that any one factor or any combination of factors will eliminate it entirely. This study indicates that the use of steroids even for the first few postoperative days is a great benefit for the patient to decrease the initial surgical morbidity associated with rhinoplasty.

References

1. **Stucker F J.** Prevention of post-rhinoplasty edema. *Laryngoscope* 1974; 84(4): 536-41.
2. **Kara CO, Gökalan I.** Effects of single-dose steroid usage on edema, ecchymosis, and intraoperative bleeding in rhinoplasty. *Plast Reconstr Surg* 1999; 104(7): 2213-8.
3. **Schmidt JH, Caffee HH.** The efficacy of methylprednisolone in reducing flap edema. *Plast Reconstr Surg* 1990; 86(6): 1148-51.
4. **Habal MB, Powell RD.** Experimental facial edema: Treatment with methylprednisolone. *J Surg Res* 1978; 24(5): 353-8.
5. **Schaberg SJ, Stuller CB, Edwards SM.** Effects of methylprednisolone on swelling after orthognatic surgery. *J Oral Maxillofac Surg* 1984; 42(6): 356-61.
6. **Echavez MI, Mangat DS.** Effects of steroids on mood, edema, and ecchymosis in facial plastic surgery. *Arch Otolaryngol Head Neck Surg* 1994; 120(10): 1137-41.
7. **Beirne OR, Hollander B.** The effect of methylprednisolone on pain, trismus and swelling after removal of third molars. *Oral Surg Oral Med Oral Pathol* 1986; 61(2): 134-8.
8. **Pedersen A.** Decadronphosphate in the relief of complaints after third molar surgery. A double-blind controlled trial with bilateral oral surgery. *Int J Oral Surg* 1985; 14(3): 235-40.
9. **Sisk AL, Bonnington GJ.** Evaluation of methylprednisolone and flurbiprofen for inhibition of postoperative inflammatory response. *Oral Surg Oral Med Oral Pathol* 1985; 60(2):137-45.
10. **Gillman AF, Rall TW.** Goodman and Gilman's. The Pharmacological Basis of Therapeutics. 8th Ed. New York, NY, Pergamon 1990; 1442.
11. **Haynes RC, Larner J.** Adrenocorticotrophic hormone, adrenocortical steroids and their synthetic analogs: Inhibitors of adrenocortical steroids biosynthesis. In: The Pharmacological Basis of Therapeutics. Goodman LS, Gillman, A (Eds.). 5th Ed. New York, Macmillan Publishing Co., 1975; 1472.
12. **Katzung BG.** Basic and Clinical Pharmacology. California, Lange Medical Publications, 1982; 390-2, 420-5.
13. **Wilhelm DL.** Inflammation and Healing. In: Pathology. Anderson WAD, Kissane JM (Eds.). 7th Ed. St. Louis, C.V. Mosby Co., 1977; 22.
14. **Hoffmann DF, Cook TA, Quatcla VC, Wang TD, Brownrigg PJ, Brummett RE.** Steroids and rhinoplasty: A double-blind study. *Arch Otolaryngol Head Neck Surg* 1991; 117: 990-3.
15. **Cawson RA, James J.** Adrenal crisis in dental patient having systemic corticosteroids. *Br J Oral Surg* 1973; 10(3): 305-9.

İletişim Adresi: Ferhat Erişir, MD

*Cerrahpaşa School of Medicine, Istanbul University,
ENT Department
K.M.Paşa 34303 İSTANBUL
Tel: (0212) 568 35 33*