

Case Report	
Doi: 10.4274/ejbh.galenos.2020.5541	
Nipple eczema responsible for galactorrhea by reactive hyperprolactinemia, complicated by a galactocele.	
Chassain et al. Nipple eczema, prolactinemia, galactocele	
Kevin CHASSAIN¹ Arthur VRIGNAUD¹ Elise CESBRON¹ Corina BARA-PASSOT¹ Hervé MAILLARD¹	
¹ Public Hospital, Dermatology, Le Mans, France	
Nipple eczema, hyperprolactinemia, galactocele	
Received: Aug 14, 2020	
Accepted: Nov 11, 2020	
Correspondence:	Kevin Chassain ; kchassain@ch-lemans.fr
Presented In:	Poster : Journée dermatologiques de Paris 2019

Uncorrected proof

Abstract

We present a case of atopic nipple eczema responsible for reactive hyperprolactinemia, by mechanical nipple stimulation. This reactive hyperprolactinemia itself causes an aggravation of the eczema by the resulting galactorrhea, by local irritation and inflammation, and is complicated by a galactocele. This benign tumour was a source of concern for the patient and requiring several diagnostic radiographic examinations.

Uncorrected proof

Introduction

Nipple eczema is a manifestation of atopic dermatitis and constitutes a known topography (1). Bilateral presentations are the most common, with a chronic course involving successive periods of remission and aggravation, particularly in cases of additional contact eczema or during breastfeeding (2, 3).

Hyperprolactinemia is defined as an increase in plasma prolactin concentration to levels beyond the upper detection limit, which is mostly between 15 and 25 ng/ml (corresponding to about 500 IU/ml), according to the method used. Its classic etiologies are pituitary diseases (hypophysitis, macroadenoma), hypothalamic diseases (sarcoidosis, meningioma), drug treatments (neuroleptics), and endocrinological conditions (hypothyroidism, polycystic ovary syndrome, pregnancy and breastfeeding). Their clinical manifestations are dominated by amenorrhea and galactorrhea. Reactional hyperprolactinemia in response to external stimulation of the nipple is a known phenomenon that contributes to milk secretion during breastfeeding. The stimulus provided by breastfeeding leads to the secretion of prolactin through activation of the vagal nerve. Repeated stimulation of the nipple in non-lactating women can also activate similar mechanisms, triggering reactional hyperprolactinemia (4, 5, 6).

Eczema due to contact of the nipples with maternal breast milk has never been reported.

We describe here the case of a 48-year-old woman presenting bilateral atopic eczema of the nipples causing galactorrhea through reactional hyperprolactinemia, resulting in clinical aggravation through secondary local irritation and inflammation, and galactocele. The patient has given her written and informed consent to this publication.

Case report

A 48-year old postmenopausal woman presented atopic dermatitis diagnosed in childhood, with no other relevant medical history, and without current medical treatment. She presented regular flare-ups of generalized eczema, treated with class II topical steroids, but often insufficiently due to a strong fear of steroids. No systemic treatment was introduced, by wish of the patient not to have oral treatment.

An allergology evaluation performed between 1995 and 2019 identified multiple sensitizations. The elimination of these allergens improved the patient's eczema everywhere except the nipples, where the lesions persisted.

The patient consulted with highly debilitating severe eczema of both nipples, of about twelve months duration. The manifestations were yellow crusty lesions of the nipples, discharging large amounts of a thick milky liquid emanating from the pores of the lactiferous ducts (Figures 1, 2 and 3). The areolae were thickened and inflamed, and several eczema-like lesions were observed on the patient's back and arms. One nodular lesion of the right breast, a centimeter or so across, was detected on palpation. The rest of the clinical examination was normal.

Pathological examination of a skin biopsy specimen taken from the internal right periareolar region revealed a histological appearance consistent with chronic eczema, with no signs of bacterial or fungal infection.

Bilateral mammography and breast ultrasound examination revealed the presence of a micronodule of pseudocyst-like appearance, consistent with a galactocele of about a centimeter across, under the right areola. The examination was classified as bilateral ACR 2 (American College of Radiologists). Blood tests revealed hypereosinophilia (up to 1798 elements/mm³), and hyperprolactinemia (93.10 ng/mL). Determinations of the plasma concentrations of other hypothalamus-pituitary gland axis compounds (Thyroid Stimulating Hormone, estradiol, Follicle Stimulating Hormone, Luteinizing Hormone, cortisol and Adrenocorticotrophic Hormone) were normal.

Brain MRI (magnetic resonance imaging) centered on the pituitary gland was performed to rule out pituitary macroadenoma. The results were strictly normal.

Galactocele induced by galactorrhea secondary to hyperprolactinemia due to mechanical stimulation of the nipples in a context of bilateral atopic nipple eczema was diagnosed (Figure 4).

Treatment with class I topical steroids, the application of which was checked during hospitalization, replaced by topical tacrolimus, resulted in the complete remission of the nipple eczema and the total cessation of galactorrhea. Tests on biological samples demonstrated a decrease in the prolactin blood level to 37.6 $\mu\text{g/L}$ after 72h from the start of treatment, and to 22.9 $\mu\text{g/L}$ (normal) after 1 month (Figure 5). Six months later she is still in complete remission without any recurrences after only 20g of topical tacrolimus by month.

Discussion

Galactocele is a complication well known to gynecologists. It occurs postpartum, during breastfeeding, and is not a cause of clinical concern in these contexts. Nipple eczema is a problem well known to patients with atopy: it can greatly affect the quality of life and may be difficult to treat.

Out of breastfeeding context, several cases of galactocele in a context of galactorrhea and hyperprolactinemia secondary to prolactinoma have been described (7, 8): our case is original by the absence of pituitary macroadenoma. Some cases have been reported after breast enlargement surgery (9, 10, 11, 12), or following vacuum-assisted core biopsy of the breast (13) : the etiology remains unclear, but this probably occurs in particular by post-surgical obstruction of the milk ducts. Pediatric cases are also described, especially in male infant, could represent a developmental anomaly possibly promoted by an obstructive phenomenon involving a defect of hollowing of some primary epidermal buds (14, 15).

However, galactocele has never been described as occurring secondary to a dermatological condition affecting the nipples. The common point of all these etiologies is probably the association of hyperprolactinemia and galactorrhea with a certain degree of obstruction of the milk ducts.

Conclusion

We describe the first case of nipple eczema, probably leading to the appearance of a galactocele through galactorrhea secondary to reactional hyperprolactinemia.

Nipple eczema led to excessive mechanical stimulation of the nipples and the areolae, due to discharge from the lesion, itching and local care (including non-adhesive dressings in particular).

This mechanical effect increased the pituitary secretion of prolactin through a hormonal response to local stimuli, thereby triggering the onset of galactorrhea outside the normal lactation period.

The occurrence of galactorrhea and/or hyperprolactinemia in a patient who is not breastfeeding should lead to clinical inspection of the skin to search for mechanical or traumatic factors responsible for mechanical stimulation of the nipple area.

An increase in serum prolactin concentration is classically observed in cases of chronic nipple stimulation and MRI examinations of the pituitary gland are not necessarily required in this context. It is crucial to explain the importance of treatment to avoid such significative consequences.

MainPoints :

- Nipple eczema is a manifestation of atopic dermatitis and constitutes a known topography.
- Mechanical nipple stimulation causes reactive hyperprolactinemia.
- The occurrence of galactorrhea, hyperprolactinemia, or galactocele in a patient who is not breastfeeding should lead to clinical inspection of the skin to search for mechanical factors responsible for mechanical stimulation of the nipple area.

Uncorrected proof

References:

1. Song HS, Jung S-E, Kim YC, Lee E-S. Nipple eczema, an indicative manifestation of atopic dermatitis? A clinical, histological, and immunohistochemical study. *Am J Dermatopathol*. 2015 Apr;37(4):284–288. PMID: 25079201
2. Barankin B, Gross MS. Nipple and areolar eczema in the breastfeeding woman. *J Cutan Med Surg*. 2004 Apr;8(2):126–130. PMID: 15129318
3. Disorders of the nipple and areola. In: Mansel RE, Webster DJT, Sweetland HM. Hughes, Mansel & Webster's benign disorders and diseases of the breast. 3rd ed. Elsevier; 2009: pp. 195–205.
4. Kolodny RC, Jacobs LS, Daughaday WH. Mammary stimulation causes prolactin secretion in non-lactating women. *Nature*. 1972 Aug 4;238(5362):284–286. PMID: 4558564
5. McNeilly AS, Robinson IC, Houston MJ, Howie PW. Release of oxytocin and prolactin in response to suckling. *Br Med J (Clin Res Ed)*. 1983 Jan 22;286(6361):257–259. PMCID: PMC1546473
6. Holt RIG. Medical causes and consequences of hyperprolactinaemia. A context for psychiatrists. *J Psychopharmacol (Oxford)*. 2008 Mar;22(2 Suppl):28–37. PMID: 18477618
7. Tayae M, Jamor J. [A rare case of giant galactocele associated with prolactinoma]. *Pan Afr Med J*. 2017;27:97. PMCID: PMC5554642
8. Poiana C, Chirita C, Carsote M, Hortopan D, Goldstein A. Galactocele and prolactinoma--a pathogenic association? *Maturitas*. 2009 Jan 20;62(1):98–102. PMID: 19110385
9. Chun YS, Taghinia A. Hyperprolactinemia and galactocele formation after augmentation mammoplasty. *Ann Plast Surg*. 2009 Feb;62(2):122–123. PMID: 19158518
10. Tung A, Carr N. Postaugmentation galactocele: a case report and review of literature. *Ann Plast Surg*. 2011;67(6):668-670. PMID: 21346529
11. Guerra M, Codolini L, Cavalieri E, Redi U, Ribuffo D. Galactocele After Aesthetic Breast Augmentation with Silicone Implants: An Uncommon Presentation. *Aesthetic Plast Surg*. 2019;43(2):366-369. PMID: 30456639
12. Sharma SC, Basu NN. Galactorrhea/Galactocele After Breast Augmentation: A Systematic Review. *Ann Plast Surg*. Published online February 19, 2020. PMID: 32079808
13. Taylor D, Kulawansa ST, McCallum DD, Saunders C. Peri-implant galactocele following vacuum-assisted core biopsy of the breast: a cautionary tale. *BMJ Case Rep*. PMID: 23749817
14. de Chadarevian J-P, Arthur LG, Rezvani GA, Duke DS, Davis WJ, Faerber EN. The galactocele of male infants: an intriguing entity. Study and reflection about a case, with review of the literature. *Pediatr Dev Pathol*. 2011;14(2):144-148. PMID: 20718614
15. Perez-Bóscollo AC, Dutra RA, Borges LGS, et al. Galactocele: an unusual cause of breast enlargement in children. *J Pediatr Surg*. 2009;44(7):e1-3. PMID: 19573643

Figure legends:

Uncorrected proof

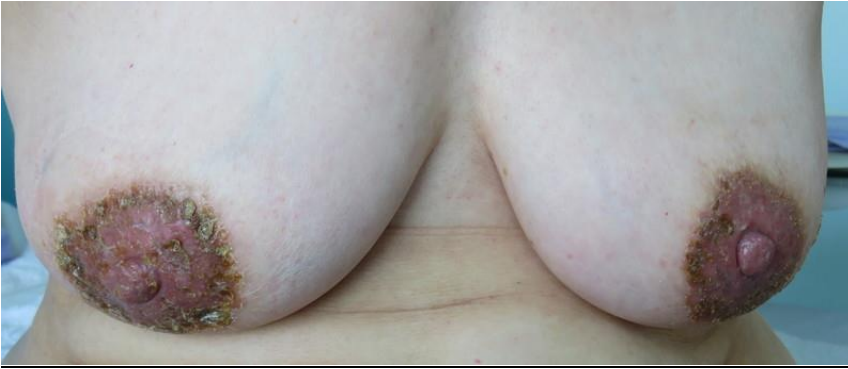

Figure 1 : Severe eczema of both nipples. The clinical manifestations were as follows: crusty yellowing lesions of the nipples, with the discharge of large amounts of a thick milky liquid from fissures and the pores of the lactiferous ducts.

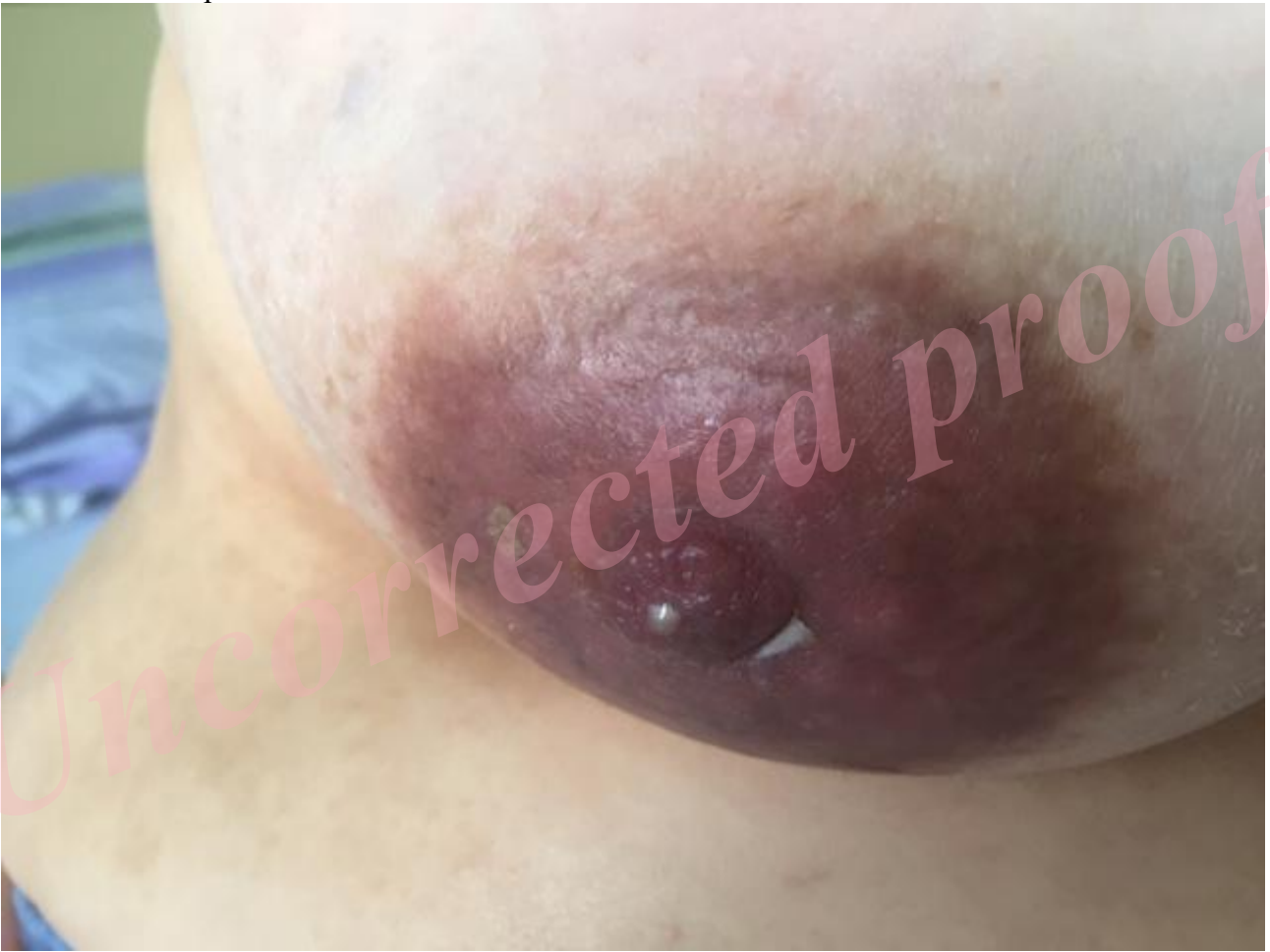

Figure 2 : Galactorrhea of the right breast, after initial local care.

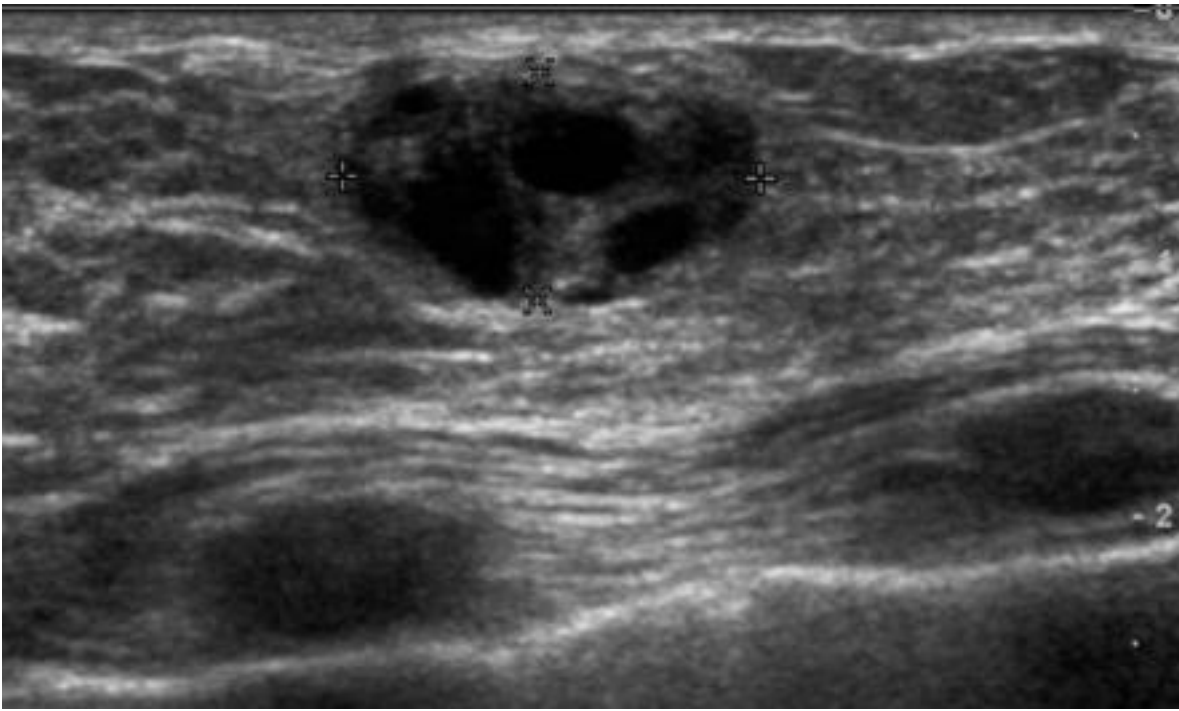


Figure 3 : Ultrasound examination of a galactocele

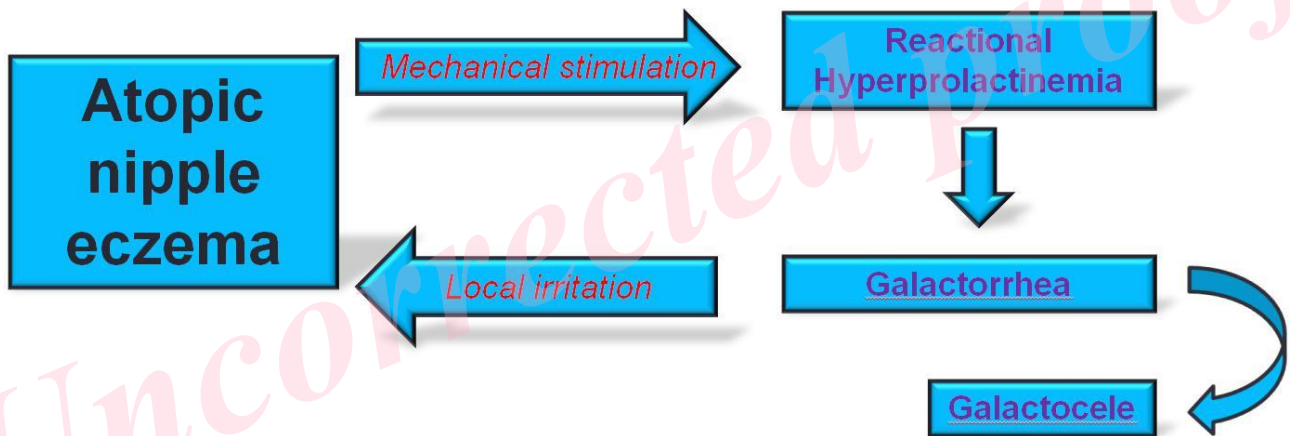


Figure 4 : Graphical abstract

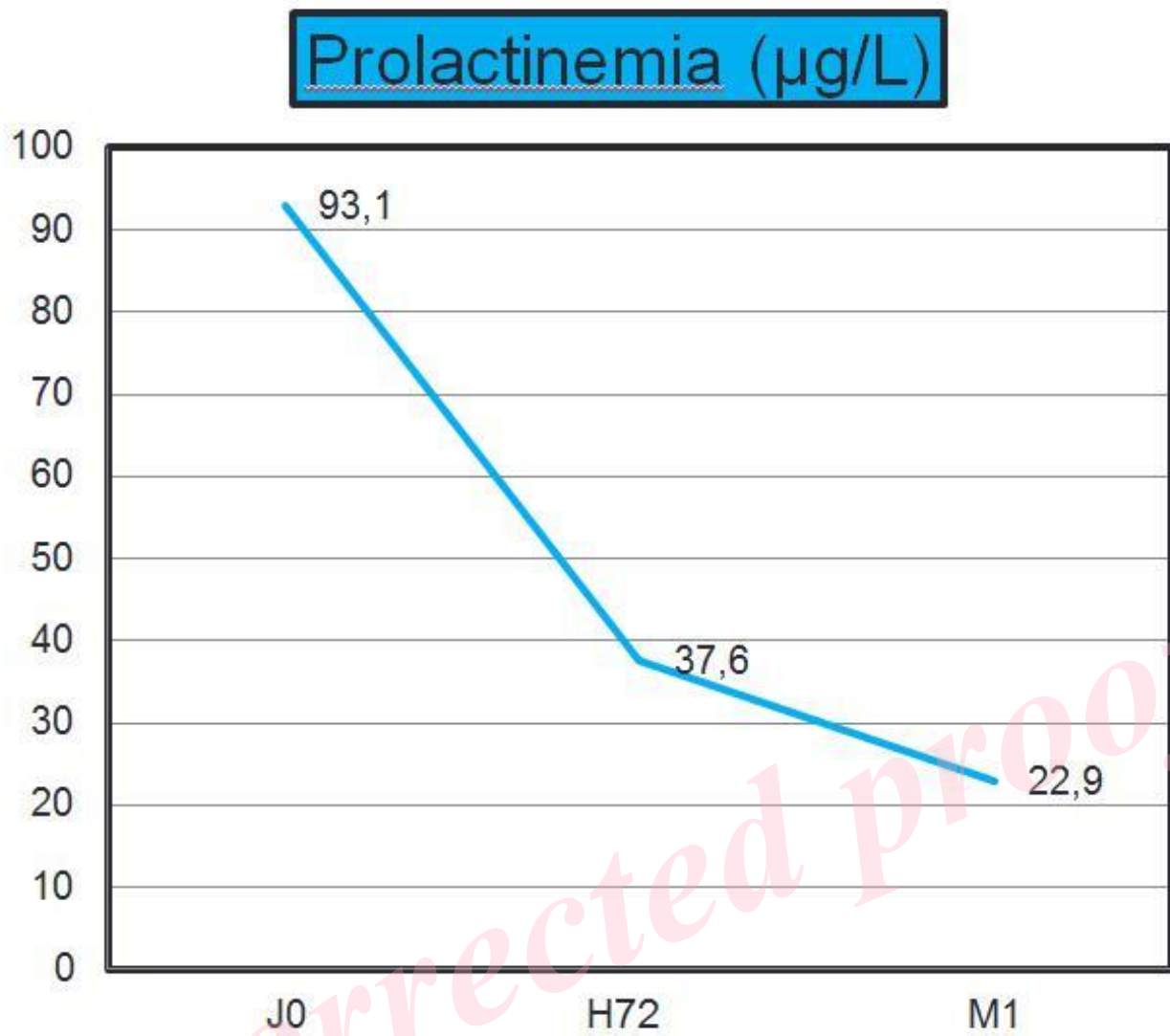


Figure 5 : Decrease in prolactinemia