

Mesenteric Cyst in a Child with Abdominal Pain: A Perspective from Emergency Department Attendance

© Sarah Mohammed Bin Hariz, © Ahmed Hasan AlZaabi, © Ghazy Habeeb Lutf, © Biniam Tesfayohannes, © Ayesha Musabbah Almemari

Sheikh Shakhbout Medical City, Department of Emergency, Abu Dhabi, United Arab Emirates

Abstract

Mesenteric cysts are rare benign intra-abdominal pediatric lesions. It has a variable clinical presentation from an asymptomatic mass to an acute abdomen that appears in the omentum or mesentery of the gastrointestinal tract. Abdominal ultrasound and complete surgical resection are the modality of choice for diagnosis and treatment. Here, we present 15 months old boy who presented to the emergency department with constipation and abdominal pain and was found to have a huge mesenteric cyst that was excised surgically.

Keywords: Mesenteric cyst, abdominal pain, acute abdomen, pediatric, abdominal X-ray

Introduction

Mesenteric cysts are rare and benign intra-abdominal lesions (1). The incidence for mesenteric and omental cysts is approximately 1 in 20,000 admissions for pediatric cases (1). Approximately one-third of cases occur in children younger than 15 years, with a mean age of onset of 4.9 years (2). The clinical presentation is diverse and variable and can occur as a spectrum of asymptomatic abdominal lumps and cramps to an acute abdomen or intestinal obstruction (1-3). Diagnosis is based on clinical and radiological findings with abdominal ultrasound (US) to be the modality of choice in the emergency department (ED) (4). Complete excision of the cystic mass is the best modality therapy (1,5). Because of the rarity of this condition and the lack of specific symptoms, a correct diagnosis is difficult and seldom made. Therefore, it is worth reporting this case.

In this paper, a case of 15 months male child who presented with constipation and abdominal pain and underwent surgical resection for a huge mesenteric cyst is reported.

Case Report

Fifteen months old male child presented to our ED with complaints of generalized abdominal pain and constipation for

10 days duration. Symptoms were associated with decreased oral intake in the last two days before presentation to the ED. There was no history of fever, vomiting, or bleeding per rectum. Prenatal, antenatal and postnatal histories were not significant. There was no significant medical, surgical, or family history.

Vital signs recorded on initial assessment were within normal limits, including a temperature of 36.8 °C. Upon examination, the patient was irritable; the abdomen was distended more in the right upper quadrant, firm to palpation with generalized mild tenderness.

As a part of his assessment in the ED, blood tests were performed, which were all within normal limits. In view of his abdominal pain, constipation and abnormal abdominal examination, an abdominal X-ray was ordered to rule-out bowel obstruction, perforation, or abdominal hernia. The X-ray showed a significant soft tissue shadow in the mid-abdomen displacing the bowel loops to the left side (Figure 1).

Therefore, an abdominal US was performed. As shown in (Figure 2), a large midline cystic lesion measuring 10x7.5 cm was seen displacing the bowel with a suggestion of a mesenteric or duplication cyst. An abdominal magnetic resonance imaging (MRI) was then done which showed a large lobulated right-sided



Corresponding Author: Sarah Mohammed Bin Hariz MD, Sheikh Shakhbout Medical City, Department of Emergency, Abu Dhabi, United Arab Emirates
Phone: +00971557107656 **E-mail:** smhariz@ssmc.ae ORCID ID: orcid.org/0000-0001-8095-5496

Received: 23.12.2021
Accepted: 28.01.2022

Cite this article as: Bin Hariz SM, AlZaabi AH, Habeeb Lutf G, Tesfayohannes B, Musabbah Almemari A. Mesenteric Cyst in a Child with Abdominal Pain: A Perspective from Emergency Department Attendance. Eurasian J Emerg Med. 2022;21(4):281-4.

©Copyright 2022 by the Emergency Medicine Physicians' Association of Turkey
Eurasian Journal of Emergency Medicine published by Galenos Publishing House.

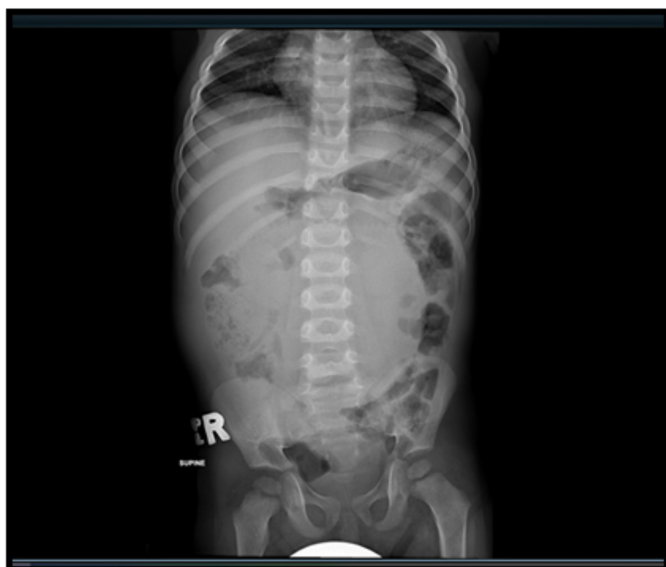

Figure 1. Abdominal X-ray showing large soft tissue shadow in mid abdomen displacing the bowel loops to left side, with no sign of bowel obstruction

and central abdominal cyst, the largest component, had a dumb-bell shape, extended from the superficial central abdomen to the sub-hepatic region and measured 10.5 cm x 14.4 cm x 7 cm. The root of origin of the cyst appeared to be the right iliac fossa, in the ileocaecal region, with the impression of a mesenteric cyst (Figure 3).

The patient underwent surgery, and the cyst was excised entirely. The patient had an uneventful postoperative period. Follow-up was impossible as the patient had traveled out of the country.

Discussion

A mesenteric cyst is defined as any cyst in the mesentery, which can occur in the mesentery along the gastrointestinal tract anywhere from the duodenum to the rectum (6). The reason behind the occurrence of mesenteric cysts is not identified, yet the most accepted theory for the occurrence of the mesenteric cysts was proposed by Gross, stating that mesenteric cysts results

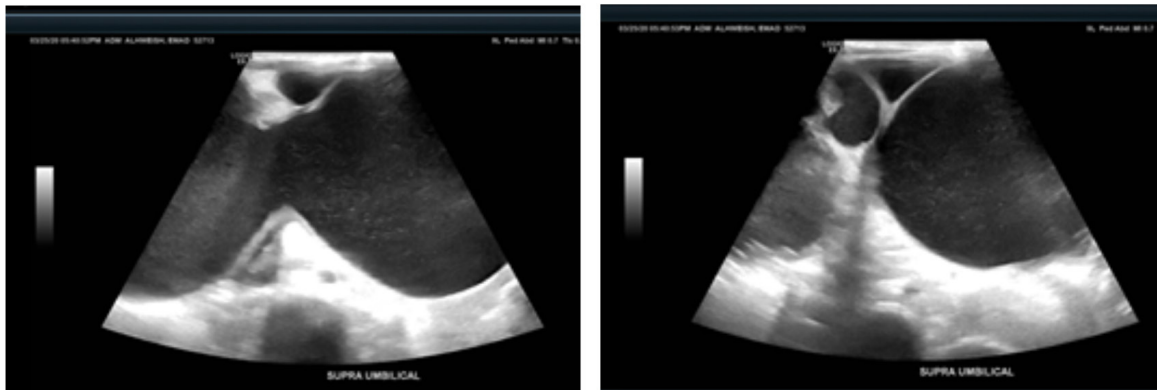


Figure 2. Large midline cystic lesion measuring 10x7.5 cm seen displacing the bowel. No internal septation or solid areas. Fluid contents show internal echoes

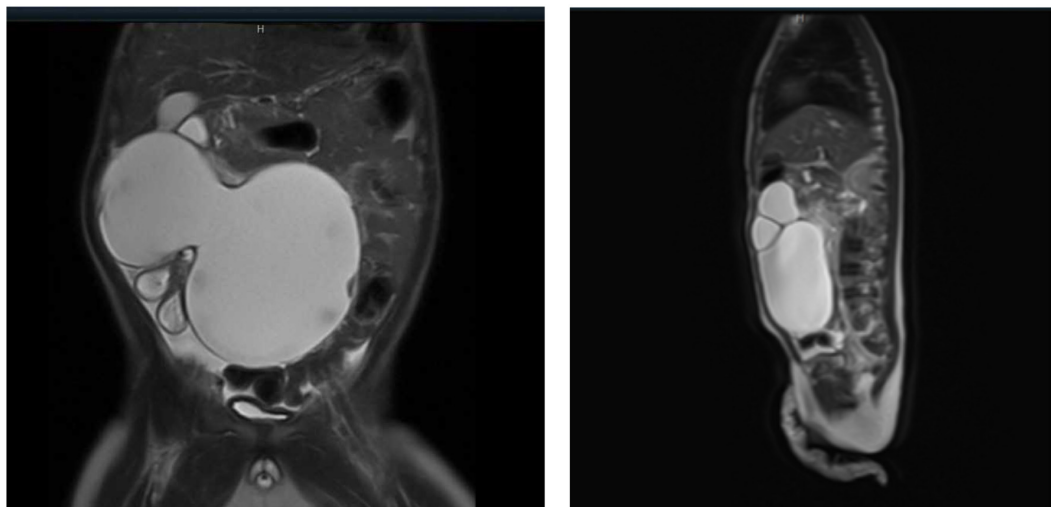


Figure 3. Magnetic resonance imaging showing a large lobulated right-sided and central abdominal cyst, the largest component, had a dumb-bell shape measures 10.5 cm x 14.4 cm x 7 cm

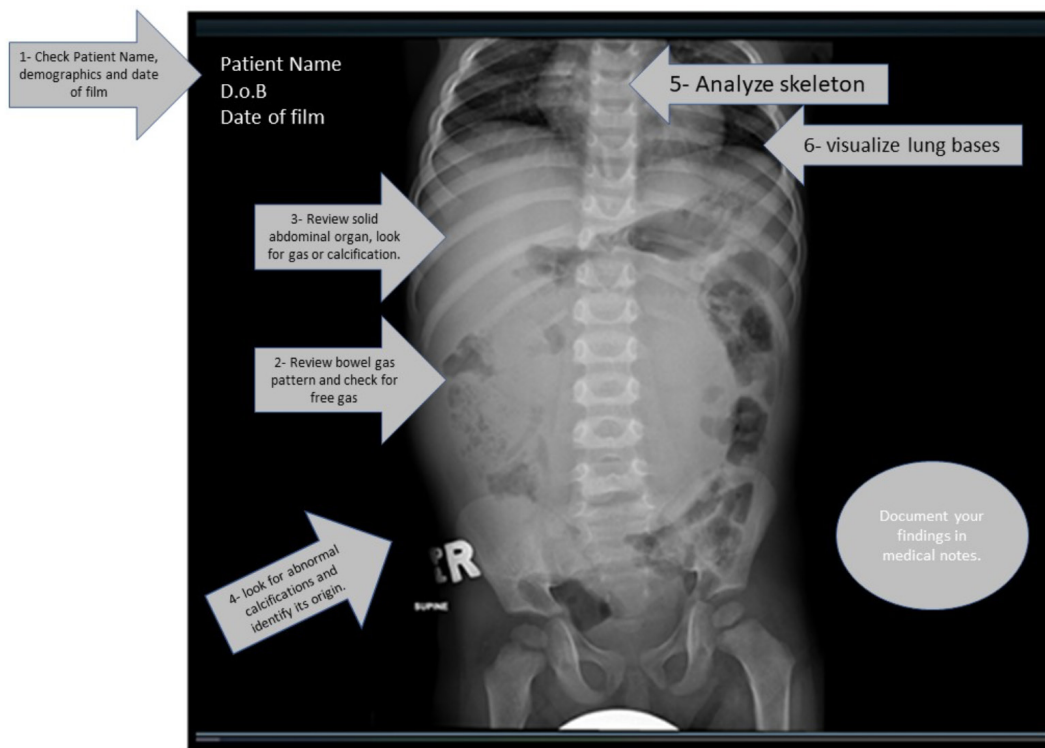


Figure 4. Barry James abdominal-XR interpretation approach [James and Kelly (9)]

from benign proliferation of ectopic lymphatics in the mesentery that lack communication with the remaining of the mesenteric system (1). Mesenteric cysts were first described in 1507 by the pathologist Benivieni during autopsy of an 8 years old child (1,7). Mesenteric cysts may range from a few centimeters to over 10 cm in maximal size length (1). A review of 162 patients mentioned different areas of mesenteric cyst formation with the commonest being in the small-bowel mesentery occurring at a rate of 60% of total described mesenteric cysts, 24% in the large-bowel mesentery, and 14.5% in the retroperitoneum (1).

Patients with mesenteric cyst are usually asymptomatic, but they can also present with vague complaints such as pain from mesenteric cyst, which is the commonest complain (82%), nausea and vomiting (45%), constipation (27%), and diarrhea (6%) while up to 61% of patients had an abdominal mass as a clinical finding (1). Our patient presented with abdominal pain, constipation and reduced oral intake. Such non-specific presenting complaints can be misunderstood as appendicitis, bowel obstruction, or even diverticulitis before surgery.

It is critical to recognize that the red flags of pediatrics' abdominal pain include fever, pain not located in the periumbilical area, nocturnal pain, weight loss, growth disorder, elevated erythrocyte sedimentation rate, and abdominal tenderness. That could increase the likelihood of organic rather than functional pain in

pediatrics. Keep differential diagnosis open initially then narrow based on clinical assessment/diagnostic workup (8).

The diagnostic work of vague abdominal pain and constipation usually includes a plain abdominal X-ray. Abdominal X-ray interpretation is an essential skill for the emergency physician. We usually look for signs of constipation, intestinal obstruction, or a foreign body. It's essential to read X-rays in a structural format not to miss such rare pathology when it occurs. James and Kelly (9) suggested an algorithm for a structured abdominal-XR interpretation as outlined in Figure 4.

For the diagnosis of mesenteric cyst, US of the abdomen is the test of choice and in the hand of an expert can provide details of size, location and septation. Computed tomography scan or MRI can add better anatomical orientation of the cyst even though in general adds little findings to the US (1,3,6,10).

The treatment of choice is complete surgical resection, which can be accomplished through either laparoscopic, laparotomy, or laparoscopic assisted techniques (6). Complications from mesenteric cyst if not removed are rare but if they do occur can range from intestinal obstruction (most frequent), intestinal volvulus, hemorrhage, infection, rupture and torsion (1,5). Additionally, there is a possibility of recurrence or malignant transformation of the cyst.

Conclusion

We report a case and a review of literature of a child with a mesenteric cyst who presented with generalized abdominal pain and constipation. He was surgically treated after being diagnosed with a mesenteric cyst based on radiological examination.

Ethics

Informed Consent: Consent form was filled out by all participants.

Peer-review: Externally peer-reviewed.

Authorship Contributions

Surgical and Medical Practices: G.H.L., B.T., Concept: G.H.L., B.T., Design: S.M.B.H., Analysis or Interpretation: S.M.B.H., A.M.A., Literature Search: S.M.B.H., A.H.A., A.M.A., Writing: S.M.B.H., A.H.A.

Conflict of Interest: No conflict of interest was declared by the authors.

Financial Disclosure: The authors declared that this study received no financial support.

References

1. Yoon JW, Choi DY, Oh YK, Lee SH, Gang DB, Yu ST. A Case of Mesenteric Cyst in a 4-Year-Old Child with Acute Abdominal Pain. *Pediatr Gastroenterol Hepatol Nutr.* 2017;20:268-72.
2. Bliss DP Jr, Coffin CM, Bower RJ, Stockmann PT, Ternberg JL. Mesenteric cysts in children. *Surgery.* 1994;115:571-7.
3. Bezzola T, Bühler L, Chardot C, Morel P. [Surgical therapy of abdominal cystic lymphangioma in adults and children]. *J Chir (Paris).* 2008;145:238-43.
4. Chou YH, Tiu CM, Lui WY, Chang T. Mesenteric and omental cysts: an ultrasonographic and clinical study of 15 patients. *Gastrointest Radiol.* 1991;16:311-4.
5. Nam SH, Kim DY, Kim SC, Kim IK. The surgical experience for retroperitoneal, mesenteric and omental cyst in children. *J Korean Surg Soc.* 2012;83:102-6.
6. Coran AG, Caldamone A, Adzick NS, Krummel TM, Laberge JM, Shamberger R. *Pediatric Surgery E-Book.* Elsevier Health Sciences; 2012.p.1891.
7. Dequanter D, Lefebvre JC, Belva P, Takeddine M, Vaneukem P. Mesenteric cysts. A case treated by laparoscopy and a review of the literature. *Surg Endosc.* 2002;16:1493.
8. Motamed F, Mohsenipour R, Seifirad S, Yusefi A, Farahmand F, Khodadad A, et al. Red Flags of Organic Recurrent Abdominal Pain in Children: Study on 100 Subjects. *Iran J Pediatr.* 2012;22:457-62.
9. James B, Kelly B. The Abdominal Radiograph. *Ulster Med J.* 2013;82:179-87.
10. Luo CC, Huang CS, Chao HC, Chu SM, Hsueh C. Intra-abdominal cystic lymphangiomas in infancy and childhood. *Chang Gung Med J.* 2004;27:509-14.