



A 61-Year-Old Caucasian Woman with Sarcoidosis

Altmış Bir Yaşında Sarkoidozu Olan Beyaz Kadın Hasta

Jason Chertoff, Ali Ataya

University of Florida College of Medicine, Division of Pulmonary, Critical Care and Sleep Medicine, Florida, USA

Cite this article as: Chertoff J, Ataya A. A 61-Year-Old Caucasian Woman with Sarcoidosis. Turk J Anaesthesiol Reanim 2017; 45: 382-3.

A 61-year old female with no medical history presented with complaints of dry cough, dyspnoea, malaise, and a 15-lb weight loss since two months. Her laboratory findings revealed an elevated serum calcium level (14.4 mg dL⁻¹). A chest X-ray showed diffuse small nodules and airspace opacities (Figure 1). Chest computed tomography revealed numerous miliary nodules in a perilymphatic pattern, large nodules in the bilateral lungs, and multiple enlarged mediastinal and hilar nodes (Figure 1). After ruling out tuberculosis, bronchoscopy (Figure 1) and transbronchial biopsy were performed in the anterior segment of the right upper lobe and in the lateral basal segment of the right lower lobe, and the biopsy samples were sent for histopathological examination, which revealed non-necrotizing granulomas (Figure 1). The patient was diagnosed with sarcoidosis and was started on prednisone, methotrexate, and folic acid.

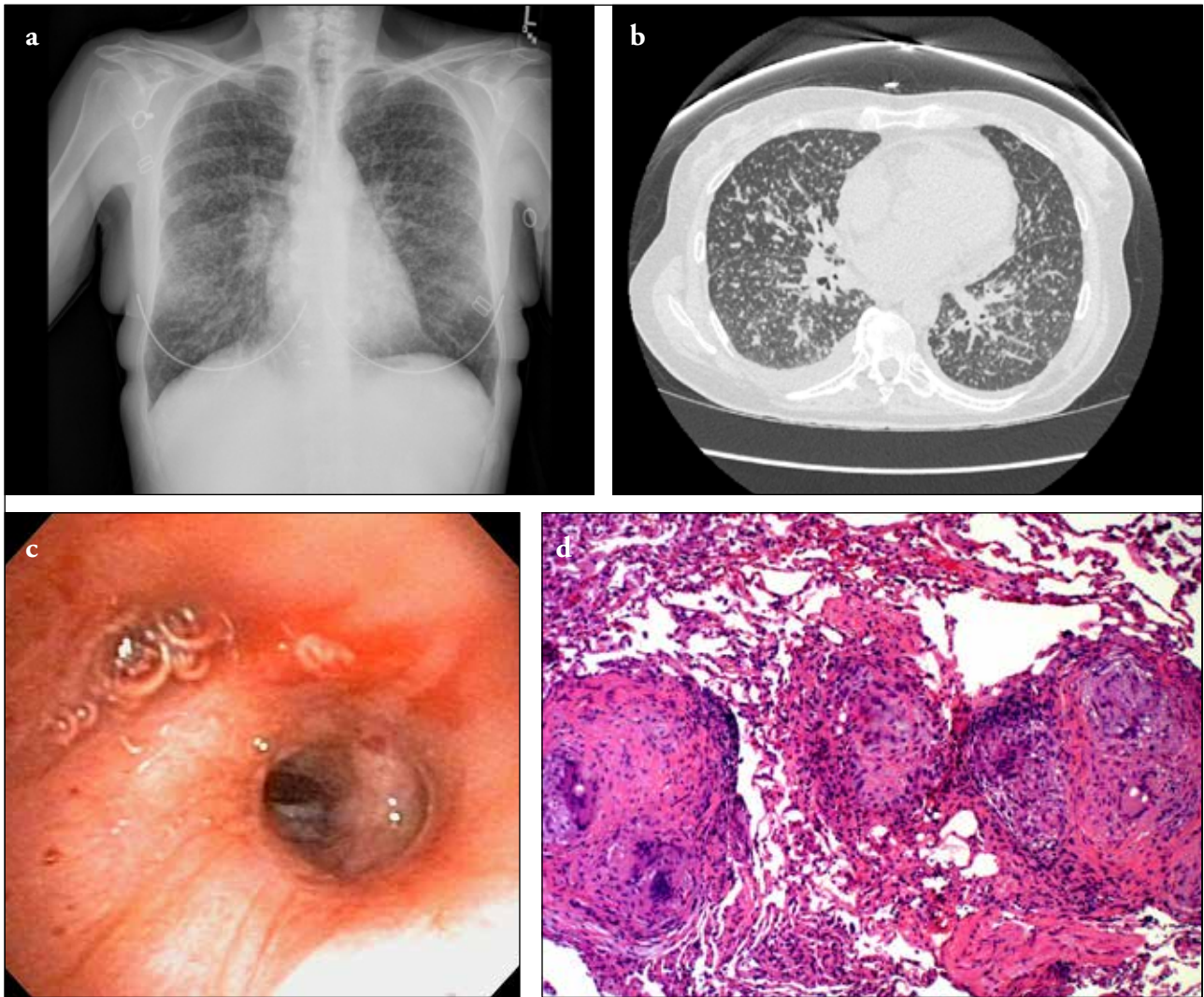


Figure 1. a-d. Chest X-ray showing diffuse nodules and airspace opacities (Panel A). Axial computed tomography showing numerous diffusely spread nodules (Panel B). Bronchoscopy showing non-obstructing raised nodular lesions throughout the tracheobronchial tree (Panel C). Pathological slides showing non-necrotizing granulomas (Panel D)