



Late Recurrence of Sigmoid Carcinoma Mimicking Primary Ureteral Cancer: Case Report and Review of the Literature

Primer Üreter Karsinomunu Taklit Eden Sigmoid Adenokarsinomunun Üretere Geç Dönem Metastazı: Olgu Takdimi ve Literatürün Gözden Geçirilmesi

Tarik Yonguç MD¹ Hakan Postacı MD², Halil İbrahim Bozkurt MD¹, Burak Arslan MD¹, Ömer Koraş MD¹, Tamer Şahin MD², Bülent Günlüsoy MD¹

¹İzmir Bozyaka Training and Research Hospital, Clinic of Urology, İzmir,

²İzmir Bozyaka Training and Research Hospital, Clinic of Pathology, İzmir, Turkey

Summary

Metastatic carcinoma to the ureter is very rare and was described to occur from breast, lung, stomach and prostate cancers. A 48 year old male was admitted with the complaint of gross hematuria. A suspicious mass in the middle part of the left ureter with hydroureteronephrosis was detected on Magnetic Resonance (MR) urography 3 months after the completion of postoperative chemotherapy. Histopathological evaluation of the ureter revealed adenocarcinoma with invasion into the muscularis and pT2. The tumor cells invaded through muscular layer to the lamina propria of the ureter. Biopsies under ureteroscopy are indispensable in the diagnosis of ureteral carcinoma.

Key Words: Adenocarcinoma, immunohistochemistry, metastasis, ureteral cancer

Özet

Üreterin metastatik karsinomu çok nadirdir ve meme, akciğer, mide ve prostat kanserlerinden yayıldığı tanımlanmıştır. Kırk sekiz yaşındaki erkek hasta hematüri şikayeti ile hastanemize başvurdu. Postoperatif kemoterapinin tamamlanmasından 3 ay sonra çekilen Manyetik Rezonans (MR) ürografide sol üreterin orta bölümünde şüpheli kitle ve hidroureteronefroz tespit edildi. Üreterin histopatolojik incelemesinde kasa invaziv adenokarsinom ve pT2 görüldü. Tümör üreterin lamina propriasını ve kas tabakasını invaze etmişti. Üreter karsinom tanısında üretroskopi eşliğinde alınan biyopsiler çok önemlidir.

Anahtar Kelimeler: Adenokarsinom, immünohistokimyasal boyama, metastaz, üreter kanseri

Introduction

Primary adenocarcinoma of the renal pelvis and ureter is an extremely rare tumor, representing less than one per cent of all renal tumors (1). Furthermore, metastatic carcinoma to the ureter is very rare and has been described to occur from breast, lung, stomach and prostate cancers (2). In most published cases the diagnosis was not made until postmortem examination or when gross metastases were present (3). This may be partly due to the asymptomatic nature of the majority of cases (4). Considering both early and late recurrences, distinguishing the metastatic lesion from primary carcinoma is crucial for both management and prognosis. Herein, late recurrence of sigmoid colon cancer presenting with ureteral solid mass is reported and discussed within current literature.

Case Report

A 48 year old male was admitted with the complaint of gross hematuria. He had been operated 1 year ago for sigmoid colon adeno-carcinoma (T4, N2, M0, stage 2, Dukes B) in general surgery department followed by six cycles of adjuvant chemotherapy. The period after the completion of chemotherapy with follow-up colonoscopies and further investigations were uneventful until present day. Physical examination was unremarkable. Abdominal ultrasonography showed left hydroureteronephrosis. Ureteral suspicious mass in the middle part of the left ureter with hydroureteronephrosis was noted on MR urography 3 months after the completion of postoperative chemotherapy (Figure 1). There was no evidence of metastasis. Biopsies under ureteroscopy was performed.

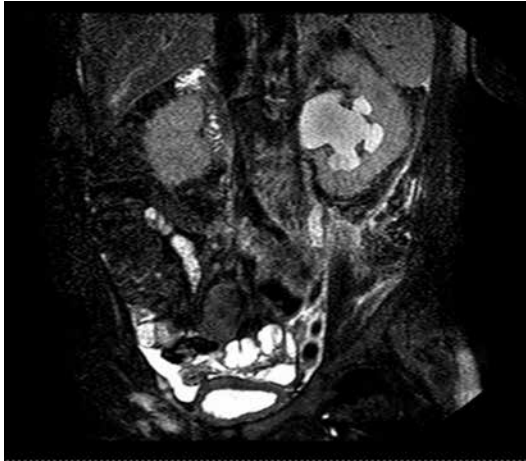

Figure 1. MR urography: Ureteral suspicious mass in the middle part of the left ureter with hydronephrosis

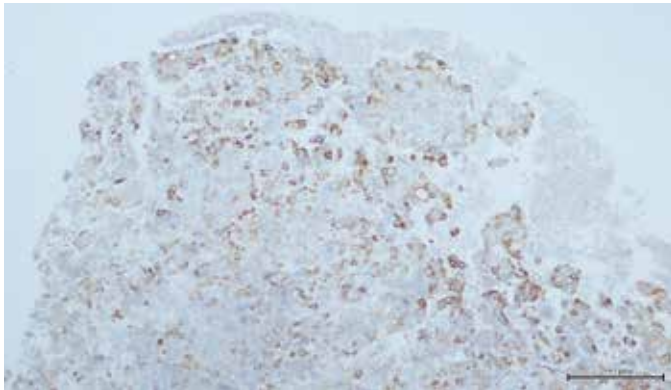


Figure 2. Diffuse and strong cytoplasmic staining pattern of malignant cells with CK-20 (x10)



Figure 3. There was no staining observed with CK-7 in malignant cells (x10)

Histopathology revealed atypical epithelial cells with large vesicular nuclei and with prominent nucleoli. Central necrosis and high mitotic activity was also reported in tumour clusters. CK20 Immunohistochemistry (IHC) examination of tumour cells revealed diffuse and strong cytoplasmic staining pattern

(Figure 2). Contrarily, there was no CK7 staining pattern observed in tumour cells (Figure 3). Also strong nuclear CDX2 immunoreactivity was found (5,6). These features were considered as strongly suggestive for ureteral metastasis of the colonic origin. Left nephroureterectomy was performed. The ureteric histology showed adenocarcinoma with invasion into the muscularis, pT2. The tumor cells invaded through muscular layer to the lamina propria of the ureter. Additional chemotherapy was planned but diffuse metastasis were seen and the patient died because of multiple organ failure in 3 months.

Discussion

Metastatic tumors of the ureter are very rare. The most common primary tumor sites may be kidney, stomach, prostate, breast, lung, and lymph nodes (7). Metastases from carcinoma of the colon are less frequently described and majority of the cases are found incidentally at autopsy (6). Clinical symptoms such as low backpain and renal colic may be due to obstruction of the upper urinary tract, or there may be anuria when there is bilateral involvement. In our case the first symptom was macroscopic hematuria. Hematuria is the most common presenting sign of primary adenocarcinoma of the renal pelvis and ureter, however it is infrequent in metastatic tumors since the mucosa of the urinary tract is rarely involved (8). Three types of metastatic ureteral involvement have been described 1- infiltration of the periureteral adventitial soft tissues with resultant compression of the ureteral wall; 2- transmural or a portion of the layers of the ureter with evidence of tumor cells in the muscular coat, perilymphatic components, or vascular components of the ureter; and 3- involvement of the local mucosa, with or without involvement of the muscularis of the ureter, and submucosal nodules (7). In our case the metastatic ureteral involvement was type 2. The clinical manifestations of the first two types of metastatic ureteral involvement may be stricture formation or even obstruction of the ureter, as occurred in our case. The third type of metastatic ureteral involvement may be manifested by filling defects within the lumen seen radiographically. With regard to the anatomy of the ureter, the periureteral adventitia has longitudinally running well-developed blood vessels, whereas the muscularis and mucosa of the ureter are supplied by fewer smaller perpendicularly arranged vessels. This is a possible reason, why hematogenous metastases more often occur in the periureteral adventitia with resultant compression of the ureter or stricture formation than in the muscularis or mucosal layer (6,7). Thus, the adventitial layer of the ureter is usually first involved and there is subsequent spread into the muscularis and lamina propria by direct extension or along vascular channels. Later, although rarely, attenuation or ulceration of the mucosa may occur.

In our case MR urography revealed significant hydronephrosis over the upper third of the right ureter. However, some ureteral abnormalities such as, inflammatory strictures or primary urothelial neoplasms may present with similar radiographic features. Pathologic confirmation is essential for the diagnosis of primary or metastatic malignancy. Unfortunately, it is difficult to obtain pathologic information in

severely ill patients once they develop diffuse metastatic disease. Biopsies under ureteroscopy provides accurate diagnosis in most of cases just as our patient. In addition, ureteroscopy is a minimal invasive surgery and can be performed in local anesthesia. The diagnostic ureteroscopy has become a fundamental step in the preoperative evaluation of the ureteral tumors. Ureteroscopy allows to explore visually at least 95% of the upper urinary tract and to perform biopsies of the tumor (9).

The prognosis is poor for patients with ureteral metastasis; 75% of the patients die within 6 months after the onset of symptoms of ureteral blockage (10). This may emphasize the importance of early recognition of metastatic ureteral obstruction, especially in those patients without significant clinical symptoms or even after a good response to chemotherapy as occurred in our case. Early appropriate treatment and relief of ureteral obstruction may preserve renal function and increase the survival rate. In conclusion, most cases are diagnosed from the resected specimen postoperatively. The treatment is nephro-ureterectomy. Although it is uncommon, the possibility of metastatic ureteral carcinoma should be considered as a differential diagnosis, especially in patients with a history of adenocarcinoma of the colon. Careful evaluation of patients with a thorough physical examination, appropriate imaging techniques and IHC is crucial for such complex cases. Biopsies under ureteroscopy is indispensable in the diagnosis of ureteral carcinoma.

Conflict of interest: The authors reported no conflict of interest related to this article.

References

1. Spires SE, Banks ER, Cibull ML, et al. Adenocarcinoma of renal pelvis. *Arch Pathol Lab Med* 1993;117:1156-1160.
2. Darrad M, Harper S, Verghese A, et al. Synchronous and metachronous ureteric metastases from adenocarcinoma of the colon. *Int J Clin Oncol* 2012; 17:185-188.
3. Thorup B, Fabrin K, Lund L. Implantation metastasis in ureter from a colonic adenocarcinoma. *Scand J Urol Nephrol* 2001;35:420-421.
4. Cohen WM, Freed SZ, Hasson J. Metastatic cancer to the ureter: a review of the literature and case presentations. *J Urol* 1974;112:188-189.
5. Dabbs DJ. *Diagnostic immunohistochemistry: theranostic and genomic applications* 3rd ed. Saunders, 2010, pp. 222,223,514,902.
6. Jonathan IE, Mahul BA, Victor ER. *Biopsy Interpretation of the Bladder*. 2nd ed. Lippincott Williams & Wilkins, 2010, pp. 71,72
7. Fitch WP, Robinson JR, Radwin HM. Metastatic carcinoma of the ureter. *Arch Surg* 1976;111:874-876.
8. Punia RP, Mundi I, Arora K, et al. Primary adenocarcinoma of ureter mimicking pyelonephritis. *Urol Ann* 2010;2:42-43.
9. Rouprêt M, Wallerand H, Traxer O, et al. Checkup and management of upper urinary tract tumours in 2010: An update from the committee of cancer from the French National Association of Urology. *Prog Urol* 2010;20:260-271.
10. Gotaro K, Shigeo K, Yasutaka K, et al. Ureteral metastasis from appendiceal cancer: report of a case. *Surg Today* 2005;35:168-171.